



A Retrospective Assessment of Zinc Oxide-Eugenol Pulpectomies in Vital Maxillary Primary Incisors Successfully Restored With Composite Resin Crowns

Robert E. Primosch, DDS, MS, MEd¹ Anissa Ahmadi, DMD² Barry Setzer, DDS³ Marcio Guelmann, DDS⁴

Abstract

Purpose: The purpose of this retrospective study was to evaluate, via clinical and radiographic assessments, the treatment outcome of zinc oxide-eugenol (ZOE) pulpectomies performed in vital maxillary primary incisors successfully restored with composite resin crowns.

Methods: Pulpectomized vital primary incisors were treated by a uniformed technique, filled with ZOE paste, and successfully restored with composite resin crowns. Those that remained intact and noncarious for the assessment interval were evaluated for the outcome (success or failure) based on clinical and radiographic findings and compared to: (1) the reason for treatment; (2) the canal filling extent; (3) the type of composite resin crown restoration performed; and (4) the eruption status of its succedaneous tooth.

Results: For 104 maxillary primary incisors meeting the inclusion criteria, failure, as judged by presence of pathologic root resorption and/or apical lucency, was determined to be 24% (25/104), for a mean duration of 18 months observation. Failures were statistically associated with the reason for treatment (higher for trauma), the extent of ZOE paste filler in the pulp canal (higher for gross overfill), and the eruption status of the associated succedaneous permanent incisor (higher for delayed eruption).

Conclusions: This study determined a failure rate (24%) for pulpectomies—using ZOE paste and performed on vital primary incisors—comparable to that reported for nonvital pulpectomies. A statistically significant increase in failure rates was found for: (1) incisors treated for trauma (42%) vs those treated for dental caries (19%); and (2) grossly overfilled canals (80%) vs canals filled to the apex (0%). (*Pediatr Dent* 2005;27:470-477)

KEYWORDS: VITAL PULPECTOMY, ZINC OXIDE-EUGENOL PASTE, PRIMARY INCISORS

Received March 23, 2005 Revision Accepted September 23, 2005

Maintenance of the maxillary primary incisors is imperative for the development of arch form, esthetics, function, normal eruption time of permanent teeth, and mastication.¹⁻³ Thus, pulp therapy is frequently performed in primary incisors to prevent their early loss from dental caries and trauma. Many conditions, however, preclude the use of pulp therapy in primary incisors, including:

1. gross loss of tooth structure;
2. internal or external pathologic root resorption;
3. periapical pathoses;

4. a history of spontaneous or percussion pain;
5. presence of a parulis or sinus tract;
6. suppuration from root canals;
7. hemorrhage that cannot be controlled within 5 minutes of pulpal extirpation.¹⁻³

Because dental caries is a bacterial infection, it has a damaging effect on the pulp, ranging from mild inflammation to necrosis. The severity of the pulpal reaction is related to: (1) the virulence of the bacteria; (2) host response; (3) degree of pulpal reaction; and (4) amount of drainage.⁴ Pulpally involved maxillary primary incisors can be treated with either a pulpotomy or pulpectomy procedure. A pulpotomy procedure (removal of the coronal pulp tissue) excises the inflamed coronal pulp tissue, yielding vital radicular tissue. A pulpectomy procedure (removal of both the coronal and radicular pulp tissue) is indicated in primary teeth that demonstrate chronic inflammation or necrosis beyond the coronal pulp.⁵

¹Dr. Primosch is professor and associate dean, ²Dr. Ahmadi is resident, ³Dr. Setzer is courtesy clinical professor, and ⁴Dr. Guelmann is associate professor and chair, all in the Department of Pediatric Dentistry, University of Florida College of Dentistry, Gainesville, Fla. Correspond with Dr. Primosch at rprimosch@dental.ufl.edu

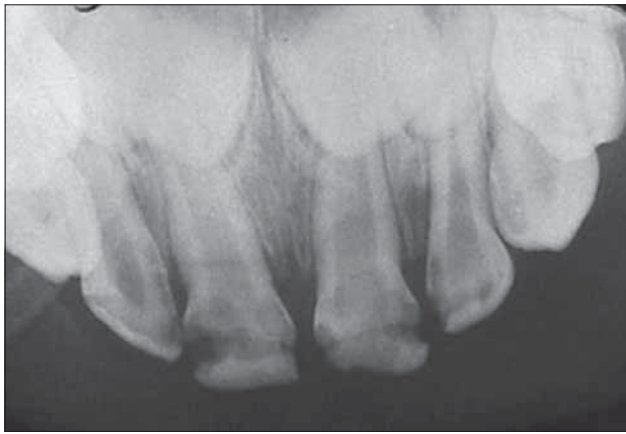

Figure 1. Preoperative radiograph of central incisors with moderate/severe caries in a 2-year, 5-month-old patient.

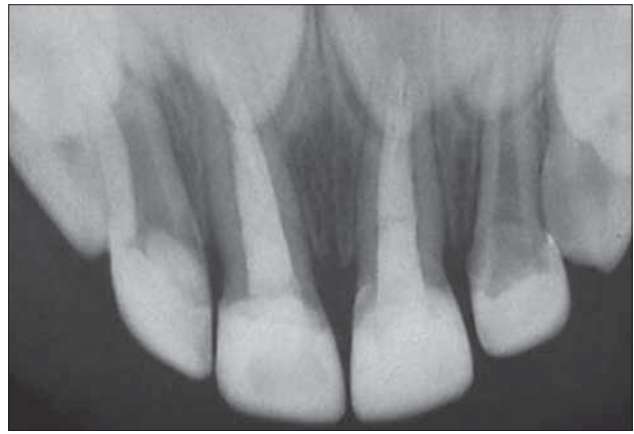


Figure 2. Immediate postoperative radiograph of the same patient's pulpctomized central incisors.

The criteria for the selection of either technique depend on the operator's judgment of the depth of the inflammatory reaction in the pulp tissue—a histological determinant judged by subjective clinical and radiographic findings. The residual pulpal tissue in a pulpctomized incisor provided an opportunity for an acute inflammatory reaction. Additionally, there was no clear anatomical demarcation between the coronal and radicular compartments of primary incisors, compared to primary molars. Consequently, some clinicians preferred pulpctomies instead of pulpctomies for the treatment of vital primary incisors.⁶⁻⁹ The pulpctomy procedure is traditionally reserved for nonvital pulp tissue that is irreversibly infected or necrotic due to caries or trauma.⁵ Despite this fact, there is growing evidence that vital pulp tissue can be successfully treated via pulpctomy when using zinc oxide-eugenol (ZOE) paste⁶⁻⁹ and that this technique is an acceptable alternative to the traditional formocresol pulpctomy procedure. The use of formocresol containing formaldehyde has been implicated in adverse immunological reactions and cited as a potential mutagenic. Therefore, formocresol has been challenged regarding its safety for use in vital pulp exposures of primary teeth.¹

Past clinical studies have shown that a relatively high success rate (>70%) may be accomplished with pulpctomies in both anterior and posterior primary teeth.^{3,6-19} The clinical success rates for pulpctomies in primary teeth may be related more to the pathologic condition of the tooth prior to treatment than to the filling technique per se.¹²

In summary, success rates for pulpctomized primary incisors vary and outcomes are likely influenced by a large array of selection factors and technique variables. The purpose of this retrospective study was to evaluate the clinical and radiographic outcome of ZOE pulpctomies in vital maxillary primary incisors successfully maintained with composite resin crowns.

Methods

This study was approved by the Institutional Review Board at the University of Florida, Gainesville, Fla. Active patient charts from a private practice of a pediatric dentist were reviewed to identify those patients treated with a pulpctomy procedure, subsequent to dental caries or trauma, on a primary maxillary incisor with vital pulp tissue. Progress notes and clinical records pertinent to the specified treated tooth were photocopied and patient identifiers removed. A digital image was taken of each applicable radiograph and coded to the patient chart for evaluation at a later date.

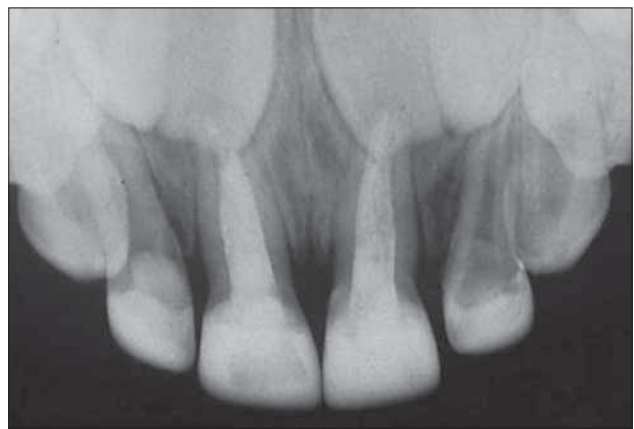


Figure 3. Postoperative radiograph of the same patient at age 4 years, 6 months. Treatment interval was 25 months, and the outcome was rated as a success.

to be included in this retrospective study, the incisor:

1. was determined to be vital by clinical history found in the progress notes (absence of a history of spontaneous or percussion pain, a parulis, or sinus tract);
2. was confirmed as vital by the presence of bleeding and absence of suppuration during extirpation of the pulp and by radiographic examination (absence of pathologic root resorption or apical lucency) at the time of the pulpctomy procedure;
3. was successfully restored with a composite strip crown and remained fully functional and intact without structural defects, recurrent caries/trauma, or loss for the duration of the evaluation interval studied;
4. had diagnostic radiographs available for preoperative, immediate postoperative, and recall appointments of at least a 6-month interval (Figures 1 to 3);
5. had an identifiable outcome (success vs failure) determined by clinical and radiographic findings.

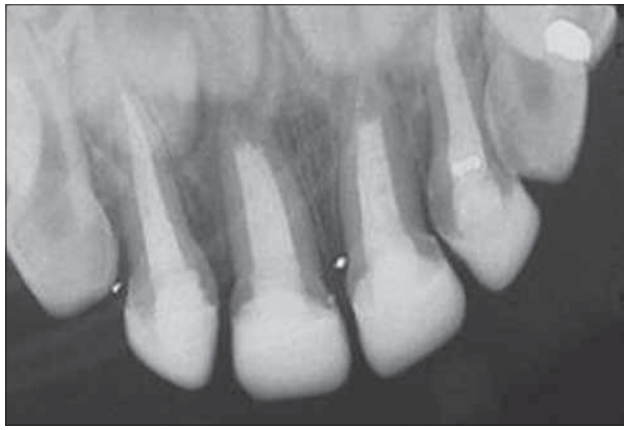


Figure 4. Example of gross underfill. Immediate postoperative radiograph of pulpectomized central incisors illustrating gross underfill of ZOE paste in a 3-year, 4-month-old patient's central incisors.

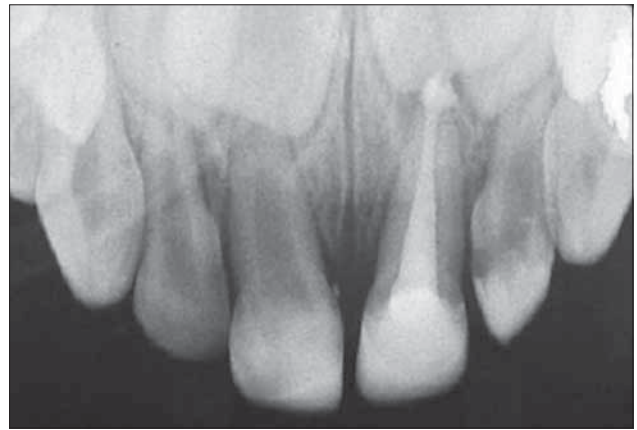

Figure 5. Example of gross overfill. Immediate postoperative radiograph of a pulpectomized central incisor illustrating gross overfill of ZOE paste in a 3-year, 1-month-old patient.

All pulpectomies were completed by a single operator (BS) using a uniformed technique in the following sequence of steps:

1. The tooth was isolated under a floss-ligated medium rubber dam.
2. All carious tooth structure was removed prior to entering the pulp chamber.
3. The pulp tissue was removed with a broach.
4. The root canal was then:
 - a. cleaned, but not instrumented, with rotary or manual endodontic files;
 - b. irrigated with water lavage and air dried;
 - c. treated with a formocresol-soaked paper point for 4 minutes;
 - d. dried with paper points;
 - e. obturated with ZOE paste (zinc oxide USP and eugenol USP) mixed with zinc acetate accelerator crystals (Sultan Chemists, Englewood, NJ) spiraled into the canal with a rotary lentulo spiral.
5. The canal orifice was sealed with TERM Endo Stop (Caulk Dentsply, Milford, Del).
6. Full-coverage restoration was completed by acid etching, a bonding agent, and composite resin (TPH, Dentsply/Caulk, Milford, Del) using a celluloid crown form (Pedo Strip Crowns, 3M/Unitek, St. Paul, Minn). When there was inadequate tooth structure for retention, the operator performed a resin-based core build-up (placed into the coronal portion of the pulp chamber after providing retentive undercuts, as described by Judd et al²⁰). When there was also inadequate crown length, the operator performed a cervical gingivectomy using electrosurgery in addition to the core build-up.
7. An immediate postoperative radiograph was taken.

A calibration training session was performed among the examiners by evaluating the radiographs of 10 randomly selected teeth in the study's coded image bank. This was done to achieve consensus regarding the classifying of ratings for the selected variables. After this training session, a single examiner evaluated the radiographs of the remain-

ing pulpectomies. The chart entries and preoperative radiographs were examined for the following data:

1. incisor type;
 2. age at treatment;
 3. reason for treatment:
 - a. caries;
 - b. trauma.
 4. type of traumatic injury:
 - a. subluxation;
 - b. lateral luxation;
 - c. intrusion;
 - d. extrusion.
 5. type of restoration:
 - a. composite resin crown (CRC);
 - b. resin-based core buildup (RCB) with CRC; or
 - c. electrosurgical gingivectomy for crown lengthening (gingival extension) with RCB and CRC.
- The immediate postoperative radiograph was evaluated for filling extent (gross underfill, slight underfill, fill at apex, slight overfill, or gross overfill; Figures 4 and 5).
- The recall radiograph was evaluated for the following:
1. the outcome (success or failure) based on clinical chart entries and radiographic findings;
 2. the degree of physiologic root resorption present for pulpectomies judged successful:
 - a. none;
 - b. apical one third;
 - c. middle one third;
 - d. coronal one third of root.
 3. the canal filling extent:
 - a. gross underfill;
 - b. slight underfill;
 - c. fill at apex;
 - d. slight overfill;
 - e. gross overfill.
 4. eruption status of the succedaneous tooth:
 - a. normal;
 - b. early;
 - c. delayed.

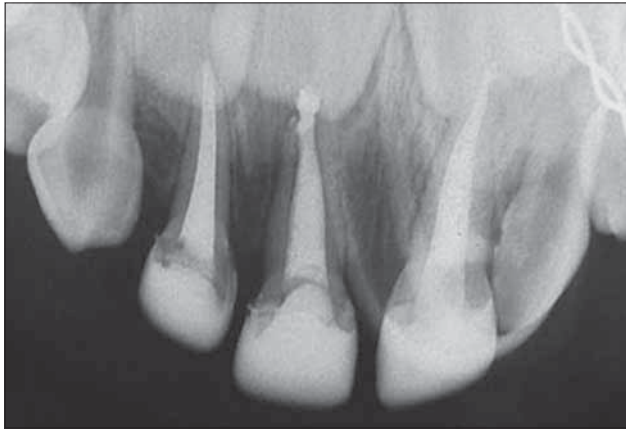

Figure 6. Immediate postoperative radiograph of pulpectomized incisors in a 30-month-old patient. The right central incisor demonstrated overfill of the ZOE paste.

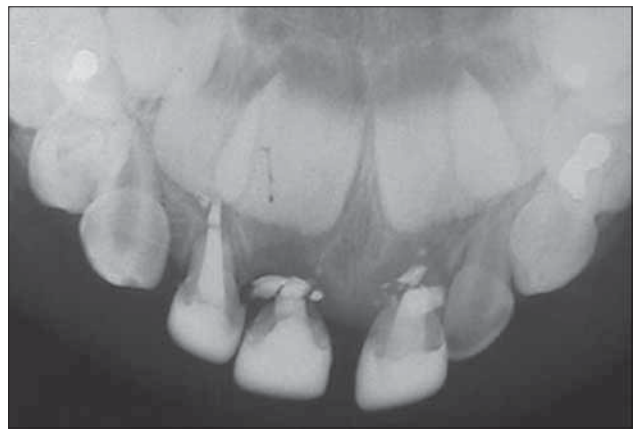


Figure 7. The same patient's radiograph at 10-month follow-up. The outcome was rated as a failure for the central incisors due to pathologic external root resorption.

The eruption status of the succedaneous permanent tooth was assessed by comparing it to the contralateral tooth (if its primary antecedent was untreated) and/or the eruption timing of the other adjacent teeth.

An outcome was labeled a success if the pulpectomized primary incisor exhibited both an asymptomatic history and normal radiographic appearance (Figure 3). An outcome was labeled a failure when the patient presented:

1. clinically with a:
 - a. spontaneous pain;
 - b. percussion sensitivity;
 - c. parulis/fistula associated with the treated incisor.
2. radiographically with an:
 - a. apical lucency;
 - b. internal and/or external inflammatory root resorption (Figures 6 and 7).

All coded data was analyzed on a statistical spreadsheet (StatView, SAS Institute, Inc, Cary, NC). Comparisons were deemed statistically significant at $P < .05$ by chi-square analysis.

Results

Following a review of the 108 available patient charts identified by the American Dental Association's procedure code for primary tooth pulpectomy, 48 charts with 104 pulpectomized primary maxillary incisors were identified as meeting the study inclusion criteria previously stated. The population of incisors analyzed included:

1. 13 right lateral incisors (13%);
2. 32 right central incisors (31%);
3. 44 left central incisors (42%);
4. 15 left lateral incisors (14%).

The reason for the pulpectomy procedure was determined to be:

1. dental caries in 80 (77%) of the incisors;
2. trauma in 24 (23%) of the remaining incisors.

The majority (88%) of the trauma cases were classified as subluxation injuries, with the remaining cases diagnosed as lateral luxation. The mean chronologic age at time of treatment was 33.6 ± 8.6 months, with a range of 16 to 53 months.

The mean chronologic age at the recall radiographic evaluation was 52.1 ± 13.6 months (range=24 to 83 months), for a mean interval of 18.7 ± 10.6 months (range=6 to 48 months). Seventy-nine (76%) of the incisors were determined to be successful (asymptomatic clinical findings and absence of radiographic pathology). Of the pulpectomized incisors judged successfully treated, 75% still had complete root formation and the remaining had various stages of physiologic root resorption. All postoperative pulpectomies judged as failures based on radiographic assessment were identified by pathologic external root resorption and/or apical lucency. No cases of ankylosis were identified in the selected population of pulpectomized incisors. All coronal restorations were considered intact and free of recurrent caries or trauma. The distribution of coronal restoration types was as follows:

1. conventional CRC (84%);
2. RCB with CRC (8%);
3. gingival extension with RCB and CRC (8%).

Analysis of failures

Distribution of the 25/104 failures (24%) by tooth type were 3/28 (11%) for lateral incisors and 22/76 (29%) for central incisors. The failure rate of pulpectomies in successfully restored maxillary primary incisors was not statistically related to tooth type ($P = .09$), although there was a trend for increasing failure rate with central incisors compared to lateral incisors. The type of coronal restoration performed was statistically significant in analyzing pulpectomy failures ($P = .04$). CRC restorations accounted for all the failures. Their failure rate of 28% (25/88) was statistically different from the total absence of failures (0/16) in the more complex RCB restorations.

The causative factor (caries or trauma) associated with the decision to perform a pulpectomy procedure in the maxillary primary incisors was found to be a statistically significant influence on failure rate by chi-square analysis ($P = .02$). Radiographic failure occurred in 19% (15/80) of the incisors treated for dental caries. A 42% failure rate (10/24), however, was demonstrated where pulpectomies were

performed to treat dental trauma, predominately subluxation injuries in the population studied. There was no statistically significant difference ($P=.11$) in failures between subluxation and lateral luxation injuries.

The extent of the ZOE filling in the radicular portion of the pulp canal was compared to the failure rate of the pulpectomy procedure. The filling extent judged on the immediate postoperative radiograph was determined to be statistically significant at $P<.001$ to the failure rate identified at the follow-up evaluation. Initial gross overfill exhibited the highest rate of failure at 80% (4/5). This failure rate was significantly higher than that identified for the other filling extents: (1) slight overfill (2/10; 20%); (2) at apex (0/13; 0%); (3) slight underfill (6/27; 22%); and (4) gross underfill (13/49; 27%).

Delayed eruption of the overlying succedaneous permanent incisor was statistically associated with cases of pulpectomy failure. Of the 11 cases of delayed eruption observed, 9 (82%) of the associated primary incisors were concurrent pulpectomy failures. There were 16 failures (17%), however, in the group of 93 primary incisors whose succedaneous permanent incisors had normal eruption status. This difference was statistically significant at $P<.0001$ using chi-square analysis.

Chronologic age at time of treatment was not associated with failures ($P=.08$), although cases of failure tended to occur in slightly older children (mean=36.2±9.3 months old), as compared to children exhibiting successful treatment (mean=32.8±8.2 months old). Pulpectomy failure in the study population was also not associated with interval of evaluation. There was no statistically significant difference ($P=.57$) in the mean duration of treatment evaluated between failures (19.8±9.1 months) and successful treatments (18.4±11.1 months).

Discussion

The goal of pulp therapy in primary teeth is to preserve function and esthetics that would otherwise be lost to extraction. Premature extraction of primary incisors may create immediate management problems, as well as potential orthodontic, masticatory, and psychological problems. Prior pulpectomy studies using ZOE paste on primary teeth revealed failure rates ranging from 11% to 35%,^{3,6-9,12,13,17,18} compared to the present study's 24% failure rate.

This failure rate was very consistent with findings for nonvital incisors of 20% by Reddy et al¹⁴ and 22% by Coll et al²¹ and not significantly different from the nonvital primary molar failure rate of 25% reported by Coll et al.²² This failure rate is also comparable to that reported for vital incisor pulpectomies using ZOE paste (18% to 24%).⁶⁻⁹ The methodology of the present study potentially created a bias toward success, as the selection criteria eliminated failures not documented by radiographic assessment. This occurrence is unlikely, however, as the operator followed treatment guidelines dictating obtainment of radiographic documentation prior to any extraction procedure.

Gross overfill of ZOE beyond the confines of the root canal was statistically associated with failure in the present study. Although a review of the literature supported this finding, one must be cautious with this interpretation due to the small number of overfills (5) identified in the sample. The extent of fill in a study by Coll et al²² also negatively influenced success rates. These authors reported a 22% failure rate in 65 primary incisor and molar ZOE pulpectomies over a 52-month period. Specifically, pulpectomies underfilled or to the apex had a significantly greater success than overfills.

According to Sadrian et al,²³ a significantly higher rate of ZOE retention (failure to resorb) was noted in those pulpectomies with overfills (65%) and those filled to the apex (53%) as compared to those filled 1 mm or more short of the apex (35%). Holan et al¹² reported that 100% of the teeth filled to the apex with KRI paste and 89% of those filled with ZOE were successful and not statistically different. Likewise, no difference was observed when the teeth were underfilled with ZOE or KRI paste. Overfilling the canals, however, resulted in a much higher success rate of KRI (79%) than ZOE (41%), which was a statistically significant difference.

In the present study, the outcome was significantly affected by the reason for treatment (caries vs trauma). Incisors treated secondary to dental trauma failed in 42% of the cases reviewed, compared to 19% for incisors treated for dental caries. The results of a previous study by Coll et al,²¹ however, indicated no significant difference in success rates of pulpectomies in teeth suffering preoperative trauma and those without a history of preoperative trauma. Furthermore, their reported pulpectomy success rates were not significantly affected by tooth type (central vs lateral incisor), length of time posttreatment, or the age of the patient at the time of treatment. These findings are consistent with the present study. To the contrary, a recent report by Payne et al⁸ suggested that central incisors had a less favorable success rate than lateral incisors.

An ideal root canal filling material for primary teeth should:

1. exhibit resorption at the same rate as the primary root structure;
2. demonstrate rapid resorption of any excess material extruded beyond the root apices;
3. be antiseptic;
4. fill the root canals easily;
5. adhere to the canal walls;
6. not shrink;
7. be easily removed, if needed;
8. be radiopaque;
9. not discolor the tooth;
10. be nontoxic.^{2,13,24,25}

Currently, no material meets all these criteria.² ZOE is presently the most commonly used root canal filling material for the pulpectomy procedure in primary teeth.²⁶ Other root canal filling materials for primary teeth include

calcium hydroxide, iodoform paste, or a combination of both.^{2,12,16,27-30}

Although ZOE has exhibited high success rates, some studies have reported that it sets into a hard cement that resists resorption when extruded beyond the apices.^{6,10,21,25,27} An investigation by Mani et al¹³ revealed that 67% of all overfilled canals showed over-retained ZOE at 6 months follow-up. Other long-term follow-up evaluations of pulpectomized primary teeth with ZOE revealed a high chance of retention of the overfilled material in the periapical region, even after physiologic resorption of the roots.^{6,22,23,27} This unresorbed ZOE can deflect the succedaneous tooth's path of eruption. In a study by Flaitz et al,⁶ deflections of the permanent tooth eruption were observed in 20% of the pulpectomized teeth that were extracted.

Furthermore, some studies indicated that ZOE itself and/or the fixative often added to it may irritate the periapical tissues and cause a foreign body reaction. Erausquin and Muruzabal found that ZOE irritates the periapical tissues of rats and may produce necrosis of bone and cementum.³¹ Jerrell and Ronk presented a case report of an overfilled ZOE pulpectomy in which development of the succedaneous premolar was arrested.³² They attributed this malformation to the toxic nature of the filling material. Sadrian et al,²³ however, reported that no pathology was associated with the retained ZOE for the 49% of the teeth that retained ZOE filler particles, nor was retention of ZOE related to pulpectomy success or failure. According to Reddy et al,¹⁴ the lack of ZOE's antibacterial properties may aggravate residual infection of the root canal instead of promoting healing of infected tissue. Specifically, ZOE has been shown to exhibit medium to weak inhibition against pure cultures of oral bacteria which frequently have been found to predominate in infected pulpal tissue.^{33,34}

The results of Coll et al²¹ showed that the timing of exfoliation of primary incisors did not seem to be a problem. Only 13% of the pulpectomies exfoliated early, while another 13% had delayed exfoliation. In another study by Coll et al,²² they reported that the pulpectomized teeth rarely exfoliated later than normal and the timing of the exfoliation was not related to retention of ZOE paste.

The most widely accepted restorative option for the treatment of primary incisors was the bonded composite resin crown using a celluloid strip crown (CRC).^{35,36} Parental satisfaction reported with this treatment option was high.³⁷ Its excellent esthetics and the ease of repair, if the crown should later chip or fracture, made it the primary choice of many clinicians. It was also the most technique sensitive, however, and its durability over extended periods of time may be of minor concern.^{35,38,39} Furthermore, adequate bonding area, moisture control, and absence of hemorrhage are required for clinical success.³⁵ In cases of severe tooth destruction, it is necessary to perform intracoronal retention, which allowed for building a core (RCB), and then placement of an appropriate full-coverage restoration.^{21,40,41} The type of coronal restoration

performed in the present study was statistically significant when analyzing pulpectomy failures.

Although all restorations were considered intact and free of recurrent caries or trauma (crown fracture) in the present study, conventional CRC (86% of the sample) accounted for all the pulpectomy failures. Their failure rate of 28% was statistically different from the complete absence of failures in the more complex restorations using an RCB. Despite only accounting for 16% of all the restorations performed, complex restorations were only preformed on cariously involved incisors. To the contrary, all traumatized incisors received CRC only. Since traumatized incisors had a higher failure rate, any comparison of the type of restoration could be biased by this association. The failures may be more attributed to the reason for treatment than to the restorative technique used. Nevertheless, it was also possible to speculate that failures were attributed to microleakage around the crown margins and that RCB restorations resisted marginal leakage better than CRC alone. There were no clinical studies identified in the literature that compared pulpectomy success to the type of crown restoration placed on the incisor.

Conclusions

In 104 successfully restored, vital maxillary primary incisors treated by a zinc oxide-eugenol paste pulpectomy procedure and observed for a mean duration of 18 months, clinical and radiographic failure was determined to be 24% (25/104) and statistically associated with:

1. Reason for treatment: incisors treated secondary to dental trauma failed in 42% of the cases reviewed, compared to 19% for incisors treated for dental caries ($P=.02$).
2. Type of restoration: Incisors restored with a conventional composite crown failed at a statistically higher rate than more complex restorative techniques using a chamber-retained composite core ($P=.04$).
3. Extent of zinc oxide-eugenol paste filler in pulp canal: Gross overfill of paste beyond the confines of the root canal was statistically associated with failure. ($P<.001$).
4. Eruption status of the associated succedaneous permanent incisor: Delayed eruption occurred more frequently with failed pulpectomies. ($P<.0001$)

In summary, the prognosis for pulpectomized vital primary incisors using zinc oxide-eugenol paste was significantly reduced when treated as a result of trauma or when overfill of the zinc oxide-eugenol paste occurred beyond the root apex.

References

1. Goerig SC, Camp JH. Root canal treatment in primary teeth: A review. *Pediatr Dent* 1983;5:33-37.
2. Fuks AB. Pulp therapy for the primary and young permanent dentitions. *Dent Clin North Am* 2000;44: 571-596.

3. Barr ES, Flaitz CM, Hicks MJ. A retrospective radiographic evaluation of primary molar pulpectomies. *Pediatr Dent* 1991;13:4-9.
4. Walton RE, Torabinejad M. *Principles and Practices of Endodontics*. 2nd ed. Philadelphia: WB Saunders Company; 1996:279.
5. AAPD. Guideline on pulp therapy for primary and young permanent teeth. *Pediatr Dent* 2004;26(special issue):115-119.
6. Flaitz CM, Barr ES, Hicks MJ. Radiographic evaluation of pulpal therapy for primary anterior teeth. *J Dent Child* 1989;56:182-185.
7. Yacobi R, Kenny DJ, Judd PL, et al. Evolving primary pulp therapy techniques. *J Am Dent Assoc* 1991;122:83-85.
8. Payne RG, Kenny DJ, Johnston DH, Judd PL. Two-year outcome study of zinc oxide-eugenol root canal treatment for vital primary teeth. *J Can Dent Assoc* 1993;59:528-536.
9. Casas MJ, Kenny DJ, Johnston DH, Judd PL, Layug MA. Outcomes of vital primary incisor ferric sulfate pulpotomy and root canal therapy. *J Can Dent Assoc* 2004;70:34-38.
10. Fuks AB, Eidelman E. Pulp therapy in the primary dentition. *Curr Opin Dent* 1991;1:556-563.
11. Tagger E, Sarnat H. Root canal therapy of infected primary teeth. *Acta Odontol Pediatr* 1984;5:63-66.
12. Holan G, Fuks AB. A comparison of pulpectomies using ZOE and KRI paste in primary molars: A retrospective study. *Pediatr Dent* 1993;15:403-407.
13. Mani SA, Chawla HS, Tewari A, Goyal A. Evaluation of calcium hydroxide and zinc oxide-eugenol as root canal filling materials in primary teeth. *J Dent Child* 2000;67:142-147.
14. Reddy VVS, Fernandes BDS, Davangere. Clinical and radiological evaluation of zinc oxide-eugenol and Maisto's paste as obturating materials in infected primary teeth—nine months study. *J Indian Soc Pedod Prev Dent* 1996;14:39-44.
15. Reyes AD, Reina ES. Root canal treatment in necrotic primary molars. *J Pedod* 1989;14:36-39.
16. Garcia-Godoy F. Evaluation of an iodoform paste in root canal therapy for infected primary teeth. *J Dent Child* 1987;54:30-34.
17. Gould JM. Root canal therapy for infected primary molar teeth—preliminary report. *J Dent Child* 1972;39:269-273.
18. Coll JA, Josell L, Casper JS. Evaluation of a one-appointment formocresol pulpectomy technique for primary molars. *Pediatr Dent* 1985;7:123-129.
19. Rifkin A. A simple, effective, safe technique for the root canal treatment of abscessed primary teeth. *J Dent Child* 1980;47:435-441.
20. Judd PL, Kenny DJ, Johnston DH, Yacobi R. Composite short-post technique for primary anterior teeth. *J Am Dent Assoc* 1990;120:553-555.
21. Coll JA, Josell S, Nassof S, Shelton P, Richards MA. An evaluation of pulpal therapy in primary incisors. *Pediatr Dent* 1988;10:178-184.
22. Coll JA, Sadrian R. Predicting pulpectomy success and its relationship to exfoliation and succedaneous dentition. *Pediatr Dent* 1996;18:57-63.
23. Sadrian R, Coll JA. A long-term follow-up on the retention rate of zinc oxide eugenol filler after primary tooth pulpectomy. *Pediatr Dent* 1993;15:249-253.
24. Spedding RH. Incomplete resorption of resorbable zinc oxide root canal fillings in primary teeth: Report of two cases. *J Dent Child* 1985;52:214-216.
25. Nurko C, Ranly DM, Garcia-Godoy F, Lakshmyya KN. Resorption of a calcium hydroxide/iodoform paste (Vitapex) in root canal therapy for primary teeth: A case report. *Pediatr Dent* 2000;22:517-520.
26. Primosch RE, Glomb TA, Jerrell RG. Primary tooth pulp therapy as taught in predoctoral pediatric dental programs in the United States. *Pediatr Dent* 1997;19:118-122.
27. Ranly DM, Garcia-Godoy F. Reviewing pulp treatment for primary teeth. *J Am Dent Assoc* 1991;122:83-85.
28. Chawla HS, Mani SA, Tewari A, Goyal A. Calcium hydroxide as a root canal filling in primary teeth—a pilot study. *J Indian Soc Pedod Prev Dent* 1998;16:90-92.
29. Chawla HS, Mathur VP, Gauba K, Goyal A, Chandigarh. A mixture of Ca(OH)₂ paste and ZnO powder as a root canal filling material for primary teeth: A preliminary study. *J Indian Soc Pedod Prev Dent* 2001;19:107-109.
30. Nedley, MP. The pulpectomy in primary teeth. *J Mich Dent Assoc* 2002;84:38-42.
31. Erasquin J, Muruzabal M. Root canal fillings with zinc oxide eugenol cement in the rat molar. *Oral Surg* 1967;24:547-558.
32. Jerrell RG, Ronk SL. Developmental arrest of a succedaneous tooth following pulpectomy in a primary tooth. *J Pedod* 1982;6:337-342.
33. Tchaou W, Turng B, Minah GE, Coll JA. In vitro inhibition of bacteria from root canals of primary teeth by various dental materials. *Pediatr Dent* 1995;17:351-355.
34. Tchaou W, Turng B, Minah GE, Coll JA. Inhibition of pure cultures of oral bacteria by root canal filling materials. *Pediatr Dent* 1996;18:444-449.
35. Waggoner WF. Restoring primary anterior teeth. *Pediatr Dent* 2002;24:511-516.
36. Waggoner WF. Restorative dentistry for the primary dentition. In: Pinkham JR, ed. *Pediatric Dentistry: Infancy through Adolescence*. 2nd ed. Philadelphia: WB Saunders Co; 1994:298-325.
37. Kupietzky A, Waggoner WF. Parental satisfaction with bonded composite strip crowns for primary incisors. *Pediatr Dent* 2004;26:337-340.

38. Kupietzky A, Waggoner WF, Galea J. The clinical and radiographic success of bonded resin composite strip crowns for primary incisors. *Pediatr Dent* 2003;25: 577-581.
39. Tate AR, Ng MW, Needleham HL, Acs G. Failure rates of restorative procedures following dental rehabilitation under general anesthesia. *Pediatr Dent* 2002;24:69-71.
40. Pithan S, Vieira RS, Chain MC. Tensile bond strength of intracanal posts in primary anterior teeth: An in vitro study. *J Clin Pediatr Dent* 2002;27:35-39.
41. Ramires-Romito ACD, Wanderley MT, Oliveira MDM, Imparato JCP. Biologic restoration of primary anterior teeth. *Quintessence Int* 2000;31:405-411.

ABSTRACT OF THE SCIENTIFIC LITERATURE



INFLUENCE OF THE TYPE OF PULP VITALITY TRAUMA AND THE TIME ELAPSED UNTIL TREATMENT

The purpose of this study was to determine the influence of the type of pulp vitality trauma in children aged 0 to 3 years and the time elapsed until dental care was sought. A total of 1,813 records were analyzed. Two hundred three patients, corresponding to 302 traumatized teeth, were assessed clinically and radiographically. Hard-tissue injuries were the most frequent (52%), with a predominance of enamel crown fractures (41%), followed by concussions (13%) and intrusions (12%). Clinical and radiographic examination revealed that 72% of the traumatized teeth maintained pulp vitality. In the case of supporting-tissue lesions, 51% of the patients sought care within 1 to 15 days after injury, while in the case of hard-tissue injuries, 53% sought care only after 16 days. The results showed that enamel crown fractures were associated with a large number of teeth, which maintained pulp vitality. The results further showed that intrusion and subluxation were responsible for a large number of cases of pulp necrosis. Supporting-tissue injuries had a significant influence on seeking dental care faster.

Comments: These findings indicate that injuries affecting the primary dentition should be monitored clinically and radiographically to detect probable alterations in the traumatized tooth and supporting structures. A high percentage of patients did not seek immediate treatment, which emphasizes the importance of educational and preventative programs to parents as early as possible. Establishment of awareness programs is needed to stimulate parents to adopt more adequate measures in case of dental injuries. FSS

Address correspondence to Robson Frederico Cunha, Department of Pediatric Dentistry, School of Dentistry, Paulista State University-UNESP, Run Jose Bonifacio n 1139, CEF 16015-050, Aaracatuba, SP, Brazil.

Pugliesi DM, Cunha RF, Delbem AC, Sundefeld ML. Influence of the type of dental trauma on the pulp vitality and the time elapsed until treatment: A study in patients aged 0-3 years. *Dent Traumatol* 2004;20:139-142.

28 references