

## Treatment of juvenile periodontitis with microbiologically modulated periodontal therapy (Keyes Technique)

Thomas E. Rams, DDS, MHS Paul H. Keyes, DDS, MS  
William E. Wright, DDS, MS

### Abstract

*Antimicrobial therapeutic strategies widely referred to as the Keyes Technique were directed at suppression of the periodontopathic microflora of 7 juvenile periodontitis patients who were treated and followed for at least 22 months.*

*Following collection of baseline clinical and microbiological parameters, the patients received meticulous scaling and root planing of all teeth with concomitant irrigation to probing depth of saturated inorganic salt solutions and 1% chloramine-T. The patients were recalled at approximately 2- to 3-month intervals for maintenance care which was modulated by clinical parameters and phase-contrast microscopic findings. Six patients received at least 2 courses of systemic tetracycline (1 gm/day for 14 days) during the study. Patient home treatments included daily application of a sodium bicarbonate/3% hydrogen peroxide paste, and inorganic salt irrigations.*

*Clinical reevaluations made an average of 29.6 months posttreatment showed statistically significant ( $p < .01$ ) decreases in bleeding on probing in all patients. Significant decreases in probing depth, and gains in clinical attachment levels also were found in all patients, particularly in advanced sites initially 4-6 mm and  $\geq 7$  mm in probing depth. Among sites with initial attachment loss  $\geq 5$  mm, 25.8% experienced a  $\geq 3$  mm gain in clinical attachment level from baseline with therapy. Significant decreases in motile organisms and crevicular polymorphonuclear leukocytes present in the subgingival plaque of the patients also occurred with the antimicrobial therapy employed.*

*These findings demonstrate that juvenile periodontitis patients can be treated successfully and maintained on a long-term basis without periodontal surgery when appropriate antimicrobial therapy is directed at the subgingival periodontopathic microbiota.*

A wide variety of therapeutic approaches have been used to manage juvenile periodontitis (JP) patients, even though the exact nature of its etiology has been understood poorly until recently. Almost all of these approaches have employed clinical periodontal parameters alone to guide therapy diagnostically, and determine its success or failure.<sup>1-6</sup> Most also have placed emphasis in treatment on mechanical control of bacteriologically undefined dental plaque, and surgical correction of anatomic and morphologic defects associated with JP disease progression (i.e., infrabony pockets, inflamed gingival tissues).<sup>1-6</sup>

Antimicrobial therapy targeted at specific disease-associated bacterial species in the subgingival plaque microbiota also has been suggested for treatment of JP.<sup>7,8</sup> This rationale was applied initially to the treatment of adult periodontitis lesions, and has been referred to widely as the Keyes Technique,<sup>9</sup> or microbiologically modulated periodontal therapy.<sup>10-13</sup> As a therapeutic strategy for the control of specific plaque infections<sup>14,15</sup> associated with human periodontal diseases, it incorporates microbiological evaluations of the subgingival flora, such as with phase-contrast microscopy, into diagnostic decision-making and patient management.<sup>16-21</sup> Additionally, chemical antimicrobial agents are utilized in both office therapy and patient home treatment procedures as adjuncts to mechanical plaque removal techniques, such as root planing, flossing, and toothbrushing.<sup>16-21</sup>

The concept of directing therapeutic measures at specific microbial pathogens in JP has been supported by recent cultural studies of subgingival plaque from

JP subjects. These studies repeatedly have associated elevated numbers of certain species of gram-negative rods with localized JP sites, especially *Haemophilus* (formerly *Actinobacillus*) *actinomycetemcomitans* (*Ha*).<sup>23-25</sup> Further, *Ha* has been shown to elaborate a number of potential virulence factors (e.g., leukotoxin, collagenase, immunoglobulin proteases, fibroblast growth inhibitors, and bone resorption factors), which may be important in the pathogenesis of JP.<sup>26</sup>

Some morphologic studies with phase-contrast, darkfield, and transmission electron microscopy also have revealed large numbers of spirochetes and motile rods in localized JP subgingival plaque.<sup>7,8,21,27-31</sup> Consistent with these findings, elevated serum titers of antibodies specific to antigenic determinants of *Treponema* species also have been reported in individuals with localized JP.<sup>32,33</sup> However, there is evidence that not all localized JP patients harbor high proportions of motile bacteria in their subgingival microflora,<sup>4,23,34,35</sup> and the exact role of these organisms in JP is not well understood.

The purpose of the present investigation was to determine whether the principles of microbiologically modulated periodontal therapy (Keyes Technique)<sup>7,8,10-13, 16-20</sup> could be applied successfully to the long-term clinical management of JP.

## Methods and Materials

This longitudinal therapeutic investigation was conducted within the clinical research facilities of the National Institute of Dental Research (NIDR), of the National Institutes of Health (NIH) in Bethesda, Maryland. The patients studied were selected from persons referred to the NIDR dental clinic for periodontal disease treatment. Seven untreated patients younger than 22 years of age with idiopathic JP, as defined by Baer,<sup>36</sup> were treated and followed for at least 22 months posttreatment (Table 1). Five of the JP patients were classified as having localized cases (first molars, incisors, and additional teeth equaling <14 total teeth), and 2 patients had generalized cases ( $\geq 14$  total teeth involved), based on the number of affected teeth.<sup>37</sup> The 5 females and 2 males in the study had a mean age of 18 years (range = 12-21 years), and 193 teeth on initial examination. The follow-up clinical observations on the patients ranged from 22 to 39 months posttreatment, with a mean of 29.6 months.

All patients were in good general health and presented with radiographic evidence of >50% bone loss associated with the permanent first molars and incisors (Fig 1), and clinical attachment loss of  $\geq 7$  mm at these sites. Comprehensive medical and dental histories were obtained, with particular emphasis on

any renal disorders, hypertension, sodium intake restrictions, or previous allergic reactions to tetracycline antibiotics. All patients underwent complete physical and hematological examinations (including CBC, SMA-12, and urinalysis) conducted by the NIH Clinical Center medical staff to exclude the presence of any contributing systemic medical disorders. None of the subjects had any systemic disorders reported to be associated with periodontal manifestations in adolescents, such as diabetes mellitus, sarcoidosis, Down's syndrome, cyclic neutropenia, agranulocytosis, Pappillon-Lefèvre syndrome, or Chédiak-Higashi syndrome. In vitro evaluations of neutrophil and monocyte functions were unavailable at the start of these studies, and were not determined for the patients followed. None of the patients had received any type of periodontal prophylaxis or systemic antibiotic therapy during the previous 6-month period.

## Diagnostic Procedures

### Clinical Examinations

Clinical parameters for all teeth were assessed independently by a single NIDR staff periodontist (author WEW) who was unaware of the patient's course of therapy (single-blind evaluation). Periodontal probing depths and clinical attachment levels were measured to the nearest mm at interproximal and buccal surfaces of all teeth with a calibrated probe, as described by Philstrom et al.<sup>38</sup>

The degree of gingival inflammation for each tooth was determined by scoring the amount of bleeding seen after gentle probing to the "bottom" of the gingival sulcus. A sulcular bleeding score was assigned as follows: 0 = no bleeding, 1 = spot bleeding point only, 2 = bleeding along the gingival margin.

### Microbiological Examinations

At each patient appointment, the composition of the subgingival plaque was monitored with phase-contrast microscopy at chairside to assess the effectiveness of the therapeutic measures. No cultural or immunologic monitoring was conducted as part of this study.

Enumeration of disease-associated morphotypes in subgingival plaque samples with phase-contrast microscopy followed procedures previously described,<sup>7,16-21</sup> and included counts of spirochetes, brush formations, motile rods (large-, medium-, and small-sized), oral protozoa (i.e., *Entamoeba gingivalis*, *Trichomonas tenax*), and accumulated crevicular polymorphonuclear leukocytes.

Briefly, subgingival plaque was removed carefully from periodontal sites with a sterile curette, placed

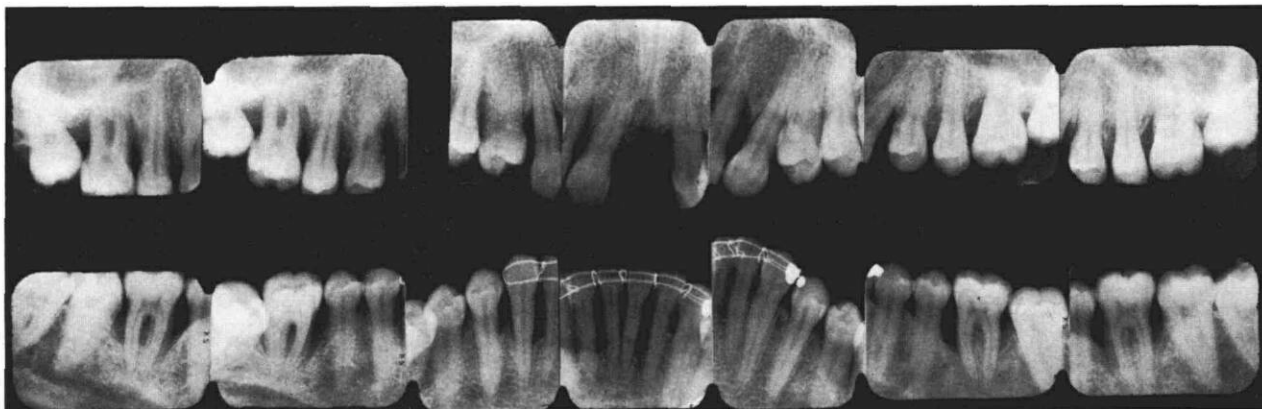


FIG 1. Typical molar/incisor angular defects associated with untreated JP lesions.

into 0.02 ml of sterile water on a microscopic slide, coverslipped, and examined immediately at 400x and 600x with a high quality, phase-contrast microscope. The highest scoring fields for each of the bacterial and cellular morphotypes then were recorded.

Based on previous research,<sup>17,18,21</sup> patients with periodontal pockets harboring  $\geq 125$ /highest scoring fields of either spirochetes, medium- or large-sized motile rods (spinning,  $2 \times 3-9^+ \mu\text{m}$ ), or crevicular polymorphonuclear leukocytes were considered in this study to have elevated numbers of disease-associated morphotypes. Small, highly motile coccobacilli ( $0.1-0.2 \mu\text{m}$  in diameter), which exhibited a circular "darting" motion, were not considered to be disease-associated in this study, since previous reports have found this plaque morphotype predominantly in healthy periodontal sites.<sup>17,18</sup>

Multiple ( $\geq 2$ ) periodontal sites in each patient were monitored microbiologically as a supplement to clinical periodontal parameters. Advanced periodontal pockets and furcations in particular were monitored closely throughout the posttreatment observation periods, since the possibility of a disease-associated flora remaining in subgingival sites after the completion of treatment is known to increase significantly with residual probing depth.<sup>39,40</sup>

As these sites came into microbiological control, samples from additional surfaces less severely involved in each quadrant were evaluated to confirm suppression of the disease-associated morphotypes. However, microbiological data reported in the results section is limited to levels of disease-associated morphotypes in periodontal sites presenting at recall appointments with the worst clinical conditions (i.e., gingival inflammation) in each patient, and/or surfaces having the greatest residual probing depth or furcation involvement. For some patients, additional microbiological observations were collected for sev-

eral months after the last posttreatment clinical evaluations were made.

## Therapeutic Procedures

### Professional Office Therapy

All teeth were subjected to meticulous subgingival scaling and root planing until a smooth, hard root surface was detected clinically. Chemical antimicrobial agents actively were delivered subgingivally and maintained in periodontal pockets throughout these procedures. Between instrumentation of different root surfaces, instruments were disinfected routinely by passage through antiseptic solutions, such as 1% chloramine-T (sodium para-toluene sulfonchloramide), or 3% hydrogen peroxide saturated with sodium chloride.

All periodontal pockets were irrigated professionally to probing depth before, during, and after mechanical instrumentation with chemical antimicrobial agents. Chloramine-T (1%) was used for this purpose, along with a saturated inorganic salt solution consisting of sodium bicarbonate ( $\text{NaHCO}_3$ ) or sodium chloride ( $\text{NaCl}$ ).

To facilitate rapid subgingival drug delivery to probing depth, especially into advanced sites ( $\geq 7$  mm) and furcations, oral irrigation devices were modified with foot-activated on/off switches, and equipped with monojet irrigation tips having 23- or 25-gauge blunt needle or cannula extensions 10 mm long, as described elsewhere.<sup>41</sup> The extended tip was advanced like a periodontal probe to probing depth and into furcations to maximize contact and exposure of subgingival plaque bacteria to the antiseptic agents during the mechanical debridement sessions.

Approximately 4-6 hr were required for initial mechanical instrumentation and professionally applied

subgingival chemotherapy. No surgical flaps or osseous recontouring procedures were employed. All carious lesions and defective restorations were restored or replaced as needed.

### Patient Home Treatment Procedures

All patients were instructed in sulcular toothbrushing and flossing. As previously described,<sup>7,8</sup> patients also were directed to apply daily a saturated inorganic salt solution (i.e., 2 tablespoons of NaHCO<sub>3</sub> or NaCl dissolved into 12 fl oz warm water) with an oral irrigation device (unmodified) at a moderate-to-high pressure setting. This was then to be followed by application of a sodium bicarbonate/3% hydrogen peroxide paste or slurry to the dentogingival surfaces via toothbrushing, flossing, interdental brushes, and rubber cone stimulators (#600<sup>a</sup>). Instruction and reinforcement was emphasized to encourage the patients to deliver the antimicrobial chemicals as deeply as possible into the sulcus/pocket spaces during the self-applied treatments. All of the patients were capable of completing this home treatment regimen in approximately 10-15 min.

At each recall appointment, patients viewed phase-contrast microscopic projections showing the bacteriologic composition of their subgingival plaque on equipment previously described.<sup>7</sup> This served as a feedback mechanism aiding in patient education, motivation, and compliance with prescribed home treatment procedures. The microscopic analysis also aided the treating clinician in assessing the self-care ability of patients to deliver antimicrobials into the targeted treatment sites.

### Modulation of Therapy

The antimicrobial effects of the professional and home treatment procedures were monitored by (1) clinical examinations for evidence of changes in gingival inflammation and periodontal attachment level, and (2) phase-contrast microscopy to determine whether a satisfactory elimination of the initial periodontopathic subgingival flora had been obtained. Levels of motile bacteria and accumulated crevicular polymorphonuclear leukocytes in subgingival plaque samples were used in this study as "indicator" morphotypes to assess the presence of a disease-associated subgingival flora, and to identify patients at increased risk of destructive disease activity.

Patients suffering additional clinical deterioration and/or identified as remaining with elevated numbers of disease-associated morphotypes in their subgingival flora after repeated use of the locally applied chemomechanical procedures described above, were

placed on a short-term course of systemic tetracycline HCl therapy (1 gm/day for 14 days). As previously stated, patients with periodontal sites harboring  $\geq 125$ /highest scoring fields of either spirochetes, medium- to large-sized motile rods (spinning,  $2 \times 3-9+ \mu\text{m}$ ), or crevicular leukocytes were considered in this study to have elevated numbers of disease-associated morphotypes. The effects of adjunctive antibiotic therapy on motile bacteria and crevicular leukocyte levels were checked by examining new subgingival plaque samples with phase-contrast microscopy at the end of the 14-day drug course.

Periodontal recall therapy was carried out at approximately 2-3 month intervals, and included reinforcement of patient home treatment procedures, mechanical instrumentation of all tooth surfaces, and subgingival irrigations to probing depth of all sites with chemical antimicrobial agents. Additional systemic tetracycline therapy as described above was prescribed if further clinical deterioration appeared and/or persistent reinfection of the subgingival microflora with high levels ( $\geq 125$ /highest scoring fields) of motile bacteria or accumulated crevicular leukocytes were seen with phase-contrast microscopic monitoring.

### Data Analysis

Patient means for probing depth and attachment level were calculated after categorizing the baseline and posttreatment data on the basis of the covariate of the original probing depth, as suggested by Pihlstrom et al.,<sup>38</sup> into 3 categories of pockets initially 1-3 mm, 4-6 mm, and those  $\geq 7$  mm. A paired *t*-test was utilized to determine statistically significant differences with treatment in probing depth and attachment level from baseline measurements. A value of  $p \leq 0.05$  was required for statistical significance.

The number of sites having major changes in attachment level ( $\geq 3$  mm) between baseline and posttreatment examinations were tabulated to supplement interpretation of mean values reported for attachment level alterations, as suggested by Haffajee et

TABLE 1. Patient Characteristics

Patient	Diagnosis	Age	Race	Sex	Length of Follow up (mo)
1. JP	LJP	12	B	F	36
2. JG	LJP	16	B	F	31
3. TC	LJP	19	B	F	39
4. NS	LJP	21	C	F	22
5. JB	LJP	21	B	M	25
6. JM	GJP	16	B	F	25
7. JF	GJP	21	C	M	29
		$\bar{x} = 18$			$\bar{x} = 29.6$

LJP = localized case, GJP = generalized case.

<sup>a</sup> #600 — John O. Butler Co: Chicago, IL.

al.<sup>42</sup> This enabled determination of the frequency of significant clinical improvement or deterioration at individual periodontal sites which, according to Lindhe et al.,<sup>43</sup> are unlikely to be explained by measurement error.

Differences in the frequency distribution of sulcular bleeding scores and microbiological parameters between baseline and posttreatment examinations were analyzed by the Wilcoxon rank sum test.<sup>44</sup>

## Results

### Clinical Findings

**Tooth Mortality:** None of the 193 teeth treated in the 7 JP patients were lost during the course of the study.

**Gingival Inflammation:** The degree of gingival inflammation, as measured by the amount of bleeding on probing, was reduced significantly at the posttreatment examinations from the pretreatment baseline measurements ( $p < 0.01$ , Table 2). Prior to the start of periodontal therapy, 56.1% of all teeth had sulcular bleeding scores of 2. At the posttreatment evaluations, sulcular bleeding scores of 2 were found on only 5.6% of all teeth, while 65.8% of all teeth had no bleeding on probing present (Table 2). A similar reduction in gingival inflammation was seen on a subset of 124 teeth (64.2% of all teeth) having one or more surfaces with  $\geq 5$  mm of attachment loss. Sulcular bleeding scores of 2 were found on only 4.8% of these severely affected teeth after treatment, compared to 66.9% before treatment.

**Mean Probing Depth and Clinical Attachment Level Changes — (A) For Sites Initially 1-3 mm:** Sites with initial probing depths of 1-3 mm experienced a statistically significant slight decrease in probing depth (0.10 mm) following treatment. No statistically significant changes in clinical periodontal attachment were associated with treatment of initially shallow surfaces (Table 3).

**(B) For Sites Initially 4-6 mm:** Periodontal pockets initially 4-6 mm in depth exhibited a statistically significant ( $p < 0.01$ ) decrease from pretreatment baseline values in pocket depth of approximately 1 mm, and a mean gain in clinical periodontal attachment level of 0.77 mm (Table 3).

**(C) For Sites Initially  $\geq 7$  mm:** In advanced JP sites

initially  $\geq 7$  mm, marked decreases (mean = 2.85 mm) were found with therapy in pocket depth (Table 3). Most of the pocket depth reductions were due to large gains in clinical periodontal attachment levels. An average of 2.66 mm of clinical periodontal attachment level gain relative to the pretreatment measurements was recorded at advanced sites after treatment (Table 3). Both the mean probing depth and clinical periodontal attachment level changes seen with treatment were statistically significant from pretreatment baseline values ( $p < 0.01$ ).

**Prevalence of Major Changes in Clinical Attachment Level:** A  $\geq 3$  mm gain in clinical periodontal attachment level from pretreatment values following therapy was recorded at 62 sites in 6 of the study patients. These individual surfaces experiencing large beneficial changes in clinical periodontal attachment level represented 10.7% of all sites followed in the study patients, and 25.8% of sites with initial clinical periodontal attachment loss of  $\geq 5$  mm.

Sites having major loss of clinical periodontal attachment during the posttreatment observation periods were rare. Seven sites in 3 patients, constituting 1.2% of all sites treated, suffered a  $\geq 3$  mm loss of clinical periodontal attachment from the pretreatment baseline measurements. Of these 7 sites, 1 initially had clinical periodontal attachment loss of 5 mm, and 6 had initial loss of 2-3 mm.

**Adverse Reactions and Side Effects:** No adverse reactions or side effects to systemic tetracycline therapy occurred in the patients followed. No adverse reactions or side effects (such as periodontal abscesses) were associated with daily applications of inorganic salt solutions with an oral irrigation device at moderate-to-high pressure settings. Daily use of an  $H_2O_2/NaHCO_3$  slurry as a topical antimicrobial treatment agent did not lead to black hairy tongue conditions, or damage hard or soft tissues in any of the patients after completion of initial periodontal therapy.

## Microbiological Findings

### Pretreatment

Prior to the start of any therapy, all subgingival plaque samples examined from the study subjects contained high levels ( $\geq 125$ /highest scoring fields) of spirochetes, medium- to large-sized motile rods (spinning,  $2 \times 3-9^+ \mu m$ ), and accumulated crevicular polymorphonuclear leukocytes (Figs 2-4). Highly structured brush formations with coordinated spirochetal movement, as previously described,<sup>17,18,21</sup> were observed in 58.3% of the pretreatment plaque samples, and oral amoebae (*E. gingivalis*) were present in 41.7%.

TABLE 2. Gingival Inflammation: Bleeding After Probing

	Frequency Distribution of Sulcular Bleeding Scores (all teeth)		
	0	1	2
Baseline	32.0%	9.7	56.1
Posttreatment	65.8	28.6	5.6*

\* Significantly different from baseline,  $p < .01$ .

TABLE 3. Analysis of Mean Differences in Probing Depth and Clinical Attachment Level

Initial Pocket Depth	No. of Sites	Mean Probing Depth Pretreatment (mm)	Mean Probing Depth Posttreatment (mm)*	Mean Probing Depth Reduction (mm)	Mean Clinical Attachment Level Gain (mm)
1-3 mm	339	2.60	2.50	0.10 ± 0.03**	-0.04 ± 0.03 (NS)
4-6 mm	157	4.86	3.79	1.07 ± 0.11**	0.77 ± 0.10**
≥7 mm	83	7.95	5.10	2.85 ± 0.33**	2.66 ± 0.30**

\* Mean = 29.6 mo. \*\* Statistically significant difference from pretreatment, p < 0.01. NS — no statistically significant difference from pretreatment.

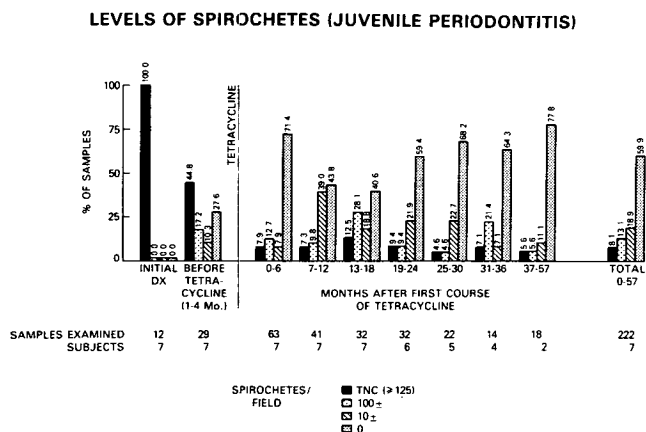


FIG 2. Changes with treatment in subgingival spirochetes.

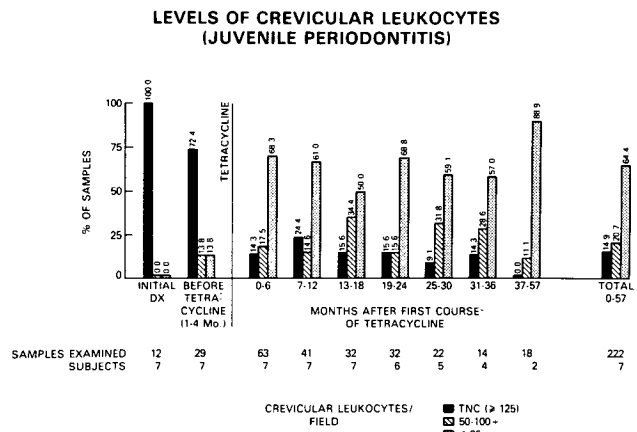


FIG 4. Changes with treatment in crevicular polymorphonuclear leukocytes.

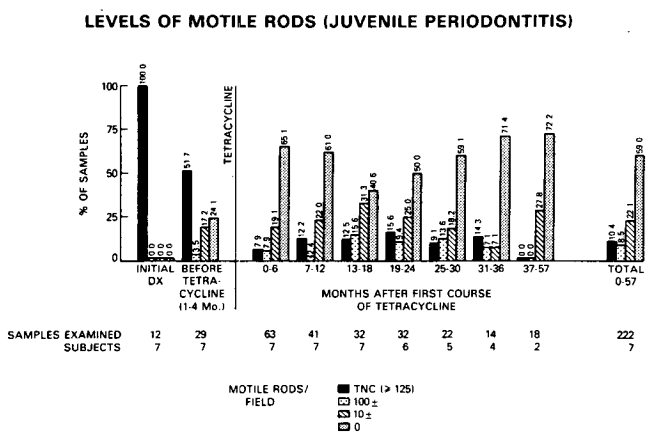


FIG 3. Changes with treatment in subgingival motile rods.

### Pretetracycline Therapy

With local periodontal treatment consisting of repeated root planing, subgingival chemotherapy, and patient home treatment procedures, a significant reduction was achieved during the first 4-month period in the numbers of motile bacteria and crevicular leukocytes in sampled sites (p < 0.01), (Figs 2-4). However, spirochetes, medium- to large-sized motile rods, and crevicular leukocytes still were found to be elevated (≥ 125/highest scoring fields) in 44.8%, 51.7%,

and 72.4%, respectively, of the subgingival plaque samples microscopically examined during this period. Brush formations also were detected in 24.1% of the samples. All of the study subjects had at least one periodontal site remaining with elevated numbers of disease-associated morphotypes (spirochetes, motile rods, and/or crevicular leukocytes present at ≥ 125/highest scoring fields), following application of local periodontal treatments.

Based on the persistence of these disease-associated morphotypes, all of the study patients then were prescribed systemic tetracycline therapy (1 gm/day for 14 days).

### Posttetracycline Therapy

At all time periods after completion of the first course of systemic tetracycline therapy (0-6 months through 37-57 months), the prevalence of spirochetes, motile rods, and crevicular leukocytes was reduced significantly (p < 0.01) relative to the baseline and pretetracycline therapy periods (Figs 2-4). Additionally, brush formations were seen in only 6.3%, and *E. gingivalis* in only 3.2% of the 222 plaque samples examined after the administration of systemic tetracycline therapy.

Immediately after completion of the first 14-day

systemic tetracycline course, all monitored sites (N = 24 sites) had significantly reduced ( $\leq 10$ /highest scoring fields) or undetectable levels of spirochetes and motile rods present in the subgingival microflora. Spirochetes, in particular, appeared quite susceptible, with 91.7% of the plaque samples taken immediately after systemic tetracycline therapy having no spirochetes present. Subsequently, low or undetectable levels of spirochetes were found in 79.3% of the subgingival plaque samples examined during the 0 to 6-month posttetracycline therapy period, and in 78.8% of all samples taken up to 57 months posttreatment (Fig 2). A similar pattern was seen with motile rods, with 71.1% of all samples analyzed up to 57 months posttreatment having only low or undetectable levels of medium- to large-sized motile rods present (Fig 3).

Most monitored sites (70.8%) also had low levels ( $\leq 25$ /highest scoring fields) of crevicular leukocytes immediately after completion of systemic tetracycline therapy. However, 6 periodontal sites, representing 25.0% of the 24 sites monitored during systemic tetracycline therapy, continued to have elevated numbers ( $\geq 125$ /highest scoring fields) of crevicular leukocytes immediately after the 14-day drug course. During the 57-month posttreatment period, a high percentage of monitored sites (85.1%) harbored only low or moderate levels of crevicular leukocytes (Fig 4).

Additional adjunctive systemic tetracycline therapy was prescribed to 6 of the study patients within 12 months of the first antibiotic course. Three patients received additional systemic tetracycline therapy (1 gm/day for 14 days) at approximately 12-month intervals. Three patients required only 1 additional systemic tetracycline course, which was given within 6 months of the original course. In 9 of 11 instances where additional systemic tetracycline therapy was prescribed, elevated levels of both motile bacteria and crevicular leukocytes were seen microscopically. In 6 of these cases, organized brush formations also were present. In 2 cases, additional systemic tetracycline therapy was given where high levels of crevicular leukocytes ( $\geq 125$ /highest scoring fields) alone were being detected consistently, even in the relative absence of motile disease-associated morphotypes in the accompanying subgingival flora.

#### Microscopic Findings Relative to Major Attachment Level Changes

Of the 7 sites which experienced a  $\geq 3$  mm loss of clinical periodontal attachment from pretreatment baseline measurements, 4 of these sites were monitored microscopically throughout the posttreatment observation period. Only 1 of these sites (25%) recolonized with high levels of spirochetes during the

posttreatment period, while only 2 of the sites (50%) were found reinfected with high levels of motile rods. However, in contrast to the findings with motile bacteria, all 4 (100%) of the monitored sites with  $\geq 3$  mm of clinical periodontal attachment loss consistently had high levels ( $\geq 125$ /highest scoring fields) of crevicular leukocytes throughout the posttreatment period. In this regard, none of the 10 microscopically monitored sites experiencing a  $\geq 3$  mm gain in clinical periodontal attachment from pretreatment values had elevated crevicular leukocyte levels present at any examination during the posttreatment period.

#### Discussion

The early onset and rapidly progressive attachment loss characteristic of JP has been related clearly to subgingival colonization by suspected periodontal pathogens, and the presence of host cell-mediated immunodeficiencies, particularly in monocyte and neutrophil leukocyte functions.<sup>45</sup> Considerable research attention is being focused on elucidating the exact nature of these host immune defects, and preliminary studies seeking therapeutic measures to enhance impaired leukocyte functions appear promising.<sup>46,47</sup> However, until these approaches are developed more thoroughly, the clinical management of JP needs to be directed primarily at elimination of the subgingival periodontopathic flora.

The results of the present investigation demonstrate that a combined local and systemically delivered antimicrobial treatment approach can produce long-term apparent arrest of destructive disease activity in most JP lesions without periodontal surgery. Marked clinical improvements were seen posttreatment, with significantly reduced bleeding on probing, decreased probing depths, and gains in clinical periodontal attachment being measured in all of the study subjects.

Pronounced clinical changes were especially evident in JP sites having advanced periodontal breakdown. In sites with initial probing depths of  $\geq 7$  mm, large gains in clinical periodontal attachment (mean = 2.66 mm), and highly significant decreases in probing depth from pretreatment baseline measurements ( $p < 0.01$ ), were associated with the treatment regimen studied (Table 3). Additionally, 25.8% of all treated surfaces presenting with initial clinical periodontal attachment loss of  $\geq 5$  mm experienced a  $\geq 3$  mm gain in clinical periodontal attachment from the pretreatment evaluations. Only 1.2% of all sites treated lost  $\geq 3$  mm of clinical periodontal attachment from baseline values, and no teeth were extracted during the course of the study, despite advanced clinical attachment loss initially present on severely affected teeth.

Standardized probing forces with pressure-sensitive periodontal probes were not used in this study for assessment of clinical parameters. Smaller variances in clinical measurements, though not statistically significant, are found with standardized versus nonstandardized probing forces.<sup>48</sup> However, in the present study, reproducibility of clinical parameters was maintained by having a single periodontist collect (on a single-blind basis) all of the probing depth and clinical periodontal attachment level measurements.

The findings reported here are consistent with other clinical studies describing long-term successful treatment and maintenance of JP lesions.<sup>1,2,4,5</sup> However, the present investigation differs from these previous studies in that (1) microbiologic criteria supplemented clinical parameters for therapeutic decision-making, (2) local subgingival chemotherapy was administered both professionally and in home treatment procedures as adjuncts to mechanical debridement, and (3) no periodontal surgical procedures were employed.

Lindhe<sup>4,5</sup> previously has called for studies of nonsurgical treatment modalities for JP. The observations reported in the present study unequivocally document that stabilization and long-term arrest of most JP lesions can be attained without periodontal surgery. These findings represent the first long-term clinical results beyond 18 months for a nonsurgical therapeutic approach to JP. Similarly, Genco et al.<sup>49</sup> treated 9 localized JP patients with a nonsurgical treatment regimen consisting of scaling and root planing in combination with systemic tetracycline therapy (1 gm/day for 14 days every 8 weeks). Over an 18-month period no further alveolar bone loss was seen with standardized radiographs in any of the molar/incisor infrabony defects monitored, and in one-third of the defects an increase was seen in the alveolar bone levels after treatment.

The study design followed in this investigation does not allow direct comparisons to be made between our nonsurgical treatment results and those reported using periodontal surgery. However, it is clear from the degree of clinical stabilization and long-term arrest of clinical periodontal attachment loss in the patients studied, that surgical intervention may not be an obligatory component critical for the successful management of most JP lesions. In fact, some of the patients treated nonsurgically with these antimicrobial approaches stabilized to such an extent that fixed orthodontic repositioning of maloccluded teeth was carried out without complication.<sup>50</sup> Thus, further investigative research is warranted on nonsurgical treatment modalities based on control of specific disease-associated plaque organisms.

Supplementing mechanical plaque removal ap-

proaches (i.e., root planing, tooth brushing, flossing) with local subgingival applications of chemotherapeutic agents has been suggested previously,<sup>14,51</sup> but rarely utilized in the treatment of adult or JP patients. In carefully controlled clinical studies on adult periodontitis patients,<sup>52,53</sup> subgingival applications of sodium bicarbonate (NaHCO<sub>3</sub>), sodium chloride (NaCl), and hydrogen peroxide were found to enhance significantly the microbiological and clinical effects of periodontal scaling and root planing. Significantly more profound reductions in probing depths, gains in clinical periodontal attachment levels, and increased alveolar bone density in sequential standardized radiographs of interproximal areas were seen after 12 months, especially in advanced sites initially  $\geq 7$  mm in depth, after a combined chemomechanical therapeutic approach was employed.<sup>52</sup>

Rosling et al.<sup>54</sup> also have shown that in multirouted teeth with furcation involvements, where mechanical debridement is difficult and likely to be imperfect, irrigating the furcation areas with chemical antimicrobial agents enhances conventional periodontal therapy. Significantly greater reductions in motile bacteria, and gains in clinical periodontal attachment were found after 1 year in furcated sites that received adjunctive subgingival iodine irrigation during periodontal scaling and root planing.<sup>54</sup>

In JP patients, Adcock et al.<sup>55</sup> have reported that subgingival sodium hypochlorite and 5% citric acid applications used in conjunction with subgingival curettage significantly reduced spirochetes and cultivable gram-negative anaerobic rods for at least a 3-month posttreatment period in advanced localized JP lesions. However, repeated root planing alone, or in conjunction with topically applied 10% povidone-iodine is ineffective in adequately reducing subgingival levels of *Ha* in localized JP pockets.<sup>29,56</sup>

In the present investigation, inorganic salts, chloramine-T, and hydrogen peroxide were used as local chemotherapeutic agents on JP sites. These compounds were selected on the basis of their availability, low toxicity, antibacterial properties, and recognition as accepted dental therapeutic agents by the American Dental Association.<sup>57</sup> In contrast, most commercially available toothpastes have almost no antibacterial effects against plaque organisms.<sup>58</sup>

In vitro studies have found that hydrogen peroxide, in addition to its antiseptic properties, can inactivate the inhibitory effects of bacterial endotoxins on gingival fibroblast growth.<sup>59</sup> However, it is not presently known if this occurs in vivo.

Saturated NaHCO<sub>3</sub> and NaCl solutions have been shown to be rapidly bactericidal to oral spirochetes and motile rods, and can induce ultrastructural changes cytotoxic to subgingival plaque microorganisms from diseased sites after brief in vitro exposure.<sup>60</sup> In cul-



turing studies by Newbrun et al.,<sup>61</sup> a large number of suspected periodontopathic microbial species, including organisms closely associated with JP, were found to be highly susceptible in vitro to the antimicrobial effects of NaHCO<sub>3</sub>, NaCl, and chloramine-T. The minimal bactericidal concentrations (MBCs) of NaHCO<sub>3</sub> and NaCl against *Ha* and *Capnocytophaga* were  $\leq 2.5\%$ . The MBCs of these salts were  $\leq 5.0\%$  against *Bacteroides gingivalis*, which also has been implicated as a possible periodontopathogen in generalized JP patients.<sup>62</sup>

The therapeutic doses of these inorganic salts as applied in office and home irrigations in this study were approximately 14% for NaHCO<sub>3</sub>, and 18% for NaCl (i.e., 2 tablespoons of the salt dissolved into 12 fl oz warm water). The 1% chloramine-T concentration used in this study for office irrigation of JP sites is also rapidly bactericidal to oral spirochetes and motile rods,<sup>60</sup> and is effective against *Ha* and *B. gingivalis* at a minimal inhibitory concentration of  $\leq 0.3\%$ .<sup>61</sup> Thus, NaHCO<sub>3</sub>, NaCl, and chloramine-T were introduced repeatedly into JP lesions during this study at therapeutically significant levels known to be bactericidal or inhibitory to suspected periodontopathogens associated with JP lesions.

Regardless of the in vitro capabilities of the aforementioned compounds, it must be stressed that effective clinical use of chemical antimicrobial agents in periodontal therapy requires adequate subgingival drug delivery into the targeted treatment sites. This concept is essential to both professional- and patient-administered regimens. Inorganic salts and hydrogen peroxide do not alter significantly the subgingival microflora or clinical parameters of advanced periodontal pockets if applied only supragingivally, such as with tooth brushing.<sup>63</sup> Similar findings have been reported with mouthrinsing of chlorhexidine<sup>64</sup> and stannous fluoride,<sup>65</sup> presumably because of insufficient sulcular penetration.

In the present study, modified oral irrigation devices with extended tips<sup>41</sup> were employed to overcome these problems in subgingival delivery of chemical antimicrobials into advanced periodontal sites. Additionally, patient home treatment regimens included daily applications of saturated inorganic salt solutions via unmodified oral irrigation devices, in order to extend subgingival bacterial control.

Oral irrigation devices (unmodified) have been shown to penetrate solutions most commonly to 75% of the clinical probing depth of sites  $\geq 7$  mm,<sup>66</sup> and in some studies, to at least 6 mm below the free gingival margin.<sup>67</sup> Eakle et al.<sup>68</sup> also have demonstrated that both oral irrigation with water and 0.1% stannous fluoride can reduce significantly the proportions of spirochetes in the subgingival flora of untreated sites 4 mm or greater in probing depth. Significantly

greater improvements in clinical periodontal parameters were seen in these sites with irrigation of the antimicrobial agent.<sup>69</sup>

Despite the intensive local subgingival chemotherapy and mechanical debridement, all patients in the present investigation required administration of systemic tetracycline therapy, which was given for a 2-week period (1 g/day). This suggests that sustained suppression of disease-associated microscopic morphotypes with nonsurgical treatment modalities may be difficult to attain in advanced JP sites without adjunctive systemic antibiotic therapy. The need for systemic tetracycline therapy most likely was due to the invasion and colonization by periodontopathic bacteria of gingival connective tissues and epithelium adjacent to infected pockets,<sup>70</sup> although no histologic studies of gingival tissue biopsies were conducted to substantiate this hypothesis.

Clinical studies have demonstrated that marked suppression or elimination of subgingival *Ha*, which may invade subepithelial tissues,<sup>70</sup> can be achieved via (1) 3 weeks of systemic tetracycline HCl therapy (1 g/day)<sup>29</sup>, or by (2) surgical excision of inflamed gingival tissues using either soft tissue curettage or periodontal flap surgery.<sup>71</sup> Genco et al.<sup>49</sup> also have reported that the ability of nonsurgical treatments to arrest progressive bone loss in localized JP sites is enhanced significantly with systemic tetracycline therapy.

In the present study, additional courses of systemic tetracycline therapy were needed during maintenance therapy due to the reestablishment of a disease-associated microflora in some sites. This may have been due to incomplete suppression and subsequent regrowth of suspected periodontal pathogens, such as *Ha*, which can persist in some periodontal sites after only 2 weeks of systemic tetracycline therapy.<sup>29</sup> The presence of elevated numbers of crevicular polymorphonuclear leukocytes in 6 periodontal sites immediately after 2 weeks of systemic tetracycline therapy may have reflected the persistence of a periodontopathic subgingival microflora incompletely eradicated by the systemic tetracycline regimen used in this study. However, in all other sites monitored, significant and sustained decreases in subgingival spirochetes, motile rods, and crevicular polymorphonuclear leukocytes were achieved following systemic tetracycline therapy. Low or undetectable levels of these disease-associated morphotypes were maintained for extended periods with local chemomechanical measures (Figs 2-4).

In regard to this, locally applied antimicrobials, such as inorganic salts and chloramine-T, may be particularly valuable during periodontal maintenance. The effects of these agents may act to prolong the immediate efficacy of other therapeutic measures (i.e.,

root planing, tetracycline, periodontal surgery) by favoring posttherapy colonization of treated sites by microbial species which are antagonistic to the regrowth of a pathogenic microbiota. Hillman and Socransky<sup>72</sup> have demonstrated that *Streptococcus sanguis*, *Streptococcus uberis*, and *Actinomyces* taken from healthy periodontal sites or from sites with periodontal disease other than JP are inhibitory to the growth of *Ha* strain Y4. Such species were not present in JP sites highly infected with the *Ha* strain Y4. Bonta et al.<sup>73</sup> also have reported that *S. sanguis*, *S. mitis*, and *S. salivarius* are inhibitory to the growth of *Ha*, and are twice as prevalent in healthy versus diseased sites in JP patients. However, a mutually antagonistic relationship apparently exists between these microbial species, since sonic extracts of *Ha* also exert a bacteriostatic effect against *S. sanguis* and *Actinomyces*.<sup>74</sup>

Clinical research has shown that successful treatment of JP lesions is attained with suppression of *Ha*, and posttreatment colonization of the subgingival ecosystem by *S. sanguis*, anaerobic gram-positive cocci, and *Actinomyces* species.<sup>75</sup> Interestingly, this type of bacterial conversion to a predominantly gram-positive flora may be responsible for the increased posttreatment calculus formation seen in some JP patients by Harvey et al.<sup>35</sup> *S. sanguis* and *Actinomyces* have been found to be less susceptible to the antimicrobial effects of NaHCO<sub>3</sub>, NaCl, and chloramine-T than are *Ha* and most other periodontal pathogens.<sup>61</sup> Thus, subgingival delivery of these antimicrobials during regular office maintenance appointments and by patients may comprise a useful clinical method for altering the subgingival environment, and promoting posttreatment growth of nonpathogenic organisms, like *S. sanguis*, which may act to inhibit further subgingival colonization by some periodontopathic species. In fact, Socransky<sup>76</sup> has suggested that subgingival development of a "protective" flora inhibitory to periodontal pathogens after initial periodontal therapy may be essential for preventing posttreatment disease relapse. Further investigative research on these points is needed.

In this study phase-contrast microscopic analysis of motile rods and spirochetes was unable to identify some JP sites which remained, despite therapy, at increased risk of further destructive disease activity. Four microscopically monitored sites experienced significant clinical deterioration from the pretreatment baseline examinations ( $\geq 3$  mm of clinical attachment loss). Elevated levels of motile rods were found after treatment in 2 of these deteriorating sites, and elevated levels of spirochetes in only 1 of the sites. Similar observations on JP patients have been reported by other investigators.<sup>4,29</sup>

However, the 4 deteriorating sites all consistently harbored elevated levels of crevicular leukocytes

throughout the posttreatment period. High levels of crevicular leukocytes are characteristic of untreated JP sites,<sup>21,77-79</sup> even though these sites commonly are colonized by *Ha*, which elaborates a leukotoxin and factors which inhibit leukocyte chemotaxis.<sup>26</sup> Several studies have found the numbers of crevicular leukocytes in untreated JP sites to be similar to those levels seen in untreated adult periodontitis sites.<sup>21,77-79</sup> Additionally, healthy periodontal sites in JP patients contain approximately tenfold fewer numbers of crevicular leukocytes than diseased sites.<sup>77</sup>

Thus, the presence of elevated crevicular leukocytes after completion of therapeutic measures may reflect the persistence or regrowth of a periodontopathic microbiota. Chairside microscopic counts of crevicular leukocytes then may be particularly valuable as a diagnostic marker in assessing the risk of destructive disease activity, and in determining "endpoints" for periodontal treatment procedures. However, further clinical and laboratory investigations of these approaches are needed.

## Conclusions

In conclusion, the clinical and microbiological observations seen in this study suggest that:

1. JP patients can be treated successfully and maintained on a long-term basis without periodontal surgery if appropriate antimicrobial therapeutic interventions (chemical, mechanical, or both) are targeted against the subgingival periodontopathic microflora.
2. Systemic tetracycline therapy longer than 2 weeks appears necessary if a nonsurgical approach is followed in the treatment of JP. This is presumably to eradicate adequately periodontal pathogens residing in gingival connective tissues and epithelium.
3. Local subgingival application of chemical antimicrobials, such as inorganic salts and chloramine-T, as part of professional- and patient-applied therapy, may be valuable adjuncts in extending the antibacterial effects of mechanical debridement procedures. This may reduce the need for surgical treatment modalities, and may help prevent the reestablishment of a periodontopathic microbiota in JP patients after its suppression by initial periodontal therapy and systemic antibiotics.
4. Microscopic monitoring of motile microorganisms alone in JP subgingival plaque does not identify accurately treated sites remaining at increased risk of disease progression. Additional microscopic monitoring of crevicular leukocyte levels, and/or identification of other disease-associated organisms with cultural or immunological techniques appears necessary.

The authors acknowledge the generous support and assistance of Dr. Andrew Christopher, chairman of the Department of Community Dentistry at Georgetown University, and the NIDR dental clinic staff, especially Drs. Surya Howard, David E. Sarfatti, John Folio, and Michael W. Roberts, chief, NIDR Patient Care Section.

Dr. Rams was a dental staff fellow, Clinical Investigations and Patient Care Branch, National Institute of Dental Research, National Institutes of Health, Bethesda, Maryland. He is now a clinical assistant professor of microbiology, School of Medicine, and community dentistry, School of Dentistry, Georgetown University, Washington, DC 20007, and a postgraduate resident in periodontics, Veterans Administration Medical Center, 408 First Ave., New York, NY 10010. Dr. Keyes was a senior investigator, Laboratory of Microbiology and Immunology, National Institute of Dental Research, National Institutes of Health, and is now a professorial lecturer of community dentistry, School of Dentistry, Georgetown University, and chairman, board of trustees, International Dental Health Foundation, Reston, Virginia. Dr. Wright is a senior staff periodontist, Clinical Investigations and Patient Care Branch, National Institute of Dental Research, National Institutes of Health. Reprint requests should be sent to Dr. Rams.

1. Nahoum H, Tennenbaum B: Long-term study of periodontosis. *J Periodontol* 45:765-71, 1974.
2. Waerhaug J: Plaque control in the treatment of juvenile periodontitis. *J Clin Periodontol* 4:29-40, 1977.
3. Ashrafi MH, Durr DP, Meister F: Early diagnosis and successful management of periodontosis. *JADA* 105:50-55, 1982.
4. Lindhe J: Treatment of localized juvenile periodontitis, in *Host-Parasite Interactions in Periodontal Diseases*, Genco RJ, Mergenhagen SE, eds. Washington, DC: American Society for Microbiology, 1982 pp 382-94.
5. Lindhe J, Liljenberg B: Treatment of localized juvenile periodontitis. Results after 5 years. *J Clin Periodontol* 11:399-410, 1984.
6. Mattout P, Roche M: Juvenile periodontitis: healing following autogenous iliac marrow graft, long-term evaluation. *J Clin Periodontol* 11:274-79, 1984.
7. Keyes PH, Wright WE, Howard SA: The use of phase-contrast microscopy and chemotherapy in the diagnosis and treatment of periodontal lesions — an initial report (I). *Quintessence Int* 9:51-56, 1978.
8. Keyes PH, Wright WE, Howard SA: The use of phase-contrast microscopy and chemotherapy in the diagnosis and treatment of periodontal lesions — an initial report (II). *Quintessence Int* 9:69-76, 1978.
9. Scheffler RM, Rovin S: Preventing and treating periodontal disease with the Keyes technique: a preliminary assessment. *Prev Med* 11:677-95, 1982.
10. Keyes PH: Microbiologically modulated periodontal therapeutics: an introduction. *Quintessence Int* 13:1325-32, 1982.
11. Keyes PH: A treatment rationale for the management of periodontal diseases. *J Alabama Dent Assoc* 68:18-25, 1984.
12. Rams TE: Microbiologically monitored and modulated periodontal therapy. Keyes therapy, pro and con. *J Okla Dent Assoc* 74:23-25, 1983.
13. Keyes PH: Microbiologically monitored and modulated periodontal therapy. *Gen Dent* 33:105-13, 1985.
14. Loesche WJ: Chemotherapy of dental plaque infections. *Oral Sci Rev* 9:65-107, 1976.
15. Loesche WJ: Clinical and microbiological aspects of chemotherapeutic agents used according to the specific plaque hypothesis. *J Dent Res* 58:2404-12, 1979.
16. Rams TE, Keyes PH, Wright WE, Howard SA: Long-term effects of microbiologically modulated periodontal therapy ('Keyes technique') on advanced adult periodontitis. *JADA* 111:429-41, 1985.
17. Keyes PH, Rogosa M, Rams TE, Sarfatti DE: Diagnosis of crevicular infections: disease-associated bacterial patterns in periodontal lesions, in *Host-Parasite Interactions in Periodontal Diseases*, Genco RJ, Mergenhagen SE, eds. Washington, DC: American Society for Microbiology, 1981, pp 395-403.
18. Keyes PH, Rams TE: A rationale for the management of periodontal diseases: rapid identification of microbial 'therapeutic targets' with phase-contrast microscopy. *JADA* 106:803-12, 1983.
19. Keyes PH, Rams TE: Clinical applications of microbiologically monitored and modulated periodontal therapy. *NY State Dent J* 49:478-81, 1983.
20. Rams TE, Keyes PH: A rationale for the management of periodontal diseases: effects of tetracycline on subgingival bacteria. *JADA* 107:37-41, 1983.
21. Rams TE, Keyes PH: Direct microscopic features of subgingival plaque in localized and generalized juvenile periodontitis. *Pediatr Dent* 6:23-27, 1984.
22. Potts TV, Zambon JJ, Genco RJ: Reassignment of *Actinobacillus actinomycetemcomitans* to the genus *Haemophilus* as *Haemophilus actinomycetemcomitans* comb nov. *Int J Sys Bact* 35:337-41, 1985.
23. Newman MG, Socransky SS, Savitt ED, Propas DA, Crawford A: Studies of the microbiology of periodontosis. *J Periodontol* 47:373-79, 1976.
24. Slots J: The predominant cultivable organisms in juvenile periodontitis. *Scand J Dent Res* 84:1-10, 1976.
25. Slots J, Reynolds HS, Genco RJ: *Actinobacillus actinomycetemcomitans* in human periodontal disease: a cross-sectional microbiological investigation. *Infect Immun* 29:1013-20, 1980.
26. Slots J, Genco RJ: Black-pigmented *Bacteroides* species, *Campylobacter* species, and *Actinobacillus actinomycetemcomitans* in human periodontal disease: virulence factors in colonization, survival, and tissue destruction. *J Dent Res* 63:412-21, 1984.
27. Westergaard J, Frandsen A, Slots J: Ultrastructure of the subgingival microflora in juvenile periodontitis. *Scand J Dent Res* 86:421-29, 1978.
28. Tempro PJ, Reynolds HS, Slots J: Microbial morphotypes in periodontal health and disease. *IADR Program and Abstracts*, no 77, 1983.
29. Slots J, Rosling BG: Suppression of the periodontopathic microflora in localized juvenile periodontitis by systemic tetracycline. *J Clin Periodontol* 10:465-86, 1983.
30. Savitt ED, Socransky SS: Distribution of certain subgingival microbial species in selected periodontal conditions. *J Periodont Res* 19:111-23, 1984.
31. Müller H-P, Flores-de-Jacoby L: The composition of the subgingival microflora of young adults suffering from juvenile periodontitis. *J Clin Periodontol* 12:113-23, 1985.
32. Walker J, Tall DB, Suzuki JB, Nauman RK: Antibody to *Treponema denticola* in juvenile periodontitis. *IADR Program and Abstracts*, no 355, 1983.
33. Tew JG, Ranney RR, Scott A, Smibert RM: Serum antibody against treponemes in adolescents and young adults with periodontitis. *IADR Program and Abstracts*, no 176, 1984.
34. Liljenberg B, Lindhe J: Juvenile periodontitis: some microbiological, histopathological, and clinical characteristics. *J Clin Periodontol* 7:48-61, 1980.
35. Harvey RF, Jones WB, Chan ECS, deVries J, Wilika H: Periodontosis. Part III: Barbados study. *Can Dent Assoc J* 47:449-58, 1981.
36. Baer PN: The case for periodontosis as a clinical entity. *J Periodontol* 42:516-20, 1971.

37. Hormand J, Frandsen A: Juvenile periodontitis: localization of bone loss in relation to age, sex, and teeth. *J Clin Periodontol* 6:407-16, 1979.
38. Pihlstrom BL, Ortiz-Campos C, McHugh RB: A randomized four-year study of periodontal therapy. *J Periodontol* 52:227-42, 1981.
39. Slots J, Rosling BG, Emrich LJ, Christersson LA, Genco RJ: Relationship between certain subgingival bacteria and gain or loss of periodontal attachment after periodontal therapy. IADR Program and Abstracts, no 122, 1983.
40. Magnusson I, Lindhe J, Yoneyama T, Liljenberg B: Recolonization of a subgingival microbiota following scaling in deep pockets. *J Clin Periodontol* 11:193-207, 1984.
41. Rams TE, Keyes PH: Modifying oral irrigation devices for subgingival periodontal chemotherapy. *Gen Dent* 32:302-5, 1984.
42. Haffajee AD, Socransky SS, Lindhe J: Comparison of statistical methods of analysis of data from clinical periodontal trials. *J Clin Periodontol* 10:247-56, 1983.
43. Lindhe J, Haffajee AD, Socransky SS: Progression of periodontal disease in adult subjects in the absence of periodontal therapy. *J Clin Periodontol* 10:433-42, 1983.
44. Rimm AA, Hartz AJ, Kalbleisch JH, Anderson AJ, Hoffmann RG: *Basic Biostatistics in Medicine and Epidemiology*. New York; Appleton-Century-Crofts, 1980 pp 275-76.
45. Newman MG: Localized juvenile periodontitis (periodontosis). *Pediatr Dent* 3:121-26, 1981.
46. Debski BF, Ranney RR, Carchman RA: Modulation of neutrophil dysfunctions associated with juvenile periodontitis. IADR Program and Abstracts, no 509, 1982.
47. Nakamura M, Mashimo PA, Genco RJ: Effects of bestatin and forphenicine on polymorphonuclear leukocyte (PMN) functions in periodontal disease. IADR Program and Abstracts, no 1091, 1983.
48. Van der Velden U, deVries JH: The influence of probing force on the reproducibility of pocket depth measurements. *J Clin Periodontol* 7:414-20, 1980.
49. Genco RJ, Cianciola LJ, Rosling B: Treatment of localized juvenile periodontitis. IADR Program and Abstracts, no 872, 1981.
50. Folio J, Rams TE, Keyes PH: Orthodontic therapy in patients with juvenile periodontitis: clinical and microbiologic effects. *Am J Orthod* 87:421-31, 1985.
51. Keyes PH, Shern RJ: Chemical adjuvants for control and prevention of dental plaque disease. *J Am Soc Prev Dent* 1:18-34, 1971.
52. Rosling BG, Slots J, Webber RL, Christersson LA, Genco RJ: Microbiological and clinical effects of topical subgingival antimicrobial treatment on human periodontal disease. *J Clin Periodontol* 10:487-514, 1983.
53. Rosling BG, Christersson LA, Slots J, Genco RJ: Predictability of topical and subgingival antimicrobial therapy in the management of advanced adult periodontitis. IADR Program and Abstracts, no 1672, 1985.
54. Rosling BG, Slots J, Christersson LA, Genco RJ: Clinical and microbiological effects of surgical and nonsurgical treatment of multi-rooted teeth in adult periodontitis. IADR Program and Abstracts, no 311, 1984.
55. Adcock JE, Berry WC, Kalkwarf KL: Effect of sodium hypochlorite solution on the subgingival microflora of juvenile periodontitis lesions. *Pediatr Dent* 5:190-94, 1983.
56. Robertson PB, Kornman KS: Longitudinal clinical and microbiological evaluation of therapy for juvenile periodontitis. IADR Program and Abstracts, no 316, 1984.
57. ADA Council on Dental Therapeutics: *Accepted Dental Therapeutics*, 37th ed. Chicago; American Dental Association, 1977.
58. Moran J, Addy M: The antibacterial properties of some commercially available toothpastes in vitro. *Br Dent J* 156:175-78, 1984.
59. DeRenzi FA: Endotoxin-inactivating potency of hydrogen peroxide: effect on cell growth. *J Dent Res* 60:933-35, 1981.
60. Rams TE, Keys PH, Jensen AB: Morphological effects of inorganic salts, chloramine-T, and citric acid on subgingival plaque bacteria. *Quintessence Int* 15:835-44, 1984.
61. Newbrun E, Hoover CI, Ryder MI: Bactericidal action of bicarbonate ion on selected periodontal pathogenic microorganisms. *J Periodontol* 55:658-67, 1984.
62. Mouton C, Hammond PG, Slots J, Genco RJ: Serrum antibodies to oral *Bacteroides asscharolyticus* (*Bacteroides gingivalis*): relationship to age and periodontal disease. *Infect Immun* 31:182-92, 1981.
63. Cerra MB, Killoy WJ: The effect of sodium bicarbonate and hydrogen peroxide on the microbial flora of periodontal pockets. *J Periodontol* 53:599-603, 1982.
64. Flótra L, Gjerme P, Rólla G, Waerhaug J: A 4-month study on the effect of chlorhexidine mouthwashes on 50 soldiers. *Scand J Dent Res* 80:10-17, 1972.
65. Tinanoff N, Hock J, Camosci D, Hellden L: Effect of stannous fluoride mouthrinse on dental plaque formation. *J Clin Periodontol* 7:232-41, 1980.
66. Eakle WS, Ford CM: Depth of penetration of periodontal pockets with oral irrigation. IADR Program and Abstracts, no 1550, 1984.
67. West B: An evaluation of an oral irrigation device's ability to reduce the microbial count of subgingival plaque at 6 mm in depth. Thesis, University of Missouri at Kansas City School of Dentistry, 1983.
68. Eakle W, Buchanan S, Leggott P, Quinn R, Boyd R, Chambers D: Daily oral irrigation with 0.1% SnF<sub>2</sub> to control subgingival bacteria. IADR Program and Abstracts, no 356, 1983.
69. Boyd RL, Leggott P, Eakle S, Quinn RS, Buchanan S, Chambers D: Effect of daily irrigation with 0.1% SnF<sub>2</sub> in control of periodontal disease. IADR Program and Abstracts, no 1090, 1983.
70. Saglie FR, Carranza FA, Newman MG, Cheng L, Lewin KL: Identification of tissue-invading bacteria in human periodontal disease. *J Periodont Res* 17:452-55, 1982.
71. Christersson L, Slots J, Rosling B, Genco RJ: Suppression of *Actinobacillus actinomycetemcomitans* in localized juvenile periodontitis. IADR Program and Abstracts, no 256, 1983.
72. Hillman JD, Socransky SS: Bacterial interference of *Actinobacillus*. IADR Program and Abstracts, no 1174, 1981.
73. Bonta Y, Zambom JJ, Christersson LA, Genco RJ: Distribution of bacterial inhibitors to *Actinobacillus actinomycetemcomitans* in localized juvenile periodontitis patients. IADR Program and Abstracts, no 1014, 1985.
74. Hammond BF, Stevens RH, Bonner P, Lillard SE: Toxicity of *Actinobacillus actinomycetemcomitans* extracts for crevicular bacteria. IADR Program and Abstracts, no 830, 1984.
75. Haffajee AD, Socransky SS, Ebersole JL, Smith DJ: Clinical, microbiological, and immunological features associated with the treatment of active periodontosis lesions. *J Clin Periodontol* 11:600-618, 1984.
76. Socransky SS: Microbiology of plaque. *Compend Cont Educ Dent Suppl* 5:53-56, 1984.
77. Murray PA, Patters MR: Gingival crevice neutrophil function in periodontal lesions. *J Periodont Res* 15:463-69, 1980.
78. Barnett ML, Baker RL: Ultrastructure of crevicular washings from advanced periodontal lesions in youths. IADR Program and Abstracts, no 1260, 1982.
79. Sandholm L: Cells and cellular interactions in gingival crevice washings from patients with juvenile periodontitis. *Scand J Dent Res* 92:436-42, 1984.