

Tooth and foreign object in the nasal fossa of a child with a cleft: case report

Dennis N. Ranalli, DDS, MDS Betty Jane McWilliams, PhD
William S. Garrett, Jr., MD

Abstract

A report is presented of a male patient, 5 years, 10 months old, with a palatal cleft complicated by both a tooth and a foreign object in the nasal cavity. The presence of these concurrent conditions contributed to nasal obstruction with associated speech problems, accretions, and chronic rhinorrhea. The importance of a thorough diagnostic work-up and interdisciplinary treatment planning is emphasized.

Literature Review

The occurrence of dental anomalies such as congenitally missing, malformed, and supernumerary teeth in children with clefts has been documented to be more frequent than in the noncleft population (Jordan et al. 1966; Fishman 1970; Jacobson and Rosenstein 1970; Ranta 1982). Furthermore, the treatment of these abnormalities has been shown to contribute to the total health care of children with clefts (Fishman 1970).

In addition to morphologic variability, children with clefts exhibit numerous abnormal conditions related to tooth position and occlusal development. Conditions have been reported such as posterior crossbite (Schwartz et al. 1984), ectopic eruption of the maxillary permanent first molars (Carr and Mink 1965; Ranalli et al. 1986), and eruption of teeth into the nasal cavity (King and Lee 1987). However, teeth in the nasal cavity are rare. King and Lee (1987) recommended early diagnosis and treatment to prevent secondary infection and to improve patency of the nasal airway.

The presence of foreign objects in the oral and nasal structures of children has been reported often. In many of these instances, such objects have been discovered during pretreatment diagnostic dental radiographic examinations (Goldstein and Gottlieb 1973; Hunter 1973; Grimes and Ranalli 1983). Some of the foreign bodies found were lost dental instruments (Nazif 1971; Bump and Roche 1973; Beerster 1978), and some were objects lodged into the nose by the children themselves (Goldstein and Gottlieb 1973; Hunter 1976).

Objects in the nose decrease nasal air flow, thereby increasing nasal resistance. These objects may result in detectable alterations in the resonance of speech in the form of nasal turbulence, cul-de-sac resonance and hyponasality (McWilliams et al. 1984).

The purpose of this paper is to report an unusual case in which both a tooth and a foreign object were discovered in the right nasal fossa of a child patient with a cleft.

Case Report

A 5-year, 10-month-old white male was referred by his plastic surgeon from another state for team evaluation at the University of Pittsburgh Cleft Palate-Craniofacial Center. The referring physician was concerned that the patient's speech problems were not responding to speech therapy. The patient was well-nourished and well-developed, with a history of hospitalizations for surgical repair of a complete cleft of the right lip, alveolar process, and palate, as well as for several tympanostomies with tubes for the management of middle-ear ailments.

Upon visual examination, the repaired palate appeared to be short, and an asymptomatic fistula on the labial surface of the right alveolar process was noted. An expansion appliance was in place in the maxillary arch to correct a bilateral crossbite secondary to maxillary arch collapse. The patient's oral hygiene and gingival status were normal and the dentition was in good repair.

The patient's hearing was in the borderline range, with losses averaging 23dB for the left ear and 22dB for the right ear. The examining speech pathologist found language development to be excellent, articulation marked by a nasal snort for /s/ and /z/, reduced pressure on sibilants, mild hoarseness, a facial grimace, very slight nasal escape on the left side and none on the right, as well as mild hypernasality combined with cul-de-sac resonance. These combined observations sug-

gested velopharyngeal incompetence complicated by obstruction of the nasal airway, and indicated exploration of the nasal airway (McWilliams et al. 1984).

During headlamp speculum examination, complete occlusion of the right nostril was observed as a result of a tilted alveolar process. Posterior to that, a supernumerary tooth had erupted nasally — the probable cause of the patient's chronic rhinorrhea on the right side. An extraoral lateral radiograph of the nasal area confirmed the presence of the nasal tooth but also revealed an irregularly shaped radiopaque shadow superior and posterior to the tooth (Fig 1). Videofluoroscopic examination confirmed the presence of the tooth in the nasal airway and of the radiopaque shadow. The nasal obstruction on the right precluded placement of contrast medium. Velopharyngeal incompetence also was noted. There was poor motion in the soft palate and inconsistency of movement. However, movement of the lateral pharyngeal walls was excellent. The patient never achieved velopharyngeal closure, and reflux was present during swallowing.

The following recommendations were made to the patient's referring plastic surgeon:

1. Discontinue ongoing speech therapy pending removal of nasal obstructions
2. Continue otological surveillance
3. Arrange for preferential seating in school to provide the best possible auditory environment
4. Perform pharyngeal flap surgery with removal of nasal obstructions
5. Reassess speech three months postoperatively and before reinstating speech therapy.

The nasal tooth was removed, and exploration of the mass revealed significant accretions surrounding small pieces of aluminum foil, which the child apparently had lodged into his nose. The pharyngeal flap was delayed because the nasal surgery had been traumatic, and time was required for recovery and healing before proceeding with further surgery.

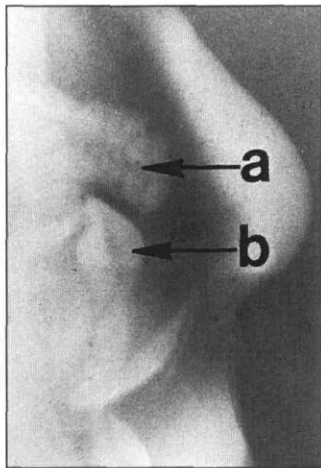


Fig 1. Extraoral lateral radiograph of nasal area of a five-year, 10-month-old white male with unilateral complete cleft of the lip, alveolar process and palate on the right side. Arrow (a) — irregular radiopaque area containing accretions surrounding small pieces of aluminum foil. Arrow (b) — supernumerary tooth in right nasal fossa.

Discussion

This case demonstrates the need for thorough diagnostic evaluations of children who present complex speech problems, before undertaking speech therapy. Since speech problems resulting from increased nasal resistance cannot be modified by speech therapy alone, such intervention has little chance of success.

This case also points to the value of close diagnostic and treatment collaboration among surgeons, dentists, and speech pathologists. Without this kind of close interaction, this child's problem might never have been identified.

Dr. Ranalli is director, advanced pediatric dentistry program; coordinator of dental services, cleft palate craniofacial center; and interim associate dean at the University of Pittsburgh, School of Dental Medicine, Pittsburgh, PA. Dr. McWilliams is professor of speech pathology and director, cleft palate craniofacial center; Dr. Garrett is assistant professor of plastic surgery and coordinator of clinical services, cleft palate craniofacial center; both are also at the University. Reprint requests should be sent to: Dr. Dennis N. Ranalli, University of Pittsburgh, School of Dental Medicine, 362 Salk Hall, Pittsburgh, PA 15261.

- Beernster G: Unusual position for a rubber dam clamp. *Oral Surg* 45:979-80, 1978.
- Bump RL, Roche WC: A broken needle in the pterygomandibular space. *Oral Surg* 36:750-52, 1973.
- Carr GE, Mink JR: Ectopic eruption of the first permanent maxillary molar in cleft lip and cleft palate children. *ASDC J Dent Child* 32:179-88, 1965.
- Fishman LS: Factors related to tooth number, eruption time, and tooth position in cleft palate individuals. *ASDC J Dent Child* 37:303-306, 1970.
- Goldstein E, Gottlieb MA: Foreign bodies in nasal fossa of children. *Oral Surg* 36:446-47, 1973.
- Grimes ML, Ranalli DN: Projectile in the cheek of a child: case report. *Pediatr Dent* 5:149, 1983.
- Hunter K: Foreign body in nasal fossa. *Oral Surg* 41:805, 1976.
- Jacobson BN, Rosenstein SW: The cleft palate patient: dental help needed. *ASDC J Dent Child* 38:105-15, 1970.
- Jordan RE et al: Dental abnormalities associated with cleft lip and/or palate. *Cleft Palate J* 3:22-55, 1966.
- King NM, Lee AMP: An intranasal tooth in a patient with a cleft lip and palate: report of case. *J Am Dent Assoc* 114:475-77, 1987.
- McWilliams BJ et al: *Cleft Palate Speech*. Philadelphia: BC Decker Inc, 1984, pp 192-93; 221-30; 245-46.
- Nazif M: A rubber dam clamp in the nasal cavity: report of case. *J Am Dent Assoc* 82:1099-1100, 1971.
- Ranalli DN et al: Comparative analysis of ectopic eruption of maxillary permanent first molars in children with clefts. *ASDC J Dent Child* 53:433-35, 1986.
- Ranta R: Comparison of tooth formation in noncleft and cleft-affected children with and without hypodontia. *ASDC J Dent Child* 49:197-99, 1982.
- Schwartz BH et al: Early prediction of posterior crossbite in the complete unilateral cleft lip and palate. *Cleft Palate J* 21:76-81, 1984.