

## Diastrophic dysplasia: case report

Aurelio Ruiz, BS, DMD

### Abstract

*This report describes the clinical features of an 11-year-old male whose genetic evaluation supports the diagnosis of diastrophic dysplasia. A professional team evaluated and treated him with regard to facial development, various physical problems, and pediatric dental management of his intraoral conditions. Cardiopulmonary function often is compromised because of kyphoscoliosis. This along with the presence of a cleft palate defect, indicates a need for special dental management.*

**H**andicapped persons can benefit greatly when a team of professionals work together to overcome health problems. Medical professionals, including the pediatric dentist, must be knowledgeable about specific illnesses and syndromes to which the term "handicapped" may apply. This knowledge is imperative for the effective management of the handicapped patient.

Diastrophic dysplasia, one of the dyschondroplasia syndromes, has been reported widely in the literature.<sup>1</sup> However, none of these reports describe the dental problems or their management. The purpose of this paper is to present a patient with this condition, discuss the diagnosis, and establish some of the more important parameters involved in managing the accompanying oral and dental problems.

### Literature Review

Diastrophic dysplasia is only one of the multiple, inherited skeletal disorders identified as a dyschondroplasia. Maroteaux separated this condition from achondroplasia by establishing its clinical and radiographic characteristics.<sup>1</sup> Until that time, achondroplasia had been a blanket term applied to this heterogeneous group of cartilage disorders. Never-

theless, achondroplasia remains the prototype of dwarfism with shortening of the extremities.

The term diastrophic dysplasia is derived from the Greek word "diastrophos," literally curved or bent.<sup>2</sup> In 1977 the Second International Conference of Nomenclature for Constitutional Osseous Disorders established the term diastrophic dysplasia. The condition is inherited as an autosomal recessive trait and is diagnosed readily at birth.<sup>3-5</sup> McKusick identified 69 reports in the literature.<sup>6</sup> Taybi reported the first two cases in the United States in 1963.<sup>7</sup>

In 1974 Herr and Goulin stated that at that time 121 cases had been reported in the literature and essentially all were published in journals of orthopedics, radiology, or pediatrics.<sup>8</sup> The diagnostic features of this condition include:

1. Severe reduced height and short extremities
2. Deformities of the hands and feet with hitchhiker thumbs, talipes equinovarus, and symphalangism
3. Rigid ear pinnae with cystic masses on the external margins of the helix that appear between 1 and 12 weeks after birth (This inflammatory cystic process is associated with ossification of the ear cartilage in 85% of the cases.)
4. Cleft palate
5. Normal intelligence
6. Thoracolumbar kyphoscoliosis in the majority of cases
7. Multiple contractures of joints.

The condition affects males and females in the same frequency and the condition also is reported in siblings. Parents were not affected in any reports, although a history of consanguinity has been noted.

The prognosis for diastrophic dysplasia is good, but the prenatal mortality rate is high. After infancy, life expectancy is improved unless the severe type of

scoliosis compromises cardiac and pulmonary function.

Patient management is essentially symptomatic. Orthopedic surgery is available for the feet, and, if combined with orthopedic braces and physical therapy, these may be all that are required unless the defect is more severe. However, the typically complex nature of this disorder dictates a team approach including genetic, social, and psychological practitioners, pediatric dentists, physiotherapists, plastic and orthopedic surgeons, and specialists in physical medicine.

The differential diagnosis includes achondroplasia, Morquio's syndrome (mucopolysaccharoidosis type IV), spondyloepiphyseal dysplasia, multiple epiphyseal dysplasia, and even arthrogyryposis multiplex congenita. From a genetic counseling standpoint, this differential diagnosis is critical in that those affected must be distinguished from achondroplasia which is inherited dominantly. Diastrophics have normal-sized heads and faces compared to achondroplasts and lack the trident hand deformities. Most importantly, diastrophic patients are not prone to nerve root and cord compression in the lumbar spine area.

Prenatal diagnosis can be made by ultrasonography. Mantagos et al. identified a case by ultrasonography at 20 weeks gestation.<sup>9</sup> The diagnosis was confirmed by examination of the aborted fetus. In 1980 O'Brien reported a patient with diastrophic dysplasia diagnosed by ultrasonography in a mother who previously had given birth to an affected child.<sup>10</sup>

## Case Report

An 11-year-old Puerto Rican male was referred to the Pedodontic Department of the Pediatric University Hospital, Puerto Rico Medical Center, for restorative treatment (Fig 1). Included in this patient's evaluation was a team professional approach encompassing surgery, orthopedics, genetics, and other services. Complete radiographic studies were performed including studies of the long bones, hands, feet, chest, head, maxillary arches, and teeth.

The Genetics Department established the diagnosis of diastrophic dysplasia. Physical examination revealed the characteristics considered typical for this condition. The patient presented with blood pressure of 102/86, pulse of 94/min, weight of 29 kg, height of 32 in, occipital-frontal circumference of 19 7/8 in, severe deformity of chest, hitchhiker thumbs (Figs 2, 3), kyphoscoliosis, bilateral talipes equinovarus (Fig 4), cleft palate, and multiple joint contractures. Routine blood studies gave values within normal limits. The facies was characteristic for diastrophic dysplasia. There was a normal-sized skull with increased philtral length, a prominent circumoral area, length-

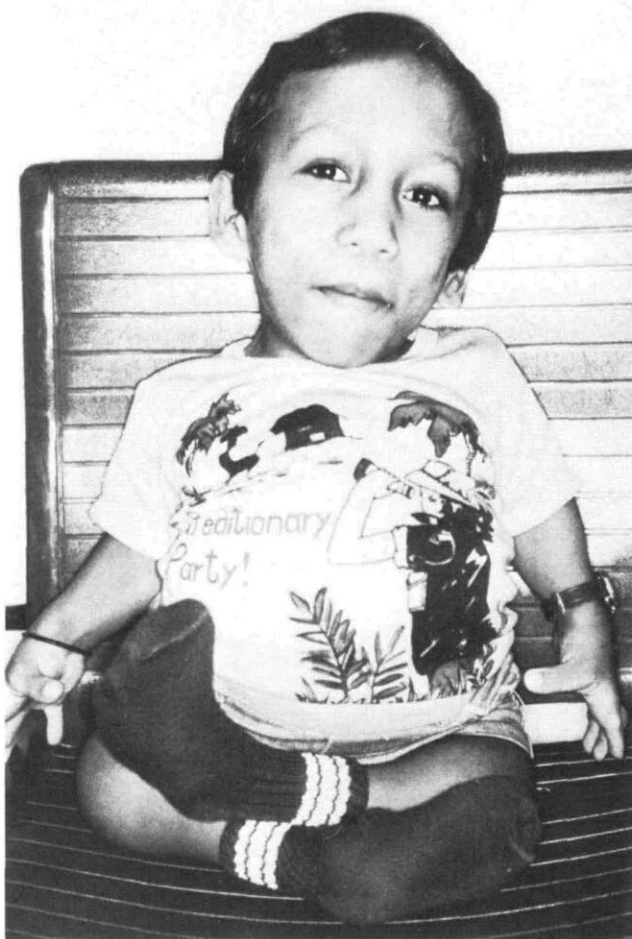


Fig 1. Patient reported with a diagnosis of diastrophic dwarfism.

ened facial appearance, and wide, prominent forehead. A psychological evaluation revealed borderline normal IQ and a social work evaluation established the patient's independence in most daily activities as well as his desire for self-ambulation.

Additional radiographic studies confirmed the presence of a distorted skull-vertebral articulation with the odontoid process parallel to the foramen magnum (Fig 4). The dental evaluation included an orthodontic work-up with full-mouth radiographs, Panorex®, cephalometrics, and study models. All these diagnostic aids revealed an exaggerated vertical development of cranial base and lack of space sufficient to accommodate the maxillary canine teeth, allowing for an eruption of other permanent teeth. Clinical examination demonstrated a convex facial profile, small nose, hypotonic superior perioral musculature, hypertonic inferior perioral musculature, facial symmetry, an obtuse nasolabial angle with open bite and tongue-thrust habit, but normal insertion of buccolabial frena.

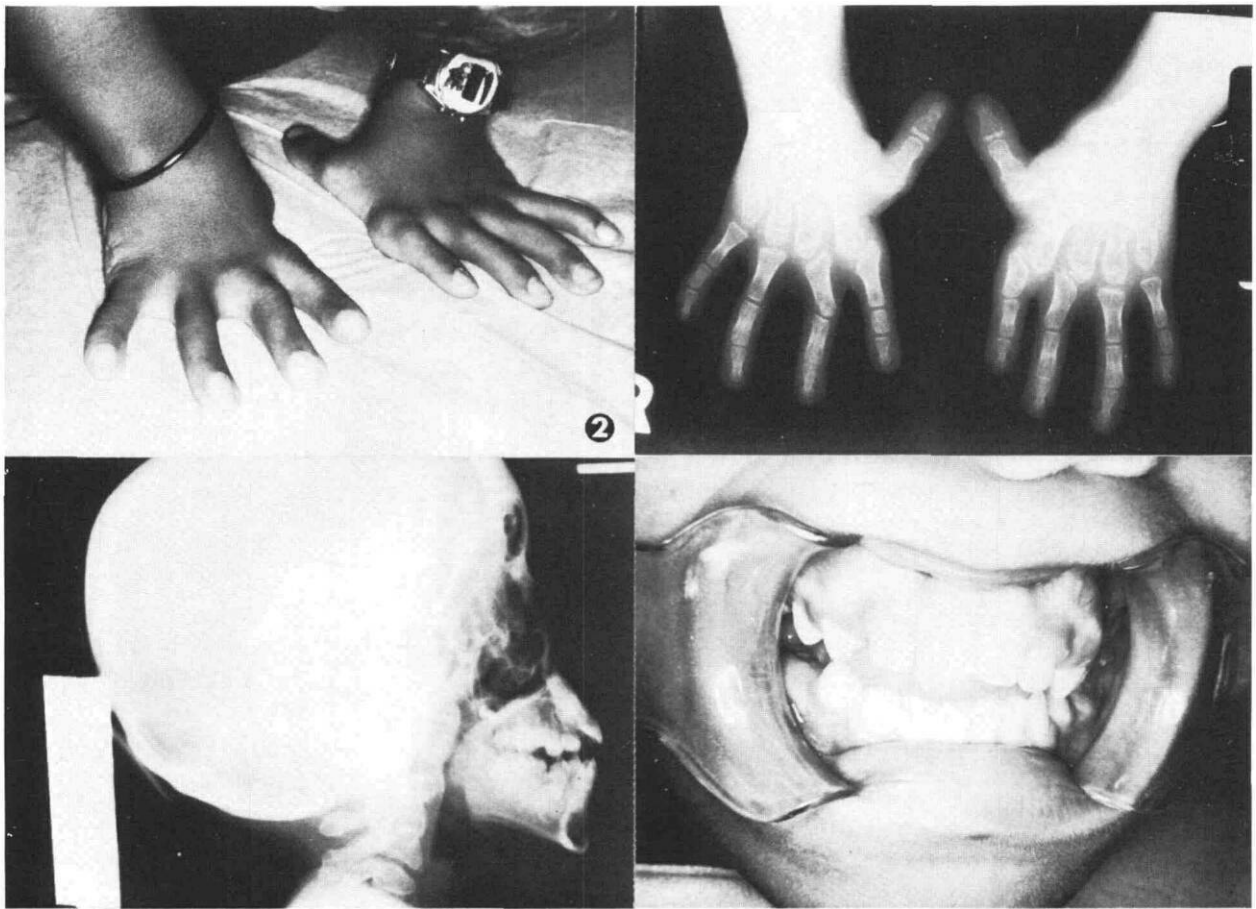


FIG 2 & 3. (top left and right) Deformities of hands which include hitchhiker thumbs and sinfalangism. FIG 4. (lower left) Cephalogram of the patient. FIG 5. Anterior open bite in the patient.

Examination of the teeth revealed caries on the mesial surfaces of No. 8, 23, 24 and 25. Unrestorable caries occurred on Tooth 14 with periapical pathology. Oral hygiene was poor although there was no calculus accumulation. Angle's classification of malocclusion could not be made because Tooth 30 previously had been extracted and because of extensive carious lesions on Tooth 14. The maxillary canines were unerupted.

The Pediatric Department made the following recommendations: (1) repair of cleft palate, (2) evaluation of pulmonary function prior to surgery, (3) use of special wheelchair as recommended by Physical Medicine, (4) social work follow up.

The author repaired the carious teeth, extracted Tooth 14, and instructed the patient and his parents in oral physiotherapy and oral hygiene. Prophylaxis and fluoride treatments also were completed. The patient is being monitored and his oral health status is checked routinely. If problems are found he will be referred to other services as needed.

This patient has a brother with a variant form of

diastrophic dysplasia and, while he has less severe problems of the feet, hands, and trunk, it appears as though this sibling carries the same diagnosis.

## Discussion and Conclusion

It is of some interest that this patient presents calcification in only one of the ear cartilages, although this is not an abnormal finding. Patients with deformities such as scoliosis often require special consideration when being treated in a dental chair. The following recommendations are made concerning the clinical management of the patient with diastrophic dysplasia: (1) use behavior management techniques in direct relationship to IQ (as with any compromised patient); (2) evaluate the emotional and psychological health of the patient; (3) use family and medical histories which may be helpful in establishing priorities for patient treatment; (4) obtain a complete dental history, (5) evaluate cleft palate, if present, and arrange for either surgical or prosthetic treatment; (6) evaluate the severity of the condition of the patient;

(7) consider referral to other departments which could facilitate rehabilitation, (8) evaluate parental attitude toward the condition of the patient and inform them of oral health management problems and how the pediatric dentist can help; and (9) use equipment and instrumentation properly to avoid upsetting and harming the patient.<sup>a</sup>

Although diastrophic dysplasia is not a common heritable disorder, the occurrence of more than 140 cases in the literature suggests it is common enough that pediatric dentists — particularly at a major medical center — should know the characteristics of this condition and establish effective management guides.

<sup>a</sup> This includes the following specific recommendations: (a) establish the most comfortable position in the chair and demonstrate its security, (b) use compressed air and water sprays with special care in patients with cleft palates, (c) avoid excessive impression material when constructing dental casts, (d) encourage patient participation, (e) attempt to perform operative procedures as with a physically normal patient, (f) take special care in taking intraoral radiographs in cleft palate patients, and (g) avoid prolonged positioning in the dental chair to avoid respiratory embarrassment, a possible complication of kyphoscoliosis.

Dr. Ruiz is in private pediatric dental practice in Bayamón, Puerto Rico. Reprint requests should be sent to him at Ave. Comerio ZA-20, Urb. Riverview, Bayamón, Puerto Rico 00619.

1. Maroteaux P: The chondrodystrophies detectable at birth. International Conference on Congenital Malformations. New York; Excerpta Medica Foundation, 1970.
2. Vazquez AM, Lee FA: Diastrophic dwarfism. *J Pediatr* 72:234-42, 1968.
3. Bethem D, Winter RB, Lutter L, Moe JH, Bradford DS, Lonstein JE, Langer LO: Spinal disorders of dwarfism. *J Bone Joint Surg* 63-A:1412-25, 1981.
4. Kash IJ, Sane SM, Samaha FJ, Briner J: Cervical cord compression in diastrophic dwarfism. *J Pediatr* 84:862-64, 1974.
5. Paul SS, Rao PL, Mullick P, Saigal S: Diastrophic dwarfism, a little known disease entity. *Clin Pediatr* 4:95-101, 1965.
6. McKusick VA: Heritable Disorders of Connective Tissue, 4th ed. St. Louis; CV Mosby Co, 1972.
7. Taybi H: Diastrophic dwarfism. *Radiology* 80:1-10, 1963.
8. Herr N, Goulian D: Review of diastrophic dwarfism associated with cleft palate - presentation of a case. *Cleft Palate J* 11:229-34, 1974.
9. Mantagos S, Weiss RR, Mahoney M, Hobbins JC: Prenatal diagnosis of diastrophic dwarfism. *Am J Obstet Gynecol* 139:111-13, 1981.
10. O'Brien GD, Rodeck C, Queenan JT: Early prenatal diagnosis of diastrophic dwarfism by ultrasound. *Br Med J* 280:1300, 1980.

### Quotable Quote: teacher burnout

When children go to school each day, there is a good chance they face a teacher who wants to leave the profession, according to Richard Schwab of the University of New Hampshire who has studied teacher "burnout" for 6 years. Thirty per cent of teachers in one of his studies did want to leave teaching. He says a desire to leave the profession — even in those who started out bright-eyed and dedicated — is one consequence of burnout.

According to Schwab, teacher burnout is characterized by 3 factors: emotional exhaustion and fatigue; negative, cynical attitudes toward students; and the loss of feelings of accomplishment on the job. Some maintain burnout is the psychological problem of individuals, but Schwab says too many teachers are affected for that to be true. In fact, he notes, a study of 339 New Hampshire teachers links burnout to particular organizational problems.

Teacher Burnout. *USA Today* 113:8-9.  
April, 1985.