

Incidental finding of odontogenic fibroma: case report

Alan M. Schwimmer, DDS
Jeffery M. Ginsberg, DMD
Charles E. Barr, DDS

The odontogenic fibroma is a rare, benign tumor of mesodermal origin, and one of the most ill-defined and least understood of all odontogenic neoplasms.¹ It presently is thought to originate from either dental follicle, periodontal ligament, or dental papilla.² Bhaskar reported the lesion as being the most common odontogenic tumor comprising approximately 23% of all odontogenic lesions.³ This opinion is based on his identification of the enlarged dental follicle as an odontogenic fibroma, and belief that the distinction between the neoplasm and the hyperplastic dental follicle is often arbitrary.⁴ Other reviewers have reported the incidence as being between 3 and 7% of all odontogenic tumors.⁵

The lesion occurs most commonly in the mandible although several cases have been reported in the maxilla.^{4,6} The tumor has no sex predilection, and has been reported in patients ranging in age from 11 to 80 years with a mean age of 34 and median age of 23.⁴ The lesion grows slowly, is not associated with pain or dysesthesia, and may be present for several years before becoming symptomatic. It usually appears on radiographs as a single well-defined radiolucency, or as a multilocular lesion when associated with a larger tumor.

Considerable controversy surrounds the classification of the odontogenic fibroma. Wesley² and Gardner⁷ have attempted to clarify the nature of the lesion. Wesley has separated it as an entity distinct from the odontogenic myxoma, hyperplastic dental follicle, and other fibroosseous lesions. He associated the following characteristics with the lesion. It is central, slow-growing, and occurs primarily in the mandible. It is frequently multilocular and associated with unerupted or displaced teeth. Histologically the lesion consists of a relatively dense collagenous stroma with a uniform distribution of fibroblasts. Multiple nests of odontogenic epithelium are a variable finding. Most pathologists believe that the absence of odontogenic epithelium does not preclude a diagnosis of odontogenic fibroma.^{2,3,7} Gardner⁷ attempted to clarify its classification by placing the lesion into three separate but related groups: the hyperplastic

dental follicle, the simple odontogenic fibroma and the central odontogenic fibroma (WHO type).

The hyperplastic dental follicle is composed of fibrous connective tissue with scattered nests of odontogenic epithelium. These epithelial nests are seldom numerous and are localized. In cases when nests of odontogenic epithelium are present, they are smaller than the islands found in ameloblastomas or ameloblastic fibromas. Stellate reticulum is not present, and the epithelial cells are not polarized. This histologic pattern is consistent with inactive odontogenic epithelium and helps to distinguish the odontogenic fibroma from an ameloblastic fibroma. The central odontogenic fibroma (WHO type) is more complex than the simple odontogenic fibroma. According to Gardner, the lesion consists of cellular but mature fibrous connective tissue in which strands of odontogenic epithelium are found. Calcified tissue either in the form of dysplastic dentin, or cementum-like material also is found in the lesion.⁷

Case Report

An eight-year-old male was referred to the department of dentistry for evaluation of pain in the right mandible following a bicycle accident. On physical examination the patient was found to have a moderate amount of trismus with tenderness to palpation over the left condyle and slight deviation to the left on opening. There was no change in occlusion, no mobility of segments, and no crepitus. Radiographic examination showed a green stick fracture of the right medial cortex of the mandible (Figure 1).

An additional finding was a 1 × 2 cm radiolucent lesion in the left mandible associated with the mandibular left second premolar (Figure 2). No pain, dysesthesia, or expansion of the medial or lateral cortices was associated with the lesion. Since the mandibular fracture was nondisplaced, conservative therapy consisting of observation, and soft diet without the use of fixation was advised. One month after the accident an incisional biopsy of the lesion was performed (Figure 3).

Figure 1. (left) Occlusal radiograph of mandible showing green stick fracture of right medial cortex.

Figure 2. (right) Radiograph of mandible showing 1 × 2 cm radiolucent lesion associated with mandibular left second bicuspid.

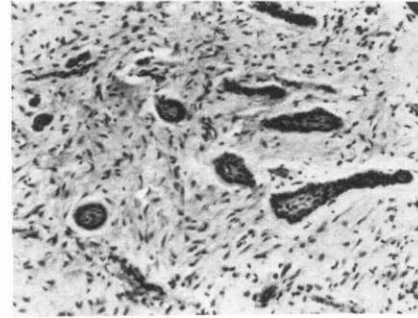
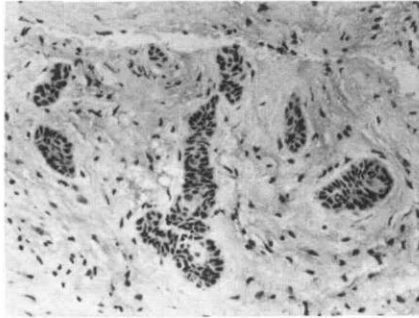
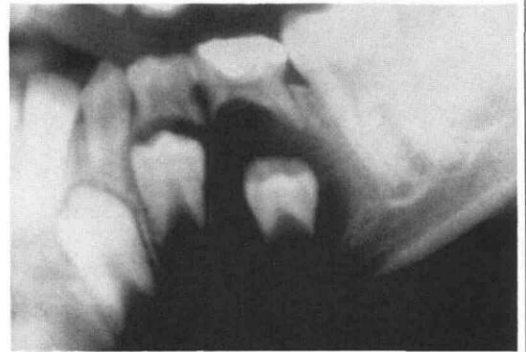
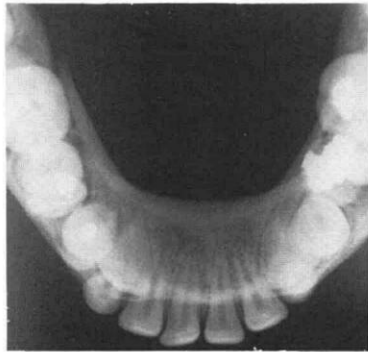


Figure 3. (left) Incisional biopsy showing islands of odontogenic epithelium in a fibromyxomatous stroma.

Figure 4. (right) Surgical specimen of odontogenic fibroma lesion showing multiple foci of nests and strands of odontogenic epithelium in a fibrous stroma.

The specimen consisted of a fibromyxomatous connective tissue stroma containing elongated and stellate-shaped fibroblasts. Islands of odontogenic epithelium were observed, suggestive of a diagnosis of odontogenic fibroma.

Definitive surgery consisted of complete enucleation and curettage of the lesion and extraction of the associated tooth. The surgical specimen consisted of a moderately dense, fibrous connective tissue stroma with mature spindle-shaped fibroblasts. Multiple foci of spherical nests and strands of odontogenic epithelium one to two cells thick were present. The epithelial nests were surrounded by a ground substance-like halo. The histological pattern was consistent with a diagnosis of odontogenic fibroma (Figure 4).

Discussion

Odontogenic fibroma is a rarely reported lesion of mesodermal origin. Current opinion regards the tumor as a distinct entity with clinical and histological patterns that separate it from the ameloblastic fibroma, odontogenic myxoma, and hyperplastic dental follicle. This lesion was asymptomatic and an incidental finding in an eight-year-old child, who was being evaluated for trauma to the mandible. The clinical and histologic patterns of the lesion are both consistent with a diagnosis of a simple odontogenic fibroma.⁷

Since the odontogenic fibroma is benign, rarely recurring, with no tendency to undergo malignant transformation, the recommended treatment is enucleation and curettage of the lesion with removal of the associated unerupted tooth.² Only one case of recurrence has been reported.³

Dr. Schwimmer is coordinator of oral surgery, Oral & Maxillofacial Surgery; Dr. Ginsberg is resident, Pediatric Dentistry; and Dr. Barr is director of Dentistry & Attending, Dentistry/Pathology, Beth Israel Medical Center, 10 Nathan Perlman Place, New York, N.Y. 10003. Requests for reprints should be sent to Dr. Schwimmer.

1. Hammer, J.E., Gamble, J.W., Gallegos, G.J. Odontogenic fibroma: report of two cases. *Oral Surg* 21:113, 1966.
2. Wesley, R.K., Wysocki, G.P., Mintz, S.M. The central odontogenic fibroma—clinical and morphological studies. *Oral Surg* 40:235, 1975.
3. Bhaskar, S.N. Synopsis of Oral Pathology, 5th ed. St. Louis: C.V. Mosby Co., 1977, pp 259-61.
4. Dahl, E.C., Wolfson, S.H., Haugen, J.C. Central odontogenic fibroma: a review of literature and report of a case. *J Oral Surg* 39:120, 1981.
5. LeDoussal, V., Mahe, E., Herbert, H. Los fibromyxomes odontogenes. *Arch Anat Cytol Path* 23:325-31, 1981.
6. Knight, W.O., Caulfield, J.J. Abbreviated case report—odontogenic fibroma. *Oral Surg* 34:381, 1972.
7. Gardner, D.G. The central odontogenic fibroma: an attempt at clarification. *Oral Surg* 50:425, 1980.