

## Dental defects in the deciduous dentition of premature infants with low birth weight and neonatal rickets

W. Kim Seow, BDS, FRACDS John P. Brown, BDS, MSc, PhD, FRACDS  
David A. Tudehope, MB, BS, FRACP Michael O'Callaghan, MB, BS,  
FRACP

### Abstract

*Etiological factors in developmental defects in the deciduous dentition are poorly understood. One method of studying these defects is to examine children who have had a definitive diagnosis of neonatal rickets—known to cause a major disturbance in calcium metabolism. Fifteen children with this history were recalled and everyone had defects in the deciduous dentition. Seven children had combined opacities and hypoplasia, three had only opacities, and five had hypoplasia alone. These findings suggest that disturbances in calcium metabolism in the neonatal period may have a central role in the pathogenesis of developmental defects in the deciduous dentition.*

**R**ickets is a condition in infants and children characterized by disturbances in the mineralization of osseous and dental tissue. In general, four etiologic classifications can be recognized.<sup>1,2</sup> Classification of the pathogenesis of rickets is presented in Table 1. The other major causes include transport defects of intestinal and renal epithelium, metabolic disorders, and matrix defects. However, the rickets seen in premature infants (neonatal rickets) appears to be multifactorial in origin, and not completely understood.<sup>3-7</sup> As the major percentage of the newborn's stores of calcium and phosphate are accumulated in the last trimester of pregnancy, an extremely low birth-weight infant (<1,500 grams) born prior to this would have missed these accumulations. Liver and renal immaturity results in defective conversion of vitamin D to its active metabolites. Furthermore, it is difficult to supply and ensure absorption of calcium, phosphate, and vitamin D to premature infants.

Systemic or local disturbances occurring at the time of dental development can result in defects of the

dentition, manifesting either as enamel hypoplasia or hypocalcification. The Federation Dentaire Internationale\* has defined enamel hypoplasia as "a qualitative defect of enamel visually and morpho-

TABLE 1. Etiologic Classification of Rickets\*

Dietary	<ol style="list-style-type: none"><li>1. Vitamin D deprivation</li><li>2. Calcium deprivation, e.g., general malnutrition, milk-free diets, prematurity, etc.</li><li>3. Phosphate deprivation, e.g., abuse of magnesium-aluminum hydroxides as antacids, prematurity, etc.</li></ol>
Transport	<ol style="list-style-type: none"><li>1. Malabsorption<ol style="list-style-type: none"><li>(a) ↓ Vitamin D absorption, e.g., bile salts depletion</li><li>(b) ↓ Calcium and vitamin D absorption, e.g., sprue, coeliac disease</li></ol></li><li>2. X-linked hypophosphatemia</li><li>3. Fanconi's syndrome</li></ol>
Metabolic	<ol style="list-style-type: none"><li>1. Hepatocellular diseases with defective synthesis of 25 hydroxy-vitamin D</li><li>2. Long-term anticonvulsant use</li><li>3. Renal cortical diseases with defective synthesis of 1,25 dihydroxy-vitamin D</li><li>4. Autosomal recessive vitamin D-dependent rickets</li><li>5. Prematurity</li></ol>
Matrix Defect	<ol style="list-style-type: none"><li>1. Hypophosphatasia</li><li>2. Metaphyseal dysostosis</li></ol>

\* The etiology of rickets of prematurity (neonatal rickets) appears to be multifactorial, involving deficient body stores, dietary factors, and metabolic factors.<sup>1-4</sup>

logically identified as involving the surface of the enamel (an external defect) and associated with a reduced thickness of enamel." The descriptive term opacity also can be used in place of the term hypocalcification and is defined as a qualitative defect of enamel identified visually as an abnormality in the translucency of enamel. Enamel hypoplasia results from factors interfering with normal matrix formation, while enamel hypocalcification results from factors interfering with the process of calcification.<sup>9</sup> Thus, the occurrence of neonatal rickets when many primary teeth are undergoing calcification will result in dental defects.

Although the adverse effects of other types of rickets on the dentition have been well documented,<sup>10-13</sup> no dental studies to date have been carried out on children who developed rickets in the neonatal period. This study investigated the dental defects found in a group of extremely low birth-weight premature infants with a diagnosis of neonatal rickets.

## Patients and Methods

In 1978 the Growth and Development Clinic was established at Mater Children's Hospital in South Brisbane, Queensland, to provide a multidisciplinary, longitudinal follow-up of all surviving infants of low birth weight.<sup>5,14-16</sup> Letters were sent to parents of 18 children, aged two years and older, who had a definite clinical and radiological diagnosis of rickets in the neonatal period, inviting them to join the study. Most of these patients previously have been reported in the medical literature.<sup>5,15</sup> Altogether, 15 patients consented to the study, while 3 did not comply.

All 15 patients, 11 females and 4 males, were born prematurely, with a mean birth weight of 852 grams (range 609-1,028 grams). The mean gestational age was 27.5 weeks (range 24-32 weeks). The mean age of the children at examination was 3 years, 7 months (range 2 years, 2 months-4 years, 3 months). The patients included a pair of discordant twins and 2 survivors of a triplet birth. All patients were diagnosed by accepted clinical and radiological criteria as having rickets in the neonatal period. All received treatment with dihydrotachysterol, and vitamin D and calcium supplement.<sup>5,15</sup>

In this series of low birth-weight infants, the clinical features which led to the diagnosis of neonatal rickets included spontaneous rib fractures and/or craniotables. Biochemical studies were of little value because serum calcium and phosphate levels tended to be within normal ranges. The diagnosis of neonatal rickets was established by radiological criteria. These included metaphyseal disturbances, periosteal reaction, and general loss of bone density. The loss of bone density was determined by measurements of the humeral cortex as described by Poznanski et al.<sup>17</sup>

Other medical causes of these radiological changes such as osteogenesis imperfecta, hypophosphatasia, Menke's syndrome, congenital syphilis, and congenital rubella, etc., were excluded by appropriate laboratory tests, serial radiographs, and clinical progress.<sup>5,15</sup>

The dental examinations were done under ideal conditions at the University of Queensland Dental School. The teeth were dried and a mirror and probe were used for the detection of caries, enamel hypoplasia, and opacities. The diagnosis of enamel hypoplasia and opacity was made using FDI criteria.<sup>8</sup> In brief, the diagnosis of opacity was restricted to white or brown opaque spots on teeth that did not have surface breaks or pits on the enamel. If there was a break in surface contours such as pits, grooves, or absence of enamel over areas of dentine, then the diagnosis of enamel hypoplasia was made. If a tooth showed both enamel hypoplasia and opacity, it was categorized as enamel hypoplasia. Each tooth was examined and the severity and extent of each dental defect recorded in a comprehensive chart. Abnormalities of soft tissues also were noted. Bite-wing radiographs were taken of four children to assist caries diagnosis. Intraoral photographs were taken in some children. Postnatal medical and dental histories were obtained from the patients. Maternal and neonatal medical histories were obtained from hospital records.

## Results

The relevant clinical details of this series of 15 children with neonatal rickets are summarized in Table 2.

### Case Histories

The onset of rickets occurred during the neonatal period in all patients in this study. Typical radiological changes were apparent within 14-30 days. The duration of the radiological findings varied between 60 and 140 days. There was no correlation between the duration of rickets and the severity of dental defects.

A maternal history of pre-eclampsia was recorded in Patient 1 but maternal histories of the other 14 children were insignificant. Medical histories since hospital dismissal were insignificant except for Patient 2 who developed measles at about 14 months. No clear histories of oral trauma were recorded in this series. None of the children had visited a dentist except for Patient 4 who had a dental examination only. The mother of the twins (Patients 5 and 6) was the only mother who ingested fluoride tablets (2.2 mg per day) during pregnancy. Only three children (Patients 5, 6 and 15) ingested fluoride tablets and all three began after age one year. None of the subjects drank fluoridated water.

**TABLE 2. Summary of Clinical and Dental Information of 15 Children with Neonatal Rickets**

Patient No	Gestational Age (weeks)	Birth Weight (gms)	Age at Exam	Sex	Dental Defects		Other Serious Illnesses in the Newborn Period
					Opacities	Hypoplasia	
1	29	1,020	2yrs 9mo	F	—   — DE	B   B	Moderate RDS, PDA Cholestatic jaundice, gastrointestinal intolerance
2	26	850	2yrs 10mo	F	D   D	—   —	Moderate RDS, PDA
3	27	820	3yrs 2mo	F	BA   A DC	—   BC	Severe RDS
4	31	961	4yrs 3mo	M	E   — DE	C   AB E	Severe RDS
5	26	897	3yrs 7mo	M	—   — B   B	—   A C   C	Apnea of prematurity
6	26	605	3yrs 7mo	M	B   B A   A	—   A C   C	Apnea of prematurity
7	26	866	2yrs 4mo	M	—   — C	—   —	Severe RDS, nonspecific chronic lung disease
8	24	609	2yrs 2mo	F	—   —	—   A	Bronchopulmonary dysplasia, gastrointestinal intolerance
9	30	913	2yrs 6mo	F	—   B D   C	A   C	Nonspecific chronic lung disease, PDA, cholestatic jaundice
10	26	750	3yrs 9mo	F	—   —	—   B	Moderate RDS, PDA, esophageal stenosis
11	26	730	3yrs 9mo	F	—   —	C   C	Moderate RDS, PDA
12	32	1,028	3yrs 1mo	F	—   —	—   A	Nonspecific chronic lung disease
13	26	880	3yrs 9mo	F	E   — E	—   —	Moderate RDS, PDA
14	32	1,015	3yrs 6mo	F	—   — D	—   AB	NEC, prolonged hyperbilirubinemia
15	26	840	3yrs 4mo	F	—   —	C   AB	Apnea of prematurity

Abbreviations: PDA - patent ductus arteriosus; RDS - respiratory distress syndrome; NEC - necrotising enterocolitis.

### Clinical Findings

Marginal gingivitis was noted in most children, but otherwise no soft tissue abnormalities were present.

Every child in this series had a complete deciduous dentition at the time of examination except for three children (Patients 2, 7, and 9) whose second primary molars still were unerupted.

All 15 children showed dental defects of the primary dentition. Three children (20%) had only dental opacities. In 7 other children, the opacities and hypoplasia were present in different teeth. These opacities, which consisted of white or yellow brown patches, were located mainly on the buccal and occlusal surfaces.

Of greater interest is the observation that 12 chil-

dren (80%) showed hypoplasia of at least one tooth. The dental defects of Patients 3 and 4 are shown in Figures 1 and 2, respectively, and are representative of the more severely affected cases.

Table 3 shows the distribution of dental hypoplasia and opacities. The teeth most commonly showing hypoplasia were the maxillary primary central and lateral incisors followed by the maxillary and mandibular canines. On the other hand, the mandibular first primary molar and canine were the teeth most commonly showing opacities followed by the mandibular second primary molar.

Depending on location, the hypoplastic defects fell into two main groups. In the first group, the incisal edges appeared fairly intact and the hypoplastic de-

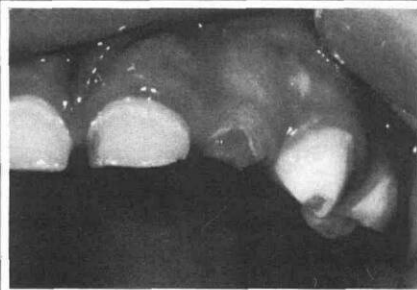


FIGURE 1. (left) The hypoplastic maxillary left lateral primary incisor and canine. Note opacity on the surface of the canine cervical to the hypoplastic area (Patient 3).

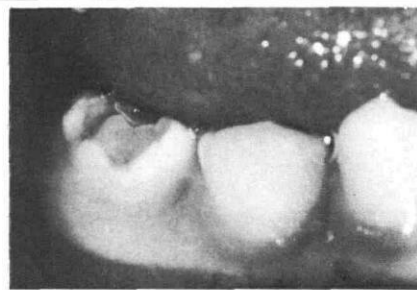

FIGURE 2. (right) Mandibular right second primary molar severely affected by hypoplasia (Patient 4).

TABLE 3. Distribution of Dental Hypoplasia and Opacities in the Primary Dentition of Children with Neonatal Rickets

	Teeth Affected*				
	A	B	C	D	E
Maxilla	8(2)	7(4)	4(0)	0(2)	0(2)
Mandible	0(2)	0(2)	4(6)	0(6)	1(4)
Total	8(4)	7(6)	8(6)	0(8)	1(6)

\* Opacities in parentheses.

fect appeared as a broad shallow pit or band in the labial surface of the crown. Ten teeth in six of these children showed this defect.

In the second group, the hypoplastic defect extended from the incisal edge onto the incisal third or half of the facial surface. This defect was found in 14 teeth of 10 children.

Apart from dental defects, additional clinical findings in these children showed that the prevalence of caries was low. The only carious lesions detected were in the occlusal pits of the first primary molars in Patient 3.

No discolorations or opacities suggestive of staining by tetracycline, bile pigments, or fluoride were seen.

### Radiographic Findings

Examination of bite-wing radiographs of Patients 4, 10, 11, and 12 did not reveal any abnormalities of the teeth. The sizes of the pulp chambers were within normal limits and no extensions of the pulp to the occlusal surfaces were noted. The radiographs of Patients 10 and 12 are shown in Figures 3 and 4, respectively.

### Discussion

According to Lunt and Law,<sup>18</sup> calcification of the primary dentition begins with the maxillary central incisors at 14 weeks in utero, but enamel formation of all primary dentition remains incomplete at birth, even for the full term newborn. Hence, in the premature infant the amount of enamel deposited will be much less. Since rickets represents a severe disturbance of calcium metabolism, it is reasonable to expect that premature infants with rickets may have developmental defects in their deciduous teeth. The

results of the present study confirm this expectation; all 15 children had dental developmental defects either in the form of opacities or hypoplasia of the crown.

Prematurity without rickets has been reported to be associated with an increased prevalence of developmental dental defects in the range of 21-27% compared to around 2% in full term infants.<sup>19-22</sup> These values are well below the 100% prevalence in this series of premature infants with neonatal rickets, suggesting that rickets is one of the possible etiological factors. If systemic influences such as prematurity and rickets are wholly responsible, then the defects would be symmetrical, yet they are not. Possible explanations for this discrepancy include modifying influence of local factors, and variation in tissue response of the developing teeth. On the other hand, the distribution of the defects may be symmetrical, but because of the inability of current techniques to detect minor defects, only obvious defects were noted.

The authors are unaware of any previous studies having been done on the prevalence of developmental dental defects in neonatal rickets. This is in part due to the high mortality of very low birth-weight infants in the past. However, recent improvements in neonatal intensive care have increased survival rates of these infants so that more cases of neonatal rickets are available for study. Other types of rickets have

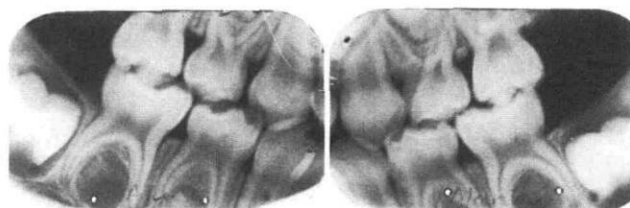


FIGURE 3. Bite-wing radiographs of Patient 10 showing normal appearance of pulp chambers and thicknesses of enamel and dentine.

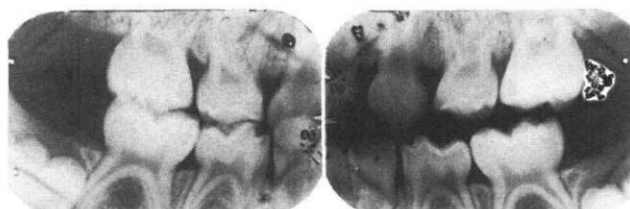


FIGURE 4. Bite-wing radiographs of Patient 12 also showing normal appearance.

been associated with dental abnormalities,<sup>10-13</sup> so it is not surprising that this is also the case with neonatal rickets. Since neonatal rickets almost always is associated with prematurity and low birth weight, these factors cannot be analyzed as causative factors separately from neonatal rickets; consequently, a direct causal effect between neonatal rickets and defects in the deciduous dentition cannot be made.

A further indication of the important role of calcium metabolism in the pathogenesis of developmental dental defects is clinical observations that full term neonates with hypocalcemic tetany can develop dental hypoplasia.<sup>23,24</sup> Also, conditions such as neonatal asphyxia and maternal diabetes are associated with an increased prevalence of neonatal hypocalcemia and enamel hypoplasia.<sup>25,26</sup>

## Conclusions

The results of this study show that children born prematurely with low birth weight and neonatal rickets have 100% prevalence of defects in the primary dentition. These results, together with supportive evidence of dental abnormalities seen in other forms of rickets and other clinical observations, indicate that deranged calcium metabolism has a possible role in pathogenesis. However, the confounding factors of prematurity and its associated complications cannot be ruled out because neonatal rickets is seldom, if ever, seen in infants without these conditions.

The authors thank C. Souvlis and G. Staples who, while dental students, conducted a pilot survey of primary dentition in premature infants. Also assisting in this study were: H. Mohay, Y. Burns, J. Boardman, M. Neil, and other members of the Growth and Development Clinic, Mater Children's Hospital.

Dr. Seow is a lecturer and Dr. Brown is a senior lecturer in dentistry for children, University of Queensland; Dr. Tudehope is director of neonatology, Mater Mothers' Hospital, South Brisbane, Queensland; and Dr. O'Callaghan is a developmental pediatrician, Mater Children's Hospital, South Brisbane, Queensland. Reprint request should be sent to Dr. Seow, Department of Social and Preventive Dentistry, University of Queensland Dental School, Turbot St., Brisbane, Queensland 4000, Australia.

1. Fraser, D., Scriver, C.R. Familial forms of vitamin D-resistant rickets revisited: X-linked hypophosphatemia and autosomal recessive vitamin D dependency. *Am J Clin Nutr* 29:1315-29, 1976.
2. Cohn, R.M., Roth, K.S. *Metabolic Disease: A Guide to Early Recognition*. Philadelphia; W.B. Saunders Co., 1983, pp 265-69.
3. Tsang, R.C., Steichen, J.J. Perinatal calcium homeostasis: neonatal hypocalcemia and bone demineralization. *Clin Perinatol* 4:385-409, 1977.
4. Hillman, L.S., Haddad, J.G. Perinatal vitamin D metabolism. *J Pediatr* 86:928-35, 1975.
5. Seino, Y., Ishii, T., Shimotsuji, T., Ishida, M., Yabuuchi, H. Plasma active vitamin D concentration in low birth-weight infants with rickets and [their] responses to vitamin D treatment. *Arch Dis Child* 56:628-32, 1981.
6. Greer, F.R., Steichen, J.J., Tsang, R.C. Calcium and phos-

- phate supplements in breast milk-related rickets. *Am J Dis Child* 136:581-83, 1982.
7. Cleghorn, G.J., Tudehope, D.I., Masel, J.P. Rickets in extremely low birth-weight infants. *Aust Paediatr J* 17:285-89, 1981.
8. Commission on Oral Health, Research and Epidemiology: An epidemiological index of dental enamel (DDE Index). *Int Dent J* 32:159-67, 1982.
9. McDonald, R.E., Avery, D.R. *Dentistry for the Child and Adolescent*, 3rd ed. St. Louis; C.V. Mosby Co., 1978, pp 45-69.
10. Eliot, M.M., Souther, S.O., Anderson, B.G., Arnim, S.S. A study of the teeth of a group of school children previously examined for rickets. *Am J Dis Child* 48:713-29, 1934.
11. Grahnen, H., Selander, P. The effects of rickets and spasmophilia on the permanent dentition. 1. The effect on the teeth. *Odont Revy* 5:7-26, 1954.
12. Scriver, C.R. Rickets and the pathogenesis of impaired tubular transport of phosphate and other solutes. *Am J Med* 57:43-49, 1974.
13. Witkop, C.J. Hereditary defects of dentin. *Dent Clin North Am* 19:25-45, 1975.
14. Tudehope, D.I., Burns, Y.R., O'Callaghan, M., Mohay, H. Minor neurological abnormalities during the first year of life in infants of birth weight less than 1,500 g. *Aust Paediatr J* 17:265-68, 1981.
15. Masel, J.P., Tudehope, D.I., Cartwright, D., Cleghorn, G. Osteopenia and rickets in the extremely low birth-weight infant—a survey of the incidence and a radiological classification. *Aust Radiol* 26:83-96, 1982.
16. Tudehope, D.I., Burns, Y.R., O'Callaghan, M., Mohay, H., Silcock, A. The relationship between intrauterine and postnatal growth on the subsequent psychomotor development of very low birth-weight infants. *Aust Paediatr J* 19:3-8, 1983.
17. Poznanski, A.K., Kuhns, L.R., Guire, K.E. New standards of cortical mass in the humerus of neonates: a means of evaluating bone loss in the premature infant. *Radiology* 134:639-44, 1980.
18. Lunt, R.C., Law, D.B. A review of the chronology of calcification of deciduous teeth. *JADA* 89:599-606, 1974.
19. Stein, G. Enamel damage of systemic origin in premature birth and diseases of early infancy. *Am J Orthod* 33:831-41, 1947.
20. Grahnen, H., Larsson, P.G. Enamel defects in the deciduous dentition of prematurely born children. *Odont Revy* 9:193-204, 1958.
21. Rosenzweig, K.A., Sahar, M. Enamel hypoplasia and dental caries in the primary dentition of prematurity. *Br Dent J* 113:279-80, 1962.
22. Funakoshi, Y., Kushida, Y., Hieda, T. Dental observations of low birth-weight infants. *Pediatr Dent* 3:21-25, 1981.
23. Stimmler, L., Snodgrass, G.J., Jaffe, E. Dental defects associated with neonatal symptomatic hypocalcaemia. *Arch Dis Child* 48:217-20, 1973.
24. Purvis, R.J., Barrie, W.J., Mackay, G.S., Cockburn, F., et al. Enamel hypoplasia of the teeth associated with neonatal tetany: a manifestation of maternal vitamin D deficiency. *Lancet* 2:811-14, 1973.
25. Miller, J., Forrester, R.M. Neonatal enamel hypoplasia associated with haemolytic disease and prematurity. *Br Dent J* 106:93-104, 1959.
26. Grahnen, H., Edlund, K. Maternal diabetes and changes in the hard tissues of primary teeth. I. A clinical study. *Odont Revy* 18:157-62, 1967.
27. Grahnen, H., Sjolín, S., Arwill, T., Magnusson, B.D. Neonatal asphyxia and mineralization defects of the primary teeth. *Caries Res* 3:301-7, 1969.