

Micromorphologic features of dentin in vitamin D-resistant rickets: correlation with clinical grading of severity

W. Kim Seow, BDS, MDS, PhD, FRACDS K. Romaniuk, BDS, MDS, Dr Med Dent, PhD, FRACDS
S. Sclavos, BDS

Abstract

This study was a histological analysis of 20 primary teeth from 5 patients with 3 clinical grades of vitamin D-resistant rickets (VDRR). The results showed that the degree of globular dentin formation in the histological sections may be graded into Grades I-III in increasing order of severity. In Grade I, the amount of globular dentin was less than 50% of the total dentin thickness, and the interglobular spaces were small. By contrast, in Grade III severity, globular dentin extended throughout the entire thickness of dentin, and the interglobular spaces were large. In Grade II severity, the amount of globular dentin was more than half but did not involve the entire dentin thickness. These histologic grades of severity correlated directly with the clinical grades of the patients. In addition, the study found that lack of medical treatment in affected mothers might lead to globular dentin formation in the fetus in-utero. Conversely, adequate phosphate supplementation in a hypophosphatemic mother might prevent the formation of globular dentin in the fetus.

Introduction

VDRR, also known as familial hypophosphatemia, is the most common form of rickets in developed countries today (Fraser and Scriver 1976). The disease, which is inherited in an X-linked dominant manner, results from a selective disorder of transepithelial transport of phosphate, leading to decreased tubular reabsorption of phosphate and persistent hypophosphatemia (Harrison and Harrison 1964).

VDRR is of special significance to pediatric dentists because of the characteristic multiple "spontaneous" dental abscesses which are often associated with the disease (Harris and Sullivan 1960; Seow 1984(b); Herbert 1986). In fact, many patients with VDRR first were diagnosed by dentists from these dental features, as the general signs and symptoms of rickets usually are not obvious until the patients are more than 18 months of age. The dental abscesses are due to defective dental mineralization which predisposes to early pulp

exposures from minimal caries or attrition.

In VDRR the abnormal dental mineralization is characteristically observed in dentin where large amounts of poorly mineralized globular dentin and tubular defects extending close to the dentinoenamel junction are observed (Soni and Marks 1967; Sauk and Witkop 1973). Enamel hypoplasia occurring concurrently with these defects also has been reported (Marks et al. 1965; Soni and Marks 1967; Tulloch and Andrews 1983; Seow and Latham 1986).

In a previous study of 13 patients affected by VDRR, Seow and Latham (1986) reported that the dental findings occurred in a spectrum of manifestations ranging from minimal to severe. Based on the history of dental abscesses and the radiographic appearances of the teeth, 3 grades of oral manifestations were proposed by the authors, viz Grade I: minimal or no dental manifestations; Grade II: moderate pulp enlargement with a few teeth abscessed; Grade III: extremely large pulp chambers and multiple dental abscesses.

In the present study, we examined teeth from patients with different clinical grades of VDRR to determine if these clinical grades could be correlated with histological findings. In addition, these microscopic findings were analyzed in relation to genetic data and medical treatment to gain further insight into the pathogenesis of the dental defects in VDRR.

Patients and Methods

Patients

Naturally exfoliated and extracted primary teeth were collected from 5 patients with an established diagnosis of VDRR. These patients formed part of the study population reported in a previous investigation (Seow and Latham 1986). Teeth were not available from the remaining patients in the previous study. Details of

medical histories and treatment were obtained from hospital charts. There were 2 females and 3 males, and their ages at the time of study ranged from 7 to 15 years. The ages of diagnosis and the start of medical treatment in these children varied from 9 months to 4.5 years of age. At the time of study, all patients were placed on phosphate replacement therapy and calcitriol. Medical and family histories also were obtained from the patients, as well as from medical records.

The response to medical treatment was assessed periodically using standard biochemical, radiological, and clinical criteria. All patients were reported to be well controlled with acceptable growth rates and minimal biochemical and radiological evidence of rickets.

As described in the previous study (Seow and Latham 1986), two patients had been diagnosed as having minimal dental manifestations of VDRR (i.e., Grade I severity), and another two had severe dental signs (i.e., Grade III activity). The fifth patient had been classified as showing Grade II severity with moderate dental findings.

Four primary teeth were obtained from each of the five patients for histologic analysis.

Histologic Sections

The teeth were embedded in plastic and sectioned sagittally to 100 μ m using a Bovis Planometer[®] (Allied Hydraulics Pty Ltd., England) sectioning machine.

Hand polishing further reduced the section to 80 μ m. The undecalcified sections were mounted on glass slides and studied under transmitted and polarizing light microscopy at various magnifications. Photographs were taken using a Leitz Ortholux[®] (Leitz-Wetzler, W. Germany) microscope coupled with a Wild Photoautomat[®] (Leitz-Wetzler, W. Germany) exposure control unit and camera.

Results

The general histological features of VDRR were noted in all the sections. Deficient mineralization of dentin, manifested as globular dentin with varying degrees of interglobular spaces was observed in all the teeth. The relative amount of globular dentin varied in teeth from different patients, and also was to be observed in the roots of the teeth.

The enamel appeared normal, as were the dentinoenamel junctions and cementum.

Establishment of Three Histological Grades

The sections were first analyzed with regard to the amount of globular dentin present, as well as its density. Using these criteria, a histological grading was established as follows (Table 1): In Grade I the amount of globular dentin was less than 50% of the total dentin

TABLE 1. Appearance of Dentin in the Three Histological Grades of Vitamin D-Resistant Rickets

Histologic Grade	Appearance of dentin	
	Amount of globular dentin	Interglobular spaces
I	< 50% of total dentin thickness	Minimal
II	> 50% but does not involve entire dentin thickness	Moderate
III	Almost entire thickness of dentin involved	Large

thickness. In addition, the interglobular spaces were small, indicating that the defect in dentin mineralization was mild. Figure 1 shows a representative tooth affected by Grade I severity, and Figure 2 depicts an area of affected dentin under higher magnification (400x), showing the small amount of globular dentin formation and the minimal interglobular spaces present.

In Grade II severity the amount of globular dentin constituted greater than half of the total dentin thickness but does not involve its entire thickness, and the interglobular spaces appear moderately large. Figure 3 shows a typical section affected by Grade II severity and Figure 4 depicts an area of affected dentin under higher magnification (400x) showing moderate amount of globular dentin and interglobular spacing.

Grade III is the most severely affected grade, with globular dentin formation extending almost throughout the entire dentin thickness, and the interglobular spaces are large. In addition, in Grade III sections there was a greater tendency for the occurrence of dentinal clefts which may extend from the pulp to the DEJ. These histological features are shown in Figure 5. In addition, Figure 6 shows an area of affected dentin under higher magnification (400x), depicting the

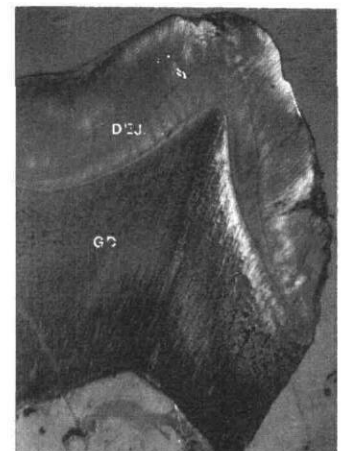


Fig 1. Ground section of a mandibular primary first molar tooth affected by Grade I severity (40x). Note the minimal amount of globular dentin formation and the small interglobular spaces. The neonatal line clearly evident in enamel and that in dentin may be extrapolated from this line. Thus, it may be observed that the prenatally formed dentin is fairly normal. nl: neonatal line; DEJ: dentinoenamel junction; GD: globular dentin; En: enamel.




Fig 2. Higher magnification (400x) of the dentin in the section shown in Fig 1 (Grade I severity) showing globular dentin. For comparison purposes, Figs 2, 4, and 6 were taken from approximately the same location of each tooth (directly beneath the cusp tips) and at the same magnification.




Fig 4. Higher magnification (400x) of the dentin in the section depicted in Fig 3 (Grade II severity) showing moderate amount of globular dentin formation.

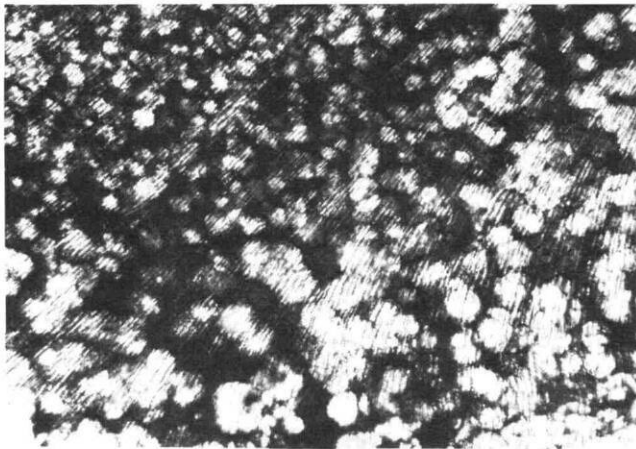


Fig 6. Higher magnification (400x) of the dentin in the section shown in Fig 5 (Grade III severity) depicting large interglobular spaces and severe globular dentin formation.

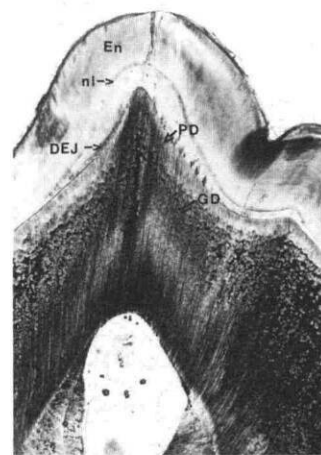


Fig 3. Ground section of a maxillary primary molar tooth affected by Grade II severity (40x). Note the moderate amount of globular dentin formation, and the moderately large interglobular spaces. nl: neonatal line; DEJ: dentino-enamel junction; GD: globular dentin; En: enamel; PD: prenatally formed dentin.

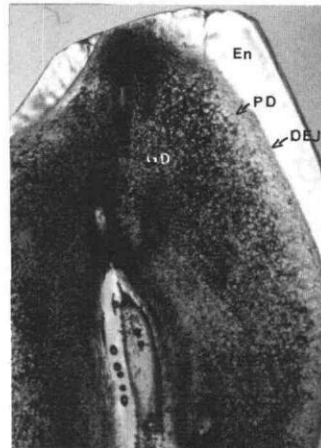


Fig 5. Ground section of a mandibular primary canine tooth affected by Grade III severity (40x). Note that globular dentin is present from the DEJ to close to the pulpal surface. The interglobular spaces also are large and clefts in dentin are observed. En: enamel; DEJ: dentino-enamel junction; PD: prenatally formed dentin; GD: globular dentin.

severity of globular dentin formation and the large interglobular spaces. For comparative purposes, Figures 2, 4, and 6 were taken from the area of globular dentin immediately beneath the cusp tips of the teeth shown in Figures 1, 3, and 5, respectively.

Correlation of Histologic and Clinical Grading

The histologic sections of all the teeth were first grouped according to the above criteria into the 3 histological grades by two of the authors (WKS and KR) without any reference to the clinical gradings previously given to the patients. The histological gradings of all the teeth from each patient were noted. It was observed that for each patient, the histological grading was similar in all of the teeth examined. These histological gradings then were correlated with the clinical gradings of the patients which had been given previously, based on the number of dental abscesses and the sizes of pulp chambers (Seow and Latham 1986).

The results, as shown in Table 2 (page 206), clearly indicate that there is a consistent correlation of clinical and histologic gradings in all the patients studied.

TABLE 2. Dental Manifestations of VDRR: Correlation of Clinical and Histological Gradings

Patient (age)	No. of Abscessed Teeth	Pulp Enlargement	Clinical Grading	Histologic* Grading
M.G. (12 yrs)	21	+++	III	III
S.S. (9 yrs)	20	+++	III	III
N.S. (15 yrs)	3	+	II	II
K.B. (11 yrs)	0	-	I	I
M.B. (7 yrs)	0	-	I	I

* Four deciduous teeth from each patient were used for histologic analysis. The histologic grading of all teeth from any individual patient was identical in all cases.

Appearance of Prenatally Formed Dentin

In the primary dentition, it is possible to distinguish the regions of the teeth mineralized before and after birth by locating the neonatal line in histological sections. Although the neonatal line is not often clearly discernible in dentin, it may be extrapolated from that in enamel, being considered to be of equidistance and of the similar angular inclination from the DEJ (Massler et al. 1941).

Using the technique, the prenatally formed dentin was located in all the teeth from each patient. The results (Table 3) showed that in one patient (SS) prenatally formed globular dentin was present, indicating that the defective mineralization occurred in utero. Of great significance is that in this male patient, the affected mother was not treated during pregnancy. Thus, it is most likely that hypophosphatemia in the mother had affected in utero mineralization of the primary teeth. This prenatally formed globular dentin is evident in Figure 5. Figure 7 shows this area under higher magnification (100x). Of further interest is the observation that although this area of dentin is also globular, the interglobular spaces are markedly smaller, indicating a better degree of mineralization.

TABLE 3. Appearance of Prenatally Formed Dentin in Patients with VDRR

Patient	Sex	Mother Affected	Mother Treated During Pregnancy	Prenatally Formed Interglobular Dentin ¹
M.G.	M	No*	-	0
S.S.	M	Yes	No	+++
N.S.	F	Yes	Yes	0
K.B.	F	Yes	Yes	0
M.B.	M	yes	Yes	0

¹ For each patient, four primary teeth were sectioned. The prenatally formed parts of each tooth were first identified using the neonatal line as indicator. In all cases results were similar in all teeth.

* This case of an affected male child with an unaffected mother in an X-linked dominant disease may indicate a new mutation.

In contrast, in the other four patients, the prenatally-formed dentin appeared fairly normal, and formation of globular dentin appeared to have commenced only after birth. It is of significance that in all these patients, the affected mothers had phosphate replacement therapy during pregnancy, suggesting that correction of hypophosphatemia in the

mother might prevent defective in utero calcification of the primary dentition of the fetus. Figure 3 clearly depicts the apparently normal prenatally formed dentin, and Figure 8 shows this area under higher magnification (100x).

Appearance of Mantle Dentin

It was a consistent observation that the mantle dentin always appeared to be better mineralized compared to the later-formed dentin. This interesting finding, seen in both coronal and radicular dentin, was present even in the Grade III sections showing severe globular dentin formation (Patient SS, Table 3). In these sections, although the mantle dentin also was globular, it appeared better mineralized than the dentin formed later.

Discussion

Although enlarged pulp chambers and globular dentin have been associated with VDRR for some time (Harris and Sullivan 1960; Marks et al. 1965; Archard and Witkop 1966; Soni and Marks 1967; Gardner et al. 1969; Pliskin et al. 1975; Cohen and Becker 1976; Gallo and Merle 1979; Vasilakis et al. 1980), there have been few detailed histological studies of the teeth in this condition. Variability in the amount of globular dentin formation among affected patients first was noted by Soni and Marks (1967) as an incidental finding in their studies. Later, Tracy et al. (1971) subjectively graded severity of globular dentin formation from unaffected to severe in their histological investigation of teeth from seven patients with VDRR, but no relationship of the histological findings to dental clinical data was mentioned.

In a recent investigation by Abe et al. (1988) the analysis of four deciduous teeth from three patients revealed that the phosphorus content of one tooth was

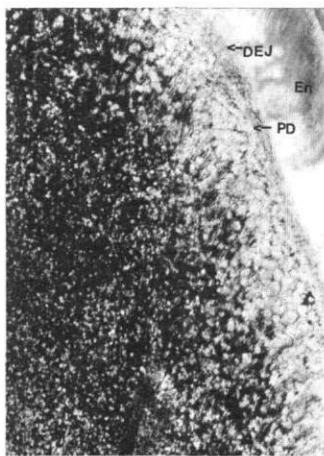


Fig 7. Higher magnification (100x) of the prenatally formed dentin in the section depicted in Fig 5. Note that although the band of dentin closest to the DEJ is better calcified than the later-formed dentin, it is still globular in appearance. En: enamel; DEJ: dentinoenamel junction; PD: prenatally formed dentin.

significantly lower compared to control teeth, although the calcium-to-phosphorus ratio was not abnormal. In this study, however, there was no attempt to correlate dental clinical manifestations with the laboratory findings.

The present investigation extends the earlier observations that there is a spectrum of severity from Grades I to III of globular dentin formation in teeth affected by VDRR and that this histological spectrum correlates closely with the clinical spectrum previously reported (Seow and Latham 1986). This correlation is, of course, not surprising as the teeth most severely affected by globular dentin formation also are those most prone to the development of dental abscesses.

Of even greater significance is the finding from this study that the presence of prenatally formed globular dentin may be related to an affected but not medically treated mother. In contrast, patients with affected mothers who took phosphate supplements in pregnancy showed prenatally formed dentin which appeared normal. This may indicate that in affected females carrying affected children, the fetus is unable to obtain sufficient phosphate for normal mineralization of dentin in utero. However, if the mother is supplemented with phosphate, globular dentin formation may be prevented in the fetus.

To substantiate this hypothesis, it was shown in the present study that one patient (MG, Table 3) who had an unaffected mother showed normal prenatally formed dentin, in sharp contrast to the severe (Grade III) globular dentin formed postnatally. In this case, extensive tests in the mother had definitively established that she did not have VDRR, and the disease in her son was probably caused by a new gene mutation. This unusual case may indicate that a normal mother protects her affected children from globular dentin formation in utero. Further supportive evidence may be obtained from histologic analysis of teeth from affected female children born to unaffected mothers; however, this awaits further investigation.

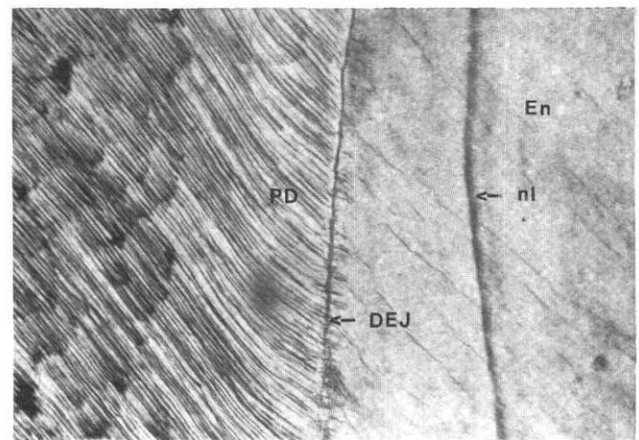


Fig 8. Higher magnification (100x) of the prenatally formed dentin in the section depicted in Fig 6. Note the normal appearance of the band of dentin formed prenatally, in sharp contrast to that seen in Fig 7. nl: neonatal line; DEJ: dentinoenamel junction; PD: prenatally formed dentin; En: enamel.

On the basis of the above findings, implications for a genetic diagnosis may be suggested. In cases of disputed or unknown family histories, it may be possible to determine whether the mother is affected by examining the presence of globular dentin in the prenatally formed regions of the tooth.

The reasons for the broad spectrum of clinical and histological manifestations of VDRR are unclear and may be related to several factors. First, it is possible that VDRR may be inherited in a wide spectrum of severity. Second, females tend to get less severe disease, being protected by the presence of an additional X-chromosome which is normal (Avioli et al. 1967; Sauk and Witkop 1973). Third, medical therapy with phosphate supplementation and calcitriol (vitamin D_3) may improve dental mineralization. In the present study, the two patients with Grade III severity dental manifestations were both diagnosed and treated after the age of two years, when most of the primary dentition is already mineralized.

The value of a grading system in dental conditions is that it provides some guidelines as to the clinical management of the patients (Seow and Latham 1986). In VDRR, prevention of dental abscesses plays a central role in management. Patients exhibiting Grades II and III severity should be placed on an aggressive preventive regime which includes prophylactic stainless steel crowns for posterior teeth (Seow 1984a, 1984b; Seow and Latham 1986) and adhesive resins for anterior teeth. However, patients with Grade I severity may require only routine preventive measures such as fissure sealants and topical fluoride therapy.

In conclusion, the present histological study has substantiated the findings of the previous clinical study

by Seow and Latham (1986) that there is a spectrum of dental manifestations in VDRR. In addition, it was established that adequate phosphate supplementation in a hypophosphatemic mother might prevent the formation of globular dentin in the fetus in utero.

Dr. W. Kim Seow is a senior lecturer in pediatric dentistry, Department of Social and Preventive Dentistry, Dental School, University of Queensland, Turbot Street, Brisbane, Australia 4000. Dr. K. Romaniuk is a senior lecturer in oral biology, University of Queensland. Dr. S. Sclavos is a private dental practitioner. All correspondence should be addressed to Dr. W. Kim Seow. Reprint requests should be sent to: Dr. W. Kim Seow, Dept. of Pediatric Dentistry, University of Queensland Dental School, Turbot St., Brisbane, Queensland 4000 Australia.

Abe K, Ooshima T, Tong SM, Yasufuku Y, Sobne S: Structural deformities of deciduous teeth in patient with hypophosphatemic vitamin D-resistant rickets. *Oral Surg* 65:191-98, 1988.

Archard HO, Witkop CJ: Hereditary hypophosphatemia (vitamin D-resistant rickets) presenting primary dental manifestations. *Oral Surg* 22:184-93, 1966.

Avioli LV, Williams F, Lund J, DeLuca HF: Metabolism of vitamin D₃-³H in vitamin D-resistant rickets and familial hypophosphatemia. *J Clin Invest* 46:1907-15, 1967.

Cohen S, Becker GL: Origin, diagnosis, and treatment of the dental manifestations of vitamin D-resistant rickets: review of the literature and report of a case. *J Am Dent Assoc* 92:120-29, 1976.

Gallo LG, Merle SG: Spontaneous dental abscesses in vitamin D-resistant rickets: report of a case. *ASDC J Dent Child* 46:327-29, 1979.

Gardner DE, David WB, Prescott GH: Hereditary hypophosphatemia. *ASDC J Dent Child* 36:199-216, 1969.

Harris R, Sullivan HR: Dental sequelae in deciduous dentition in vitamin D-resistant rickets. Case report. *Aust Dent J* 5:200-203, 1960.

Harrison HE, Harrison HC: Hereditary metabolic bone diseases. *Clin Orthop* 33:147-56, 1964.

Harrison HE, Harrison HC, Lifshitz F, Johnson AD: Growth disturbance in hereditary hypophosphatemia. *Am J Dis Child* 112:290-97, 1966.

Herbert FL: Hereditary hypophosphatemia rickets: an important awareness for dentists. *ASDC J Dent Child* 53:223-26, 1986.

Marks SC, Lindahl RL, Bawden JW: Dental and cephalometric findings in vitamin D-resistant rickets. *ASDC J Dent Child* 32:259-65, 1965.

Massler M, Schour I, Poncher HG: Developmental pattern of the child as reflected in the calcification of the teeth. *Am J Dis Child* 62:33-67, 1941.

Pliskin ME, Brown AM, Baden EE, Kimball HG: Vitamin D-resistant rickets of young adult patient. A review and case report. *J Oral Med* 30:77-80, 1975.

Sauk JJ, Witkop CJ: Electron optic analysis of human dentin in hypophosphatemic vitamin D-resistant rickets. (Report of a kindred with consanguinity.) *J Oral Path* 2:203-14, 1973.

Seow WK, Latham SC: The spectrum of vitamin D-resistant rickets: implications for management. *Pediatr Dent* 8:245-50, 1986.

Seow WK: The application of tooth separation in clinical pedodontics. *ASDC J Dent Child* 51:428-30, 1984(a).

Seow WK: X-linked hypophosphatemic vitamin D-resistant rickets. *Aust Dent J* 29:371-77, 1984(b).

Soni NN, Marks SC: Microradiographic and polarized-light study of dental tissues in vitamin D-resistant rickets. *Oral Surg* 23:755-62, 1967.

Tracy WE, Steen JC, Steiner JE, Brust NRM: Analysis of dentine pathogenesis in vitamin D-resistant rickets. *Oral Surg* 32:38-44, 1971.

Tulloch EN, Andrews FFH: The association of dental abscesses with vitamin D-resistant rickets. *Br Dent J* 154:136-38, 1983.

Vasilakis GJ, Nygaard VK, DiPalma DM: Vitamin D-resistant rickets. A review and case report of an adolescent boy with a history of dental problems. *J Oral Med* 35:19-26, 1980.

FAX now available for *Pediatric Dentistry*

Authors and other contributors to *Pediatric Dentistry* now have access to a facsimile machine number. You can FAX documents to 312-337-6329, 24 hours a day, 365 days a year. We also accept Macintosh® computer disks and Xmodem transmissions by arrangement with the managing editor. Our voice phone remains 312-337-2169.