

Dental fluorosis as a complication of hereditary diabetes insipidus: studies of six affected patients

W. Kim Seow, BDS_c, MDS_c, DDS_c, PhD, FRACDS M.J. Thomsett, MBBS, FRACP

Abstract

Hereditary diabetes insipidus is a rare endocrine disorder caused by a deficiency of the antidiuretic hormone, vasopressin. The disease is characterized by polyuria, extreme thirst, and polydipsia. In this study of six affected members from two families with hereditary diabetes insipidus, it was found that two children who drank water fluoridated at optimum levels developed moderate to severe fluorosis. By contrast, four other affected patients who did not consume fluoridated water showed normal dentitions. This report indicates that dental fluorosis may be an important complication of diabetes insipidus, and demonstrates the possibility that excessive consumption of optimally fluoridated water can lead to severe developmental enamel defects. (Pediatr Dent 16:128-32, 1994)

Introduction

Pituitary diabetes insipidus is an endocrine disorder that results from a deficiency of the antidiuretic hormone (ADH), vasopressin.¹ This hormone is synthesized in the supraoptic and paraventricular nuclei of the posterior pituitary (neurohypophysis), and the granules containing the packaged neurohormones are transported via the axons to their storage site in the neurohypophysis.² The release of vasopressin is regulated by a complex system that, under physiologic conditions, controls the osmotic pressure of plasma.³ Pituitary diabetes insipidus may arise from pathological conditions of the neurohypophyseal unit. Common causes include head trauma, hemorrhage, histiocytosis, and tumors of the basilar surfaces of the brain.⁴

In rare cases, diabetes insipidus is inherited,⁵ usually in an autosomal dominant manner.^{6,7} Molecular studies have localized the defect to the

preprovasopressin-neurophysin II-glycoprotein complex on chromosome 20, but the precise molecular defect remains unknown.² The disease is characterized by a persistence of inappropriately dilute urine in the presence of strong osmotic or nonosmotic stimuli to ADH secretion, absence of renal concentrating defects, and a rise in urine osmolality upon administration of vasopressin.¹ This disease, which usually presents before age 1, is characterized by polyuria, extreme thirst, and polydipsia. An affected infant is irritable, and is placated only with water rather than additional milk. Hyperthermia, vomiting, constipation, and enuresis may occur in childhood. Dehydration in early infancy may result in brain damage and mental impairment.¹

Diagnosis of hereditary diabetes insipidus usually depends on familial history and clinical symptoms. Analysis of urine osmolality and blood levels of vasopressin may also help to establish diagnosis. Treatment

Table 1. Dental fluorosis in patients with hereditary diabetes insipidus

Patient Number	Age/Sex (Years)	Age of Diagnosis* (Years)	Fluoride in Drinking Water (ppm)	Teeth Present	Teeth Showing Fluorosis (Severity)
1.	38/M	35	< 0.1	7654321 123467 754321 1234568	—
2.	12/F	9	< 0.1	7654321 1234567 7654321 1234567	—
3.	16/F	13	1	87654321 12345678 87654321 1234567	all teeth (moderate)
4.	8/F	5	< 0.1	6EDC21 12CDE6 6EDC21 12 4E6	—
5.	14/F	11	< 0.1	7654321 1234567 7654321 1234567	—
6.	8/F	5	1	6EDC21 12CDE6 6EDC21 12CDE6	all permanent teeth (severe)

* Treatment with DDAVP was instituted in all cases after diagnosis was established.

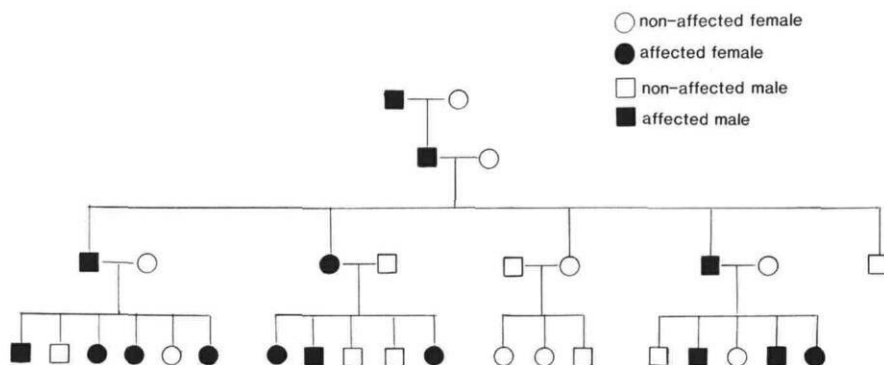


Fig 1. Pedigree of family affected with hereditary diabetes insipidus, showing autosomal dominant inheritance.

Table 2. Peak serum and urine osmolality in affected children from Family 1

Patient Number	Peak Serum Osmolality* (mOsm/L)	Urine Osmolality† (mOsm/L)	Post DDAVP Urine Osmolality (mOsm/L)
3	302	88	135
5	308	288	410
4	290	570	254

* Normal values = 275–295 mOsm/L.

† Normal values after 12 hour fluid restriction: > 850 mOsm/L.

usually consists of administering the drug desmopressin (DDAVP), which is a highly effective analog of vasopressin.^{8,9}

Because only a few families of hereditary diabetes insipidus have ever been reported in the medical literature, the oral manifestations of the condition remain unclear. Apart from a 1975 case report¹⁰ that noted dental fluorosis in a family with hereditary diabetes insipidus, no other investigations are available. The aim of this investigation was to study the dental manifestations of diabetes insipidus, with special regard to dental fluorosis.

Case studies

Family 1

Medical history

A family of five children (one male and four females) was referred to the chief investigator by their endocrinologist for dental evaluation. The father (patient #1, Table 1) as well as three of his female children

(patients #2, 4, 5, Table 1) had been diagnosed three years earlier as having classical hereditary diabetes insipidus. A pedigree history revealed an autosomal dominant mode of inheritance (Fig 1). An affected cousin of the family (patient #3) was also available for dental examination.

All the patients were products of normal pregnancies, and all were born full-term, and were of normal birthweight. Medical diagnosis of hereditary diabetes insipidus was made from family history, clinical symptoms, high urine osmolality in the presence of water deprivation, and increased osmolality after treatment with DDAVP

(Table 2). In addition, biochemical analysis¹¹ revealed total absence of vasopressin in the plasma. All affected family members had classical symptoms of constant thirst, polydipsia, and polyuria. Each patient had an estimated average daily consumption of approximately 8–10 L of water. Nocturnal enuresis was also noted in patients #2 and #4.

In addition, patient #2 was found to have hydronephrosis and hydroureter secondary to diabetes insipidus. Except for patient #3, who was treated with bronchodilators for mild asthma, none of the remain-

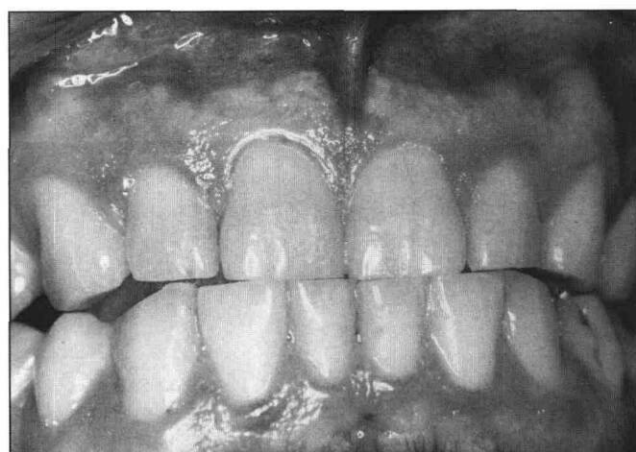

Fig 2. Dentition of father from Family 1 affected with diabetes insipidus. There was no evidence of dental fluorosis. He had lived in a low-fluoride area during his childhood.

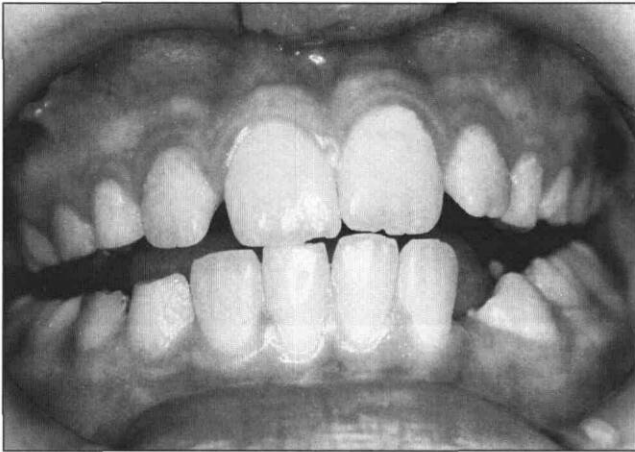


Fig 3. Normal dentition of 8-year-old female patient affected by diabetes insipidus. She had lived in a low-fluoride area until age 4 years.

ing family members had other medical conditions. After diagnosis three years previously, all affected members of the family were placed on DDAVP therapy, at a dose of 10 µg per day, administered intranasally, with good response.

Dental examination

Father (patient #1, Table 1). The father (aged 38 years) had lived in a nonfluoridated area (< 0.1 ppm) throughout childhood. He had never taken fluoride supplements. He has had routine dental care previously, and his dental history was unremarkable.

On dental examination, he had a complete permanent dentition except for both maxillary third molars, maxillary left second premolar, left mandibular second molar, and right mandibular first molar (Fig 2). The occlusion was Class I. An isolated area of enamel hypoplasia (narrow linear area of missing enamel) was noted on the buccal surface of the mandibular left first premolar. There was no evidence of dental fluorosis.

Affected children (patients #2, 4, 5, Table 1). The three female children affected with diabetes insipidus spent most of their early childhood in a low-fluoride area (< 0.1 ppm). The family moved to an optimally fluoridated area (1 ppm) when these children were

aged 4, 8, and 10 years. They were all bottle-fed with formula since birth, and were given plain water or reconstituted fruit cordials when thirsty. There was no history of fluoride supplementation at any time. According to the mother, since approximately age 2, the children's teeth were brushed once a day with a small amount of toothpaste. Previous restorative care was provided through a school dental service.

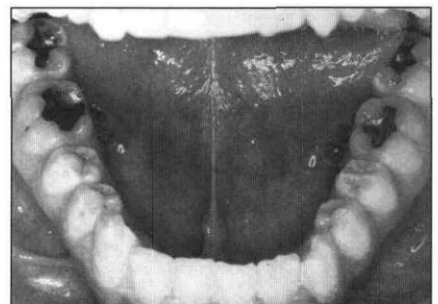
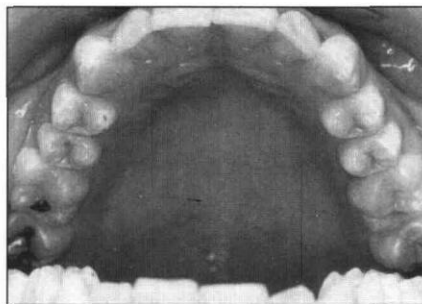
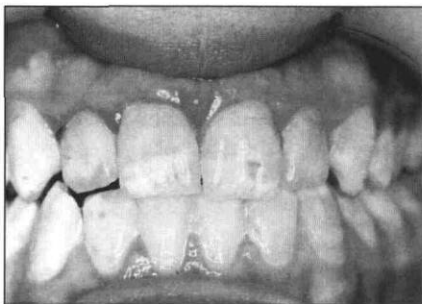Patient #2 (aged 12 years) presented with a full permanent dentition, except for the third molars (Table 1). The occlusion was Class I. Apart from occlusal amalgam restorations on the mandibular first permanent molars, the dentition was intact and showed no abnormalities. A panoramic radiograph showed no abnormalities.

Patient #4 (aged 8 years) presented with a mixed dentition consisting of the first permanent molars, central and lateral incisors, the mandibular left first premolar, and the primary first and second molars and canines except the mandibular left primary canine and first molar (Table 1, Fig 3). The occlusion was Class I. Amalgam restorations were present in the mandibular left and the maxillary right first permanent molars, as well as in all the remaining primary molars. All other teeth were intact and showed no abnormalities.

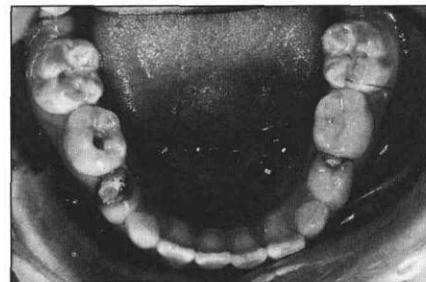
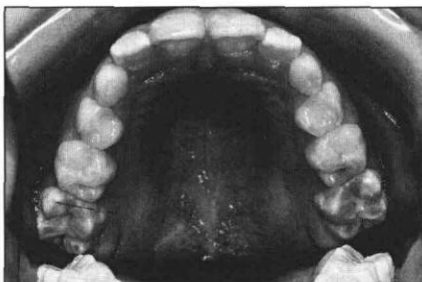
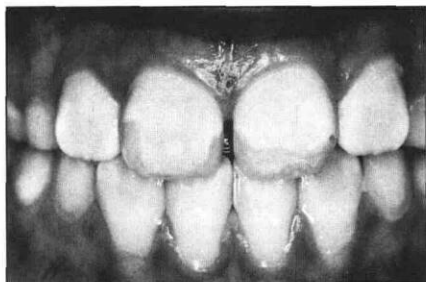
Patient #5 (aged 14 years) presented with a full permanent dentition except the third molars (Table 1). Her occlusion was Class I. Large amalgam restorations were noted in the mandibular first permanent molars as well as in the maxillary left first permanent molar. The other teeth appeared sound.

Affected cousin of the children (patient #3, Table 2). The oldest daughter of the father's sister (Fig 1) also presented for the dental examination. Aged 16 years at the time of dental examination, she was medically diagnosed at the same time as her cousins—approximately three years previously. She had lived all her life in a region with optimally fluoridated water supply (approximately 1 ppm).

She presented with a complete permanent dentition except for an unerupted left mandibular third molar (Figs 4–6). The occlusion was Class I. The entire dentition showed dental mottling, which appeared as opaque white and cream-brown diffuse patches on the enamel



Figs 4, 5, 6. Dentition of 16-year-old female patient affected with diabetes insipidus. The teeth showed typical features of moderate dental fluorosis. She had lived in an optimally fluoridated community throughout her entire childhood.



Figs 7, 8, 9. Dentition of 8-year-old female patient affected with diabetes insipidus, showing severe dental fluorosis. She had lived her entire childhood in an optimally fluoridated area.

(Figs 4–6). Small areas of pitting and brown staining were evident. This appearance was consistent with that of moderate dental fluorosis.^{12–14}

Amalgam restorations were noted on the mandibular first and second molars, as well as on the right maxillary first and second molars.

Family 2

Medical history

An 8-year-old female patient was referred by her dental practitioner to the first author for dental management. She gave a history of familial diabetes insipidus, which had been diagnosed two years previously. She had inherited the disease from her father. Her only sibling, a brother, was not affected. The diabetes was well controlled with intranasal DDAVP, at a dose of 5 µg/day.

Dental examination

The patient had lived all her life in a community with optimally fluoridated water (approximately 1 ppm). She had previous routine dental care from her dental general practitioner and the school dental service.

She presented with a mixed dentition consisting of the permanent first molars and incisors and the primary first and second molars and canines (Figs 7–9). All the permanent teeth showed the typical appearance of severe fluorosis^{12–14}. The enamel appeared uniformly chalky and opaque with a white to cream-brown appearance. There were isolated areas of brown staining and pitting, which was particularly severe on the molars (Figs 7–9). In addition, the enamel on the incisal edges of the maxillary incisors appeared to have chipped off, exposing the underlying dentin (Fig 7). Furthermore, mild, diffuse opacities were noted on the cusps of the second primary molars.

Large amalgam restorations with recurrent decay were noted on the mandibular first primary molars. In addition, unrestored caries was noted on the maxillary left first permanent molar, the maxillary left second primary molar, and the mandibular right second primary molar. A panoramic radiograph showed the unerupted permanent teeth to be developing normally.

Discussion

Excessive consumption of fluoride during the secretory and/or maturation phases of amelogenesis may lead to developmental defects of enamel known as fluorosis.^{15, 16} The condition is characterized by white opacities on the enamel, usually affecting homologous teeth.^{13–14} Posteruptive staining and pitting of the enamel may occur in severe cases. The severity of the enamel lesions depends on the amount of fluoride consumed, the duration of intake, and the stage of enamel formation.

The most common causes of dental fluorosis in young children today are believed to be overdosing with fluoride supplements^{17–19} and inadvertent increased fluoride consumption from swallowing fluoride-containing toothpaste.²⁰ Furthermore, there is evidence that mild to moderate fluorosis in optimally fluoridated communities is increasing;^{17, 21, 22} fluoride levels in water supplies need to be monitored constantly to adjust for fluoride intake from other sources, as well as varying water consumption at different latitudes.²³

In our affected patients, it is obvious that overdoses of fluoride have come from excessive drinking of fluoridated water. Constant thirst, polydipsia, and polyuria are well-recognized signs of diabetes insipidus. The study patients reported an average intake of approximately 8–10 L of water a day. At a fluoride concentration of 1 ppm fluoride in the water, the patients who lived in fluoridated communities would have consumed an average of 8–10 mg of fluoride a day, which is eight- to ten-fold the recommended dose. Thus, the two affected patients in this study showed classical signs of moderate to severe dental fluorosis with the enamel being opaque, pitted, and stained. In both patients, the permanent dentitions were affected, although in the younger child, mild opacities were noted in the second primary molars as well.

By contrast, those patients with diabetes insipidus who did not drink water containing appreciable fluoride did not show the enamel defects (Table 1). This clearly proves that the enamel changes are unlikely to be related to the medical condition itself. Furthermore, a healthy, unaffected sibling of the affected girls in Family 1 showed a normal dentition without any enamel

defects, indicating that normal consumption of the water did not result in enamel changes. The normal teeth in the healthy sibling, as well the dietary and toothbrushing histories of the family, suggest that it is most unlikely that fluoride overdoses could have resulted from sources other than the drinking water.

It is thus suggested that patients with diabetes insipidus avoid drinking water containing fluoride, unless medical treatment has effectively controlled the polydipsia. Fluoride supplements in the recommended doses may be given to replace the fluoride that would have been obtained from drinking fluoridated water.

Various techniques are available to improve the appearance of the fluorotic lesions. The brown stains on the enamel surfaces may be removed by a process of microabrasion, using phosphoric acid.²⁴ This technique, however, does not improve the white opacities, which may need to be masked by composite resin or porcelain veneers using techniques similar to those for managing other enamel defects.²⁵

In conclusion, dental fluorosis should be recognized as an important complication in patients with diabetes insipidus. Although hereditary diabetes insipidus is rare, this study further demonstrates the potential of chronic polydipsia to cause severe dental fluorosis in patients residing in fluoridated communities.

Dr. Seow is associate professor in pediatric dentistry, University of Queensland Dental School, Brisbane, Australia and visiting professor, Harvard School of Dental Medicine and Children's Hospital, Boston, Massachusetts. Dr. Thomsett is consultant endocrinologist, Mater Children's Hospital, South Brisbane, Australia.

1. Crigler JF Jr: Diabetes insipidus. *Curr Pediatr Ther* 11:319-21, 1984.
2. Brownstein MJ, Russell JT, Gainer H: Synthesis, transport and release of posterior pituitary hormones. *Science* 207:373-78, 1980.
3. Schrier RW, Berl T, Anderson RJ: Osmotic and nonosmotic control of vasopressin release. *Am J Physiol* 236:F321-32, 1979.
4. Richman RA, Post EM, Notman DD, Hochberg Z, Moses AM: Simplifying the diagnosis of diabetes insipidus in children. *Am J Dis Child* 135:839-41, 1981.
5. Martin FIR: Familial diabetes insipidus. *Q J Med* 573-82, 1959.
6. Baylis PH, Robertson GL: Vasopressin function in familial cranial diabetes insipidus. *Postgrad Med* 57:36-40, 1981.
7. Pender CB, Fraser FC: Dominant inheritance of diabetes insipidus: a family study. *Pediatrics* 11:246-54, 1953.
8. Robinson AG: DDAVP in the treatment of central diabetes insipidus. *N Engl J Med* 294:507-11, 1976.
9. Hendricks SA, Lippe B, Kaplan SA, Lee WN: Differential diagnosis of diabetes insipidus: use of DDAVP to terminate the seven-hour water deprivation test. *J Pediatr* 98:244-46, 1981.
10. Klein H: Dental fluorosis associated with hereditary diabetes insipidus. *Oral Surg Oral Med Oral Pathol* 40:736-41, 1975.
11. Kaplowitz PB, D'Ercole AJ, Robertson GL: Radioimmunoassay of vasopressin in familial central diabetes insipidus. *J Pediatr* 100:76-81, 1982.
12. Horowitz HS: Indexes for measuring dental fluorosis. *J Public Health Dent* 46:179-83, 1986.
13. Cutress TW, Suckling GW: Differential diagnosis of dental fluorosis. *J Dent Res* 69 (Spec Iss):714-20, 1990.
14. Seow WK: Enamel hypoplasia in the primary dentition: a review. *ASDC J Dent Child* 58:441-52, 1991.
15. Richards A: Nature and mechanisms of dental fluorosis in animals. *J Dent Res* 69 (Spec Iss): 701-5, 1990.
16. Den Besten PK, Heffernan LM: Enamel proteases in secretory and maturation enamel of rats ingesting 0 and 100 ppm fluoride in drinking water. *Adv Dent Res* 3:199-202, 1989.
17. Pendrys DG, Stamm JW: Relationship of total fluoride intake to beneficial effects and enamel fluorosis. *J Dent Res* 69:(Spec Iss):529-38, 1990.
18. Holm AK, Andersson R: Enamel mineralization disturbances in 12-year-old children with known early exposure to fluorides. *Community Dent Oral Epidemiol* 10:335-39, 1982.
19. Larsen MJ, Richards A, Fejerskov O: Development of dental fluorosis according to age at start of fluoride administration. *Caries Res* 19:519-27, 1985.
20. Houwink B, Wagg BJ: Effect of fluoride dentifrice usage during infancy upon enamel mottling of the permanent teeth. *Caries Res* 13:231-37, 1979.
21. Driscoll WS, Horowitz HS, Meyers RJ, Heifetz SB, Kingman A, Zimmerman ER: Prevalence of dental caries and dental fluorosis in areas with negligible, optimal, and above-optimal fluoride concentrations in drinking water. *J Am Dent Assoc* 113:29-33, 1986.
22. Szpunar SM, Burt BA: Trends in the prevalence of dental fluorosis in the United States: a review. *J Public Health Dent* 47:71-9, 1987.
23. Brouwer ID, Dirks OB, DeBruin A, Hautvast JGAJ: Unsuitability of World Health Organisation Guidelines for fluoride concentrations in drinking water in Senegal. *Lancet* 30:223-25, 1988.
24. Croll TP: Enamel microabrasion for removal of superficial dysmineralization and decalcification defects. *J Am Dent Assoc* 120:411-15, 1990.
25. Seow WK: Diagnostic and management strategies for amelogenesis imperfecta. *Pediatr Dent* 15:384-93, 1993.