

# Effect of familial hypophosphatemic rickets on dental development: a controlled, longitudinal study

W. Kim Seow, MDSc, DDS, PhD, FRACDS   Howard L. Needleman, DMD   Ingrid A. Holm, MD

## Abstract

*Familial or X-linked hypophosphatemic rickets (XLHR) is the most common type of rickets in developed countries today. While the dental manifestations of rickets are well reported, there is little information regarding its relationship to dental development and other dental anomalies. This investigation studied the rate of dental development and associated dental anomalies in 19 XLHR subjects compared with 38 race-, age-, and sex-matched control children. The results showed that in both XLHR and control children, no significant differences existed in dental age compared with the respective chronological age, indicating that rickets did not affect the rate of dental development. Longitudinal growth curves of seven XLHR and matched control children substantiated that relationships of dental to chronological ages were comparable in both groups. Male XLHR subjects showed significantly increased tendency for dental taurodontism with mean Crown-Body (CB):Root (R) ratio of 1.1 compared with 1.0 in females and 0.8 in controls ( $P < 0.02$ ). Male XLHR children also showed significantly increased prevalence (50%) of ectopic permanent canines compared with control children (8%,  $P < 0.01$ ). (Pediatr Dent 17:346-50, 1995)*

The most common type of rickets in developed countries today is familial or X-linked hypophosphatemic rickets (XLHR),<sup>1,2</sup> also known as vitamin D-resistant rickets. The usual mode of transmission is X-linked dominant, although other types of inheritance have been described. While the locus product remains unclear, the genetic defect is now known to be a mutation in region Xp22.1-p22.2,<sup>3</sup> which leads to impaired renal reabsorption of phosphate and hypophosphatemia.<sup>2</sup> The main effect of hypophosphatemia is impaired mineralization of teeth, bone, and cartilage.

The mineralization defects of XLHR on the teeth have been well described.<sup>4-12</sup> The main structural dental defects are found in dentin, which is poorly mineralized, hypoplastic, and consists of calcospherites instead of densely mineralized dentin. Gross structural

dental defects that may extend from the pulp to the dentinoenamel junction may be present, so that when the enamel is lost through attrition or caries, pulpal infection occurs.<sup>4</sup> Hence, XLHR often is associated with so-called spontaneous dental abscesses, which occur without any history of trauma or dental decay.

The dentin defects in XLHR are well recognized, but other oral complications remain poorly understood. It is unclear whether dental development is altered in affected patients. Overall development of the dentition may be impaired primarily by hypophosphatemia, or alternatively, by the secondary effects of rickets in bone and dentin. An early investigation<sup>13</sup> noted normal dental calcification as part of a report on facial development in patients with XLHR. By contrast, other case reports<sup>14, 15</sup> have suggested that affected patients have an altered eruption rate, although this is also likely to be caused by local factors such as premature extraction of primary teeth. Controlled longitudinal studies may clarify these confusing results, yet none have been done to date.

Our study was designed to investigate longitudinal dental development in a group of subjects with XLHR compared with healthy, race-, age-, and sex-matched controls. In addition, other developmental abnormalities such as taurodontism also were studied to further define the effect of XLHR on the dentition development.

## Patients and methods

### XLHR subjects

Nineteen XLHR subjects (13 females and six males) from 13 unrelated families were examined. Five of the subjects attended the Dental Department of the Children's Hospital, Boston, and the remaining 14 were referred from endocrinologists to the University of Queensland Dental School for dental evaluation and treatment. Informed consent was obtained from the subjects prior to the dental examination.

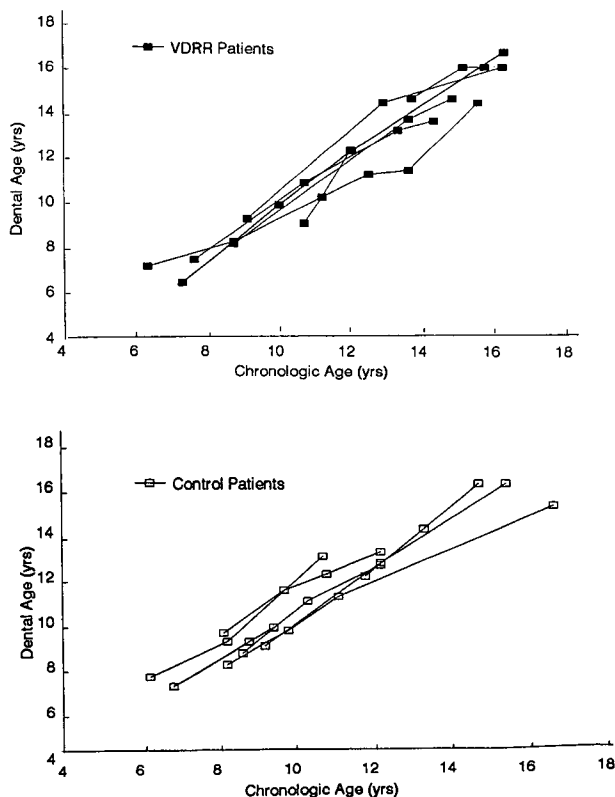
All XLHR subjects had panoramic radiographs suitable for the study. The mean chronologic age of the subjects at the time of panoramic examination was  $10.7 \pm 2.8$  years (range 4.5-14.7 years).

## Control subjects

For each XLHR subject, two control subjects, matched for race, sex, and age were selected from the general patient pool at the University of Queensland Dental School and the Department of Dentistry, Children's Hospital, Boston. All control subjects were healthy, and did not show dental conditions that may affect dental development such as hypodontia,<sup>16</sup> or amelogenesis imperfecta.<sup>17</sup> Each had panoramic radiographs exposed at approximately the same age as the comparison XLHR subjects. Their mean chronological age at radiographic examination was  $10.6 \pm 2.8$  years, (range 4.2–14.5 years).

## Assessment of dental ages

Dental ages were determined from panoramic radiographs employing the method described by Demirjian et al.<sup>18</sup> In this technique, the radiological appearance of each of the seven teeth on the left side of the mandible was graded according to developmental criteria<sup>18</sup> into one of eight stages, A through H. A score for the developmental stage of each tooth was obtained from the reference charts provided by Demirjian et al.<sup>18</sup> The total score of all seven teeth from each patient provided a dental maturity score, which was converted directly



**Fig 1.** Longitudinal dental growth curves of seven XLHR patients and seven matched controls. No significant differences were observed between the two groups in the relationship of dental and chronological ages. All dental age values were within two standard deviations of the normal compared to the corresponding chronological ages in both groups.

to a dental age using the reference standards of Demirjian et al.<sup>18</sup>

Assessment of dental ages was done by one examiner (WKS). Intraexaminer variability for this technique was checked in a previous study<sup>17</sup> and found to be non-significant. A blind technique could not be employed as most of the XLHR subjects could be identified from their radiographic appearance.

## Measurement of crown-body and root lengths

Crown-body and root lengths of the mandibular first permanent molar were determined from panoramic radiographs according to the technique of Seow and Lai,<sup>19</sup> and employed in other investigations.<sup>20,21</sup> In this technique, the crown-body (CB) length was determined on a line drawn from the occlusal pit to the furcation and perpendicular to the line joining the cusp tips. The root (R) length was determined from the furcation to the root tips along the same line as the CB measurement. The mandibular first permanent molar was selected for measurement because previous studies<sup>20,21</sup> have shown minimal distortion of the panoramic radiographic image of this tooth compared with the long-cone exposure.

The assessments were performed by one of the authors (WKS), and the consistency of intraexaminer technique was established in previous studies.<sup>19,21</sup>

## Statistical analysis

The Student's *t*-test or the chi-square test, where appropriate, were used for statistical analysis of the data.

## Results

### Comparison of dental ages and chronological ages

#### Cross-sectional data

As shown in Table 1, the mean dental age of XLHR subjects of  $10.7 \pm 3.0$  years did not differ significantly from their mean chronological age of  $10.7 \pm 2.8$  years.

**TABLE 1. CHRONOLOGIC AND DENTAL AGES OF XLHR SUBJECTS AND MATCHED HEALTHY CONTROLS**

	XLHR Subjects (N = 19)	Healthy Controls (N = 38)	P-value
<b>Chronologic age (CA)</b>			
Mean $\pm$ SD (yrs)	$10.7 \pm 2.8$	$10.6 \pm 2.8$	$P > 0.1$
Range (yrs)	4.5–14.7	4.2–14.5	
<b>Dental Age (DA)</b>			
Mean $\pm$ SD	$10.7 \pm 3.0$	$10.7 \pm 2.9$	$P > 0.1$
Range (yrs)	4.3–14.6	3.9–16.0	
Difference (DA - CA yrs)	$0.1 \pm 0.7$	$0.2 \pm 0.6$	$P > 0.1$
Range (yrs)	-1.0–1.9	-0.9–1.1	

Data revealed no significant differences between the sexes. Similarly, control subjects showed a mean dental age ( $10.7 \pm 2.9$  years) comparable to their mean chronological age ( $10.6 \pm 2.8$  years)

#### Longitudinal data

The longitudinal relationship of dental and chronological ages was examined in seven XLHR subjects who each had at least three panoramic radiographs exposed at various ages ranging from 4 to 16 years. Seven race-, age-, and sex-matched control subjects who each had at least three longitudinal panoramic radiographs exposed at similar age ranges were examined for comparison. The results (Fig. 1) show that in the age range studied, there were no significant differences between the XLHR and control children in the relationship between the chronological and dental ages ( $P > 0.1$ ). Furthermore, in both groups of children, all the values for both chronological and dental ages were within two standard deviations of the mean, i.e. ranging between 10th and 90th percentile of the normal dental maturity curves.<sup>18</sup>

#### Crown-body (CB) and root (R) lengths and taurodontism in XLHR and control subjects

As shown in Table 2, the overall mean CB length of the mandibular first permanent molars in XLHR children (12.4 mm) was significantly greater than that of the control group (11.8 mm;  $P < 0.02$ ). In addition, the mean R lengths of the XLHR group were significantly

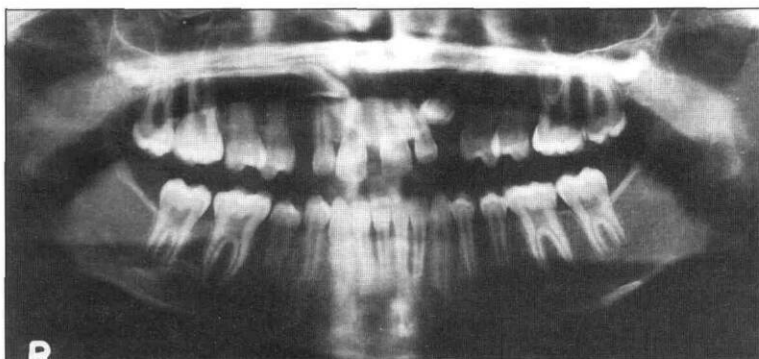


Fig 2. Panoramic radiograph of a male XLHR patient showing severe taurodontism of the permanent molars and impaction of the maxillary permanent canine teeth.

shorter than those of the control group (12.1 mm versus 14.2 mm;  $P < 0.001$ ).

To determine if there were significant differences between males and females in the XLHR and control groups, the CB and R lengths in females and males of each group were compared. As shown in Table 2, a statistically significant difference was found only in the CB length between females and males in the XLHR group (13.4 mm in males versus 11.7 mm in females,  $P < 0.01$ ). By contrast, no significant difference between the sexes was found in their R lengths ( $P > 0.1$ ). Fig 2 shows the panoramic radiograph of a male XLHR subject depicting the taurodontic permanent molars.

Taurodontism was objectively diagnosed as present if the CB:R ratio was 1.1 or greater.<sup>19</sup> In the XLHR group, taurodontism was observed in only the male subjects who had a mean CB:R ratio of 1.10. In the con-

TABLE 2. CROWN-BODY AND ROOT LENGTHS OF MANDIBULAR FIRST PERMANENT MOLARS AND TAURODONTISM IN XLHR AND CONTROL CHILDREN

	XLHR (No. of teeth)				Controls (No. of teeth)			
	Females (N = 18)	Males (N = 12)	Both (N = 30)	P-value	Females (N = 36)	Males (N = 24)	Both (N = 60)	P-value
Crown-body (CB)								
Length (mm)	11.7	13.4	12.4*	$P < 0.01$	11.8	11.9	11.8	$P > 0.1$
SD	1.0	1.8	1.7		0.8	1.0	0.9	
Range (mm)	8.9-13.6	11.2-16.0	8.9-16.0		10.0-14.2	10.1-13.3	10.0-13.3	
Root								
Length (mm)	12.0	12.2	12.1†	$P > 0.1$	14.0	14.7	14.2	$P > 0.1$
SD	2.1	1.4	1.8		1.3	1.8	1.4	
Range	8.0-16.4	9.9-14.5	8.0-16.4		11.5-17.2	12.4-17.0	11.5-17.2	
CB:R ratio	1.0	1.1	1.0		0.8	0.8	0.8	
Taurodontism	-	+			-	-	-	

\*  $P < 0.02$  between XLHR patients and controls.

†  $P < 0.001$  between XLHR patients and controls.

trol group, the mean CB:R ratio was 0.80, indicating normal (cynodont) morphology.

### **Other dental anomalies**

#### ***Ectopic eruption of canines***

The panoramic radiographs of both XLHR and control subjects were surveyed for structural and positional abnormalities of the teeth. Ectopic canines were diagnosed if the teeth appeared substantially deviated from their normal eruption paths. In the XLHR group, four of 19 patients (21%) had ectopic eruption of the permanent canines unrelated to crowding (Fig 2). This prevalence differed significantly from that of the control group in which only two of 38 (5.2%) subjects had the condition ( $P < 0.01$ ).

A significant difference in the prevalence of ectopic permanent canines was observed between males (three of six; 50%) and females (one of 12; 8%) in the XLHR group ( $P < 0.01$ ). In contrast, in the control group, the prevalence in males was one of 12 (8%) and in females one of 24 (4%). This difference was not statistically significant ( $P > 0.1$ ).

#### ***Generalized root resorption***

Generalized idiopathic blunting of all the roots of the permanent teeth was observed in a XLHR female subject who had not undergone orthodontic treatment or suffered facial trauma.

## **Discussion**

XLHR is of special interest to dentists because of the multiple dental infections commonly associated with the condition and the potential for dentists to diagnose the disease from the dental signs that may be the first obvious manifestations in a young patient.<sup>4</sup> However, while the dental mineralization defects associated with these infections are well known,<sup>4-12</sup> little information is available on other dental aspects of the condition.

The results of our longitudinal study conducted on a relatively large population of XLHR patients have clarified the issue of whether dental development and eruption are affected in XLHR. Early attempts based on case reports and small cross-sectional, uncontrolled studies to address this question had shown equivocal results. Tracy and Campbell<sup>23</sup> found in an uncontrolled, cross-sectional study of nine XLHR children, no significant changes in their dental calcification ages compared with their chronological ages. Other studies related to dental eruption, such as emergence, may provide some indication of dental development. Dental eruption, however, may not directly reflect dental development, as local factors such as early or delayed extraction of primary teeth also may influence eruption. The delayed eruption observed in the studies of Winters et al.,<sup>14</sup> and Harris and Sullivan<sup>22</sup> may be the result of such local factors. This possibility is supported by the observations of Marks et al.<sup>13</sup> who found delayed eruption in only one of seven children with XLHR.

Our controlled investigation of 19 XLHR subjects showed no significant changes in their rate of dental development compared with healthy children. These observations were further substantiated by our longitudinal data on seven affected subjects. The dental ages of those studied were comparable to their chronological ages at various stages of their development, and the relationship between the two ages was not significantly different from that of unaffected controls.

The above results suggest that XLHR does not have an effect on the rate of dental development and maturation, or alternatively, that medical therapy has been successful in preventing derangements of dental development. All the cases in our study were diagnosed when the patient was younger than 2 years of age, which would have permitted adequate time for dental growth correction prior to dental assessment. Previous studies on general body growth in affected humans<sup>24, 25</sup> and animal models<sup>26</sup> of XLHR have shown reduced stature, due mainly to impairment of growth in the legs and craniofacial problems such as craniosynostosis<sup>27</sup> with frontal and occipital bossing and oxycephaly.<sup>13, 26</sup> Attenuated growth in the mandible and maxillary length and depth also have been reported.<sup>23</sup> However, in spite of these morphological abnormalities associated with XLHR, recent longitudinal studies<sup>24, 25</sup> have shown that general growth curves and pubertal growth spurts followed normal patterns, and no significant differences between bone age and chronological age even though the average height of affected patients was two standard deviations below normal.

XLHR may be associated directly with increased prevalence of dental taurodontism — an increase in the length of the body at the expense of the root.<sup>21</sup> The male subjects had significantly longer crown-body lengths and shorter root lengths than the healthy controls. In addition, 21% of all XLHR subjects showed ectopic eruption of permanent canines compared with only 5% of controls. A significant difference was found between the sexes, with three of six (50%) male subjects and one female of 12 (8%) with XLHR having the condition. This extremely high prevalence compared with prevalences ranging from 0.9 to 3.3<sup>28</sup> reported in the general population suggests a strong association of this dental anomaly with XLHR.

The dental taurodontism and high prevalence of impacted canines were observed only in male XLHR subjects. Males are usually more severely affected than females in an X-dominant disease. This has been explained by the hemizygous nature of the disease allele in males. Females are heterozygous and, assuming random X-inactivation, have half the gene dosage of males on average. Our results are consistent with this genotype-phenotype relationship between the dental changes and the disease.

Taurodontism usually is thought to have resulted from an abnormality of the Hertwig sheath, resulting in delayed invagination. In the case of XLHR this ab-

normality may result from an associated gene abnormality or alternatively, indirectly through an abnormal interaction of the root sheath with rachitic bone. Similarly, ectopic canines likely result from abnormal interaction of the tooth follicle with rachitic bone so that normal paths of eruption are not achieved.

Serious clinical implications can be associated with dental taurodontism in XLHR. The pulp chamber size already is increased due to reduced dentin thickness in XLHR, so taurodontism may lead to further anatomical enlargement of the pulp, thus increasing the patients' susceptibility to dental infections. Furthermore, severe taurodontism is associated with other endodontic complications such as increased accessory canals in the apical parts of the root canal system.<sup>29</sup>

## Conclusions

1. XLHR does not cause significant changes in rates of dental development.
2. In addition to well-known mineralization defects, XLHR is associated with dental taurodontism and ectopic permanent canines.

Dr. Seow is an associate professor in pediatric dentistry, University of Queensland Dental School, Australia, and a visiting professor, Harvard School of Dental Medicine and Children's Hospital, Boston. Dr. Needleman is associate dentist-in-chief, Children's Hospital, Boston, and an associate clinical professor, Harvard School of Dental Medicine. Dr. Holm is an instructor at Harvard Medical School, and an assistant in medicine (genetics and endocrinology) Children's Hospital, Boston, Massachusetts.

1. Tenenhouse HS, Scriver CR: X-linked hypophosphatemia. A phenotype in search of a cause. *Int J Biochem* 24:685-91, 1992.
2. Nakagawa N, Ghishan FK: Transport of phosphate by plasma membranes of the jejunum and kidney of the mouse model of hypophosphatemic vitamin D-resistant rickets. *Proc Soc Exp Biol Med* 203:328-35, 1993.
3. Rowe PS, Goulding J, Read A, Mountford R, Hanauer A, Oudet C, Whyte MP, Meier-Ewert S, Lehrach H, Davies KE, et al: New markers for linkage analysis of X-linked hypophosphatemic rickets. *Hum Genet* 91: 571-75, 1993.
4. Seow WK: X-linked hypophosphatemic vitamin D-resistant rickets. *Aust Dent J* 29:371-77, 1984.
5. Seow WK, Latham SC: The spectrum of dental manifestations in vitamin D-resistant rickets. *Pediatr Dent* 8:245-50, 1986.
6. Seow WK, Romaniuk K, Sclavos S: Micromorphologic features of dentin in vitamin D-resistant rickets: correlation with clinical grading of severity. *Pediatr Dent* 11:203-8, 1989.
7. Seeto E, Seow WK: Scanning electron microscope analysis of dentin in vitamin D-resistant rickets — assessment of mineralization and correlation with clinical findings. *Pediatr Dent* 13:43-48, 1991.
8. Seow WK: The effect of medical therapy on dentin formation in vitamin D-resistant rickets. *Pediatr Dent* 13:97-102, 1991.

9. Abe K, Ooshima T, Tong SML, Yasufuku Y, Sobue S: Structural deformities of deciduous teeth in patients with hypophosphatemic vitamin D-resistant rickets. *Oral Surg* 65:191-98, 1988.
10. Larmas M, Hietala EL, Similä S, Pajari U: Oral manifestations of familial hypophosphatemic rickets after phosphate supplement therapy: a review of the literature and report of case. *ASDC J Dent Child* 58:328-24, 1991.
11. Abe K, Masatomi Y, Nakajima Y, Shintani S, Moriwaki Y, Sobue S, Ooshima T: The occurrence of interglobular dentin in incisors of hypophosphatemic mice fed a high-calcium and high-phosphate diet. *J Dent Res* 71:478-83, 1992.
12. Fadavi S, Rowold E: Familial hypophosphatemic vitamin D-resistant rickets: review of the literature and report of a case. *ADSC J Dent Child* 53:223-26, 1986.
13. Marks SC, Lindahl RL, Bawden JW: Dental and cephalometric findings in vitamin D-resistant rickets. *J Dent Child* 32:259-65, 1965.
14. Winters RW, Graham JB, Williams TF, McFalls VW, Burnett CH: A genetic study of familial hypophosphatemia and vitamin D-resistant rickets with a review of the literature. *Medicine* 37:97-142, 1958.
15. Bender IB, Naidorf IF: Dental observations in vitamin D-resistant rickets with special reference to periapical lesions. *J Endodont* 11:514-20, 1985.
16. Schalk van der Weide Y, Prahl-Andersen B, Bosman F: Tooth formation in patients with oligodontia. *Angle Orthod* 63:31-37, 1993.
17. Seow WK: A controlled study of dental development in amelogenesis imperfecta. *Pediatr Dent* 17:26-30, 1995.
18. Demirjian A, Goldstein H, Tanner JM: A new system of dental age assessment. *Hum Biol* 45:211-27, 1973.
19. Seow WK, Lai PY: Association of taurodontism with hypodontia: a controlled study. *Pediatr Dent* 11: 214-19, 1989.
20. Schalk-van der Weide, Steen WHA, Bosman F: Taurodontism and the length of teeth in patients with oligodontia. *J Oral Rehabil* 20:401-12, 1993.
21. Seow WK: Taurodontism of the mandibular first permanent molar distinguishes between the tricho-dento-osseous (TDO) syndrome and amelogenesis imperfecta. *Clin Genet* 43:240-46, 1993.
22. Harris R, Sullivan HR: Dental sequelae in deciduous dentition in vitamin D-resistant rickets: case report. *Austral Dent J* 5:200-3, 1960.
23. Tracy WE, Campbell RA: Dentofacial development in children with vitamin D-resistant rickets. *J Amer Dent Assoc* 76:1026-31, 1968.
24. Steendijk R, Hauspie RC: The pattern of growth and growth retardation of patients with hypophosphatemic vitamin D-resistant rickets: a longitudinal study. *Eur J Pediatr* 151: 422-27, 1992.
25. Balsan S, Tieder M: Linear growth in patients with hypophosphatemic vitamin D-resistant rickets: influence of treatment regimen and parental height. *J Pediatr* 116:365-71, 1990.
26. Shetty NS, Meyer RA: Craniofacial abnormalities in mice with X-linked hypophosphatemic genes (Hyp or Gy). *Tetralogy* 44:463-72, 1991.
27. Reilly BJ, Leeming JM, Fraser D: Craniosynostosis in the rachitic spectrum. *J Pediatr* 64:396-405, 1964.
28. Ferguson JW: Management of the unerupted maxillary canine. *Br Dent J* 169:11-17, 1990.
29. Ogden GR: Significance of taurodontism. *Dental Update* 15:32-34, 1988.