

A two-step separation technique for fused teeth: clinical report

Joseph Shapira, DMD David Kochavi, DMD
Doron Harary, DMD Aubrey Chosack, BDS (Rand), MSD

Abstract

An unusual case of fusion combined with concrescence of a supernumerary tooth and a central incisor is presented. In order to prevent a deep periodontal pocket following the separation, a two-step technique was attempted. The first stage consisted of surgical exposure of the roots and separation with closure to allow in-growth of connective tissue. Four weeks later, the fused crowns were separated and one of the teeth was extracted. One year after the separation a periodontal pocket of 3 mm was present at the separation site. Suggestions for use and improvement of the technique are given.

Fusion has been defined as the dentinal union of two or more originally individual teeth.¹⁻⁴ It may involve a normal and a supernumerary tooth (mesiodens or supplementary tooth).

Gemination (Latin, twinning) is believed to be the result of splitting or incomplete division of a single tooth germ.^{1,2,4} Tannenbaum and Alling³ stated that in gemination, if the bifid tooth is counted as one entity, the total number of teeth in the dental arch is normal. This compares to the fusion of two normal teeth where there should be one fewer tooth in the arch. If the fusion is between a supernumerary and a normal tooth there would be no reduction in the number of teeth.

Concrescence is defined as the union of teeth by cementum only.^{1,2,4} There is disagreement as to whether it happens during or after root formation.¹

Clem and Natkin⁵ described the treatment of a supernumerary tooth fused to an incisor tooth. They used a labial flap, removed about 3 mm of crestal bone, separated the two segments and extracted the central incisor, leaving the mesiodens portion because of its more normal position. Good and Berson⁶ described a case in which they removed the complete crown and a section of the root of a labially positioned supernumerary tooth to the level of the cemento-enamel junction. A periodontal problem developed in this case. In both of these cases, no continuity was found between the pulp chambers and canals of the fused teeth.

The purpose of this paper is to report on an unusual case of fusion combined with concrescence and a treatment approach designed to solve the esthetic and potential periodontal problem.

Clinical Report

A 10-year-old boy presented at the pedodontic clinic of the Hebrew University Hadassah School of Dental Medicine complaining about "the funny giant front tooth."

Oral examination revealed an abnormally wide maxillary right central incisor crown, divided unevenly by a longitudinal groove. The total width was nearly twice that of the left central incisor (Figure 1). The left central

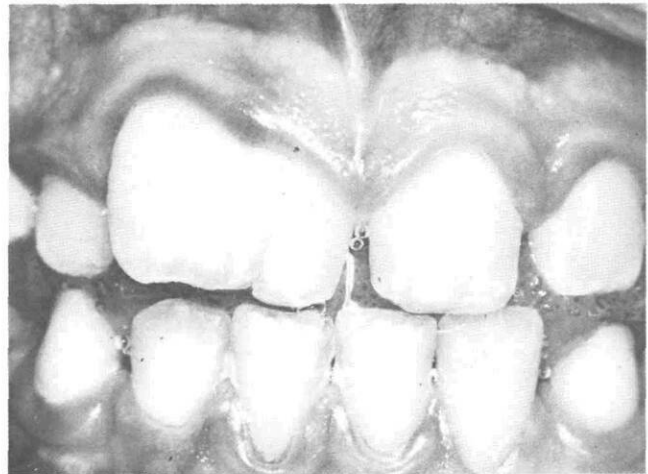

Figure 1. The wide central incisor was diagnosed as either gemination or fusion between the central incisor and a supernumerary tooth.

incisor and the right lateral incisor (both normal size), were present in the arch. Therefore, the differential diagnosis was either gemination of the central incisor, or fusion between the central incisor and a supplemental tooth.

Radiographs showed the presence of two separated roots with wide bifurcation (Figure 2). The individual root canals could be followed into the pulp chamber on either side but it was unclear whether the pulp chambers were

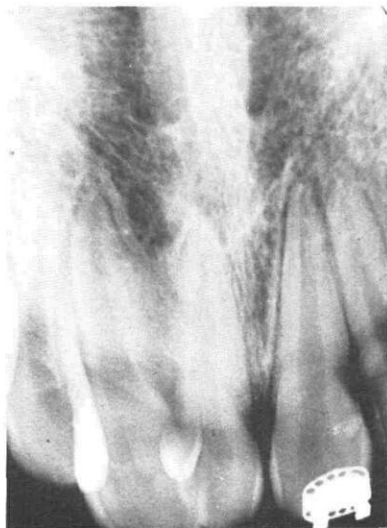

Figure 2. Radiograph of the fused teeth demonstrating the two roots joined by a sheet of radiopaque material between them. Note the continuation of the PDL across the base of this sheet.

separated. Close examination of the radiographs demonstrated a sheet of radiopaque material, forming a continuous web between the two roots. This material was diagnosed as cementum because of the position and degree of radiopacity. A normal-appearing periodontal ligament space and lamina dura could be followed along the lateral aspects of both roots and along the base of the cementum web separating the latter from the surrounded bone.

Treatment

Following infiltration anesthesia, a semilunar flap was elevated to expose the area between the two roots. After removing the bone covering the mesioapical third of the distal root, it was possible to detect the hard material connecting the roots with a probe. The distal root was separated from the web attached to its mesial side to a point near the bifurcation using a thin fissure bur with low speed and coolant spray (Figure 3). The fissure was cleaned and the flap was repositioned and sutured. Four weeks later, after waiting for connective tissue repair, a labial flap was again elevated. The crown was separated with high-speed handpiece, leaving a mesial portion of

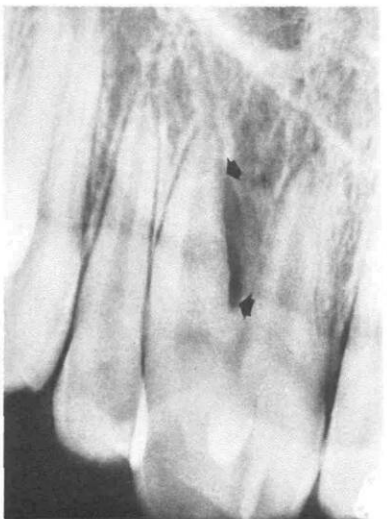


Figure 3. Radiograph following initial separation of the distal root from the web attached to its mesial side (to a point near the bifurcation). Arrows indicate radiolucent area of the separation site.

the crown the same width as the crown of the left central incisor. The separation was continued to the incisal end of the fissure made in the first step, and the distal section of the fused tooth was removed with extraction forceps. Examination of the extraction socket showed a definite wall separating the socket from the mesial root and remaining cementum web (Figure 4).

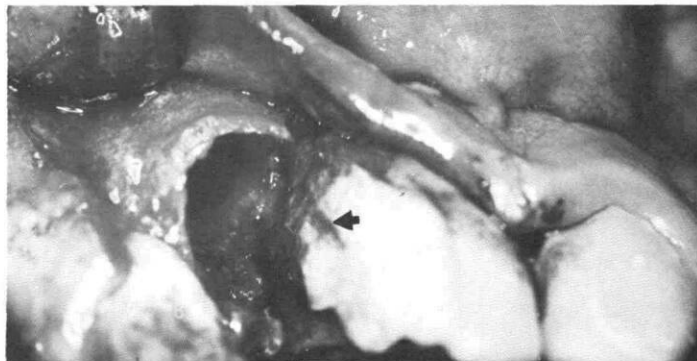


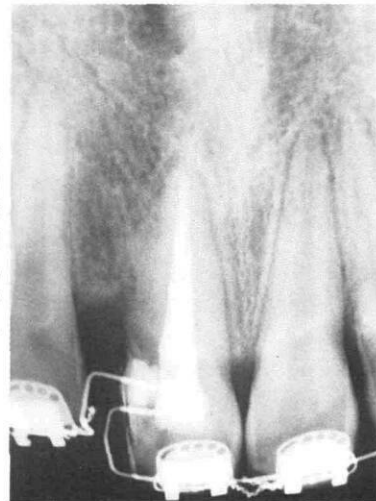Figure 4. Postextraction photograph showing a connective tissue wall separating the socket from the mesial portion of the fused teeth. Note a pulp exposure in the coronal portion.

A pulp exposure detected on the distal portion of the remaining crown was covered temporarily. The flap then was repositioned and sutured. One week later a root canal treatment was completed and the distal portion of the crown was shaped esthetically with a composite resin restoration.

A followup examination four months later revealed a stable tooth with no mobility. Gingival health was good and a periodontal pocket of 3-4 mm was detected at the distal part of the crown. Radiographic examination (Figure 5) revealed a resorption of the major portion of the cementum attached to the mesial root. Orthodontic treatment was underway using edge-wise technique to close the space left between the upper anterior teeth (Figure 6).

Eight months after restoration placement, clinical

Figure 5. Four months postoperative radiograph showing a resorption of the major portion of the cementum attached to the mesial root, and progress of orthodontic closure of the extraction site.



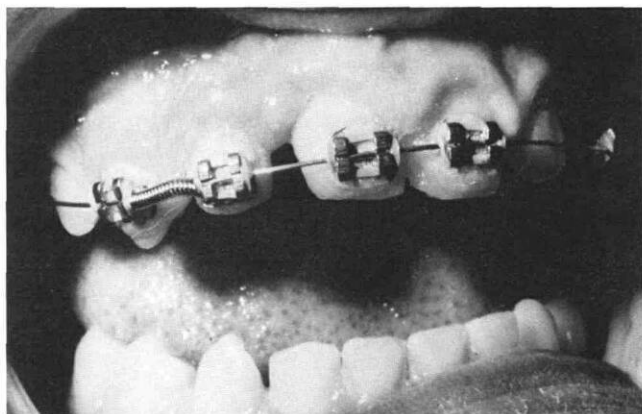


Figure 6. The fused teeth four months following the separation, showing progress in the space closure between the upper anterior teeth.

evaluation revealed a 4 mm periodontal pocket at the distal part of the crown, and radiographs revealed resorption of most of the cementum web, and a distinct periodontal space around the root (Figure 7).

Discussion

The major problem in treating the fusion and concrescence was how to separate the teeth and remove one of them without leaving a deep subosteal periodontal pocket.

A decision also had to be made on whether to remove the mesial or distal section. Removal of the mesial portion with the shorter root would have left a more normal-appearing crown and longer root, but would have demanded mesial orthodontic movement of both this tooth and the lateral incisor. One possible complication of the separation could have been continued pathological root resorption and orthodontic movement might have increased this possibility. It was decided, therefore, to remove the distal portion.

A one-step separation and extraction would have left denuded cementum and dentin surfaces followed by an ingrowth of epithelium into the depth of the socket. This would result in a deep subosteal periodontal pocket. To avoid this, a technique was developed that would simulate the healing process seen following apicoectomy. By raising a semilunar flap, separating the roots, and closing the wound to prevent epithelial in-growth, repair similar to that seen following apicoectomies was hoped for. Healing of connective tissue followed by eventual bone replacement and establishment of a periodontal membrane, was the expected course of recovery. Eight months after the operation the depth of the pocket appeared to reach the lowest border of the separation done in the first operation. This indicated that the idea of performing the two-step operation was correct, but that the

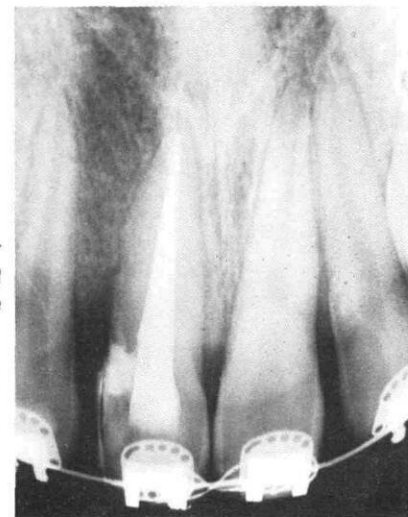


Figure 7. Eight months post-operative radiograph showing a distinct periodontal space around the root.

extension cervically was insufficient in the first step. It is suggested, therefore, that in future use of this technique, the separation in the first stage should be extended cervically as far as possible without causing a break into the epithelial attachment (this would result in a down-growth of epithelium and failure).

Conclusion

This two-step technique proved to be a success. The extent of separation cervically in the first step apparently determines the depth of the pocket after such an operation.

This technique also could be used when separating fused or geminated teeth when the roots are joined to such an extent that a deep periodontal pocket would result if separation was attempted in a single operation.

Dr. Shapira is a lecturer, Department of Pedodontics; Dr. Kochavi is a lecturer, Department of Perio-Prosthodontics; Dr. Harary is an instructor, Department of Orthodontics; and Dr. Chosack is an associate professor, Department of Pedodontics, The Hebrew University, Hadassah Faculty of Dental Medicine, Box 12000, Jerusalem, Israel. Reprint requests should be sent to Dr. Shapira.

1. Gorlin, R.J., Goldman, H.M., eds. *Thoma's Oral Pathology*. St. Louis: C.V. Mosby Co., 1970, Ch. 3.
2. Spouge, J.D. *Oral Pathology*. St. Louis: C.V. Mosby Co., 1973, pp 134-37.
3. Tannenbaum K.A., Alling, E.E. Anomalous tooth development: case report of gemination and twinning. *Oral Surg* 16:883-87, 1963.
4. Stewart, R.E., Barber, T.K., Troutman, K.C., Wei, S.H.Y., eds. *Pediatric Dentistry - Scientific foundations and clinical practice*. St. Louis: C.V. Mosby Co., 1982, p 100.
5. Clem, W.H., Natkin, E. Treatment of the fused tooth - report of a case. *Oral Surg* 21:365-70, 1966.
6. Good, D.L., Berson, R.B. A supernumerary tooth fused to a maxillary permanent central incisor. *Pediatr Dent* 3:346-47, 1981.