

Dental management of a child on anticoagulant therapy and the International Normalized Ratio: case report

Barbara Sheller, DDS, MSD Darryl Tong, BDS

Abstract

A 7-year-old girl with a history of four prosthetic heart valve replacements and daily anticoagulant therapy was treated with modification of the anticoagulant regimen and hospitalization. Coagulation times now are being expressed using the International Normalized Ratio (INR), a move by the international medical community to standardize laboratory values worldwide. This report describes this new measure and its role in patient assessment. (*Pediatr Dent* 16:56-58, 1994)

Introduction

Ebstein's anomaly is a malformation in which septal and posterior leaflets of the tricuspid valve are displaced on the wall of the right ventricle in a downward position with the anterior leaflet attached to the annulus fibrosus of the tricuspid valve. As a result, the right atrium is exceptionally large, the right ventricle small, and the tricuspid valve insufficient. Ebstein's anomaly usually is associated with an atrial septal defect (Fig 1).^{1,2} This condition is treated by surgical replacement of the tricuspid valve.

Patients with prosthetic heart valves are maintained on anticoagulants to minimize thromboembolic complications. Historically, the efficacy of anticoagulants has been measured by the prothrombin time (PT). The

International Normalized Ratio (INR) has been devised in an attempt to standardize PT values between laboratories.^{3,4} The INR is appearing with increasing frequency in the literature on measuring prothrombin times.

This case report describes the use of the INR for evaluating one pediatric patient requiring dental treatment.

Case report

A 7-year-old, 21.8-kg girl was referred by her dentist to the Department of Dental Medicine at Children's Hospital and Medical Center. Her medical history included Ebstein's anomaly of the heart, four surgeries for prosthetic tricuspid heart valve replacement, con-

tinuous oral anticoagulant therapy with Coumadin™ (Du Pont Pharmaceuticals, Wilmington, DE) and an allergy to penicillin and sulfa drugs. The referring dentist stated the child was difficult to treat and too risky to sedate in his dental office.

The dental examination revealed an early mixed dentition with caries in multiple primary teeth and periapical abscess with draining fistulae in all first primary molars. Radiographs were not exposed until general anesthesia.

Consultation with the patient's cardiologist and hematologist led to a plan for temporary withdrawal of the anticoagulant agent, hospitalization, SBE prophylaxis, dental restorations, and ex-

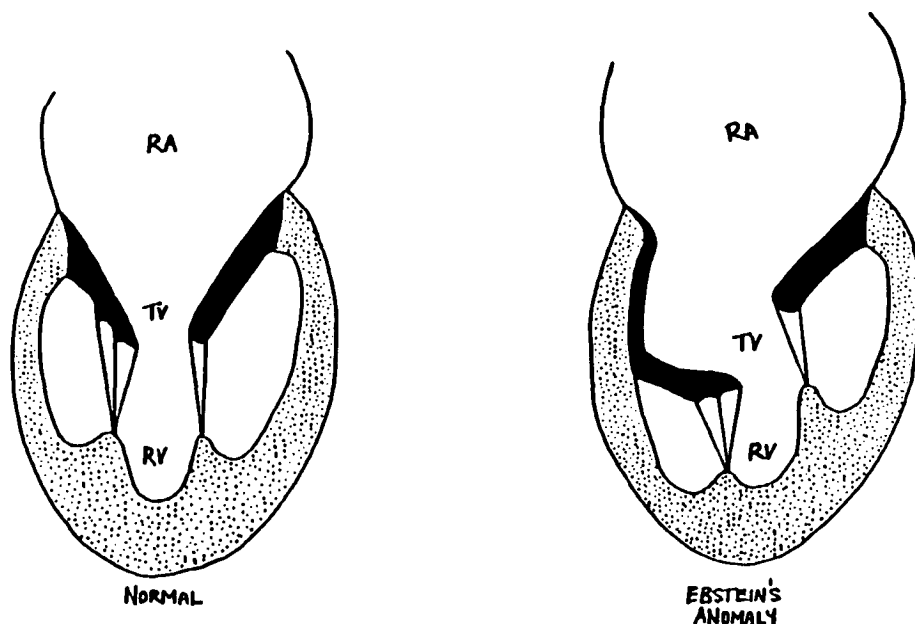


Fig. Diagrammatic comparison between Ebstein's anomaly and a normal heart. RA: Right Atrium, TV: Tricuspid Valve, RV: Right Ventricle.

tractions under general anesthesia. Anticoagulant therapy was to be resumed following dental treatment. Her cardiologist was concerned that the patient had lost two prosthetic heart valves due to coagulation problems and, although he understood the rationale for stopping anticoagulation therapy for the treatment, stressed the need for a return to maintenance anticoagulant levels immediately after dental treatment.

The patient was receiving oral anticoagulant therapy using Coumadin in varying dosages according to the day of the week (1 mg bid Monday, Wednesday, Friday, and Sunday, and 1.5 mg Tuesday, Thursday, and Saturday). Her PT and INR were significantly above normal and unacceptable for dental extractions.

The patient stopped Coumadin two days prior to surgery. Twenty-five mg dipyridamole (Persantine™—Boehringer Ingelheim Pharmaceuticals, Inc. Ridgefield, CT), which lengthens abnormally shortened platelet survival time, was given 11 hr prior to surgery. Clindamycin (200 mg), and gentamicin (45 mg), were given IV as prophylactic premedication against bacterial endocarditis. Dental treatment was completed with the patient under general anesthesia and included radiographs, prophylaxis, sealants, stainless steel crowns, and three primary molar extractions.

Avitene™ (Avitene Med Chem, Woburn, MA) was placed in the tooth sockets and interrupted resorbable sutures used for primary closure of the extraction sites.

The patient received clindamycin (200 mg), and gentamicin (45 mg), IV 6 hr postoperatively. Anticoagulant therapy was restarted 7 hr after surgery. The patient's postoperative dental course was uneventful, with no bleeding or oozing, and she was discharged one day postoperatively.

Discussion

Dental treatment for this patient posed several interesting problems: extensive dental caries with multiple periapical abscesses, a history of uncooperative behavior for dental treatment, a severe systemic disorder categorized as ASA Class III,⁵ and a very high risk for bacteremia-induced infection.⁶ Initial contact with the patient's cardiologist led to the discovery that the INR is becoming the standard for quantifying the status of patients receiving anticoagulants. The INR has not been widely reported in pediatric dental literature.

This patient had a porcine valve replacement at 2-1/2 years old, which failed due to valve deterioration. The prosthetic heart valve most commonly used is the St. Jude Medical Prosthesis (St. Jude Medical, Inc., St. Paul, MN).⁷ Despite certain hemodynamic advantages in its design, two such prostheses had failed due to coagulation problems and another type of mechanical valve had been placed.

These patients must be maintained on anticoagulants. Coumarin anticoagulants (warfarin, dicumarol) are Vitamin K antagonists that interfere with the

gamma-carboxylation of vitamin K-dependent factors. (Table 1). The result is the production of nonfunctional factors II, VII, IX, and X. This effect is measured most readily by the PT.⁸

Table. Pharmacokinetic properties of coumarin derivatives

<i>Coumarin Derivatives</i>	<i>Half Life/ Days</i>	<i>Peak Activity/ Days</i>	<i>Duration/ Days</i>
Dicoumarol (bishydroxycoumarin)	1-2	3-5	2-10
Warfarin (Coumadin®)	1.5-2.5	1.5-3	2-5

PT values are commonly expressed as the ratio of the patient's actual PT (in seconds) to a control value that varies by laboratory. In an attempt to standardize PT values between laboratories and to establish an internationally recognized system, the INR was devised. The INR is the PT ratio (patient's PT/normal PT) that would have been obtained if the IRP 67/40 (an international reference thromboplastin type) was used. The INR is appropriate only for patients who are stably orally anticoagulated, having been on an oral anticoagulant for at least two weeks, with appropriate response to the drug and have reproducible PT results. It is used primarily for outpatients.

In a person with a PT within the normal range, the INR is approximately 1.0. In order to minimize thromboembolic problems with the mechanical tricuspid valve, our patient was maintained on doses of anticoagulant to keep the INR between 3.0 and 3.5. Dental treatment was not recommended unless the INR was ≤ 1.5 .

Using a classification introduced by Mulligan and Weitzel⁹ for pretreatment management of the patient receiving anticoagulants, the simple extractions required by this patient would be considered a moderate risk. The medical risk of our patient was high due to her history of thromboembolic complications with two previous prosthetic heart valves. Hospitalization of this type of patient is the accepted protocol.

Treatment under general anesthesia was indicated for our patient due to her:

1. History of combative behavior for dental treatment
2. Difficult logistics of presenting for multiple appointments from the family home 240 miles away
3. The cardiologist's preference for IV administration of antibiotics for SBE prophylaxis
4. Deep caries and multiple abscessed teeth indicated for expedient treatment
5. The need for hospitalization for modifying the anticoagulant regimen.

The dentist providing treatment determined that three maxillary primary molars had inadequate tooth structure remaining for appropriate restoration, so these teeth were extracted. A microfibrillar collagen hemostat (Avitene) was used in the extraction sites. This absorbable topical hemostatic agent attracts platelets that adhere to the fibrils and trigger aggregation of the platelets into thrombi.¹⁰ It is used as an adjunct to sutures and direct pressure for achieving hemostasis. Space maintenance was addressed at subsequent clinic appointments.

Persantine is used in addition to Coumarin anticoagulants to prevent postoperative thromboembolic complications of prosthetic heart valves. Platelet reactivity and interaction with prosthetic heart valves results in shortened platelet survival time; this may be a factor in thromboembolic complications with prosthetic heart valves.¹¹ Persantine lengthens abnormally shortened platelet survival times. The cardiologist treating our patient prescribed it to minimize the risk for thromboembolic complications during the time the anticoagulant was withdrawn.

Our patient was at very high risk for bacteremia-induced endocarditis. Her cardiologist recommended a parenteral prophylactic regimen. Clindamycin (10 mg/kg) and gentamicin (2 mg/kg) were given preoperatively to this penicillin-allergic patient. The parenteral regimen was repeated 8 hr after the initial dose. The cardiologist preferred the clindamycin and gentamicin combination over the standard parenteral administration of vancomycin to penicillin-allergic high-risk patients.

This patient does not require any alteration of anticoagulant medication for low-risk dental procedures such as supragingival prophylaxis. The patient continues to be followed as an outpatient in the dental clinic at Children's Hospital and Medical Center. If she re-

quires dental treatment with local anesthetic, her cardiologist will be contacted to discuss the need for alteration of anticoagulant levels.

Dr. Sheller is chief, education and resident training, Children's Hospital & Medical Center and affiliate assistant professor, departments of orthodontics and pediatric dentistry, University of Washington; and Dr. Tong is resident, department of hospital dentistry, University of Washington Medical Center, Seattle, Wash.

1. Taylor EJ, ED: *Dorland's Illustrated Medical Dictionary*, 27th Ed. Philadelphia: WB Saunders Co, 1988, p 92.
2. Fink BW: *Congenital Heart Disease*, 3rd Ed. St Louis: CV Mosby Co, 1991, pp 175-84.
3. Palareti G, Coccheri S, Poggi M, Bonetti M, Cervi V, Mazzuca A, Savoia M, Veri L, Fiori F, Gaspari G, Palareti A: Oral anticoagulant therapy control: evidence that INR expression improves the inter-laboratory comparability of results: the Bologna oral anticoagulant control exercise. *Thromb Haemostas* 58:905-10, 1987.
4. Mackie MJ, Douglas AS: *Drug-induced disorders of coagulation*. In *Disorders of Hemostasis*. OD Ratnoff, CD Forbes EDS. Philadelphia: WB Saunders Co, 1991, pp 495-96.
5. *Guidelines for the Elective Use of Conscious Sedation, Deep Sedation, and General Anesthesia in Pediatric Patients*. American Academy of Pediatric Dentistry Reference Manual 1992-1993, pp 41-3.
6. *Antibiotic Chemoprophylaxis for Pediatric Dental Patients at Risk*. American Academy of Pediatric Dentistry Reference Manual 1992-1993, pp 32-7.
7. Harada Y, Imai Y, Kurosawa H, Ishihara K, Kawada M, Fukuchi S: Ten-year follow up after valve replacement with the St. Jude Medical prosthesis in children. *J Thorac Cardiovasc Surg* 100:175-80, 1990.
8. Catalano P: Disorders of the coagulation mechanism. In *Internal Medicine for Dentistry*, 2nd Ed. Rose LF, Kaye D EDS. St Louis: CB Mosby Co, 1990, pp 358-59.
9. Mulligan R, Weitzel KG: Pretreatment management of the patient receiving anticoagulant drugs. *J Am Dent Assoc* 117:479-83, 1988.
10. Olin BR, ED. *Drug Facts and Comparisons*, 47th Ed. St Louis: Wolters Kluwer, 1993, pp 220-21.
11. Olin, BR ED. *Drug Facts and Comparisons*, 47th Ed. St Louis: Wolters Kluwer, 1993, pp 261-62.