



# Self-injurious behavior as a challenge for the dental practice: a case report

Daniela Rodrigues Silva, DDS    Márcio A. da Fonseca, DDS, MS

*Dr. Silva is a pediatric dentistry resident, University of Michigan School of Dentistry, Ann Arbor, Mich, and assistant clinical professor, Department of Preventive Dentistry, School of Dentistry of Anápolis, Goiás, Brazil; Dr. da Fonseca is associate professor, Department of Orthodontics and Pediatric Dentistry, University of Michigan School of Dentistry, Ann Arbor, Mich.*

*Correspond with Dr. Silva at silvad@umich.edu*

## Abstract

Patients who present self-injurious behavior (SIB) can be considered a treatment challenge in the dental office or hospital setting. Oral structures can play various roles in the process of self injury. In this paper, the authors report a case of SIB in the form of cheek-biting on an adolescent with a history of hydrocephalus and developmental delay, which was successfully treated with a modified standard maxillary orthodontic retainer. Early detection and intervention in SIB cases in patients with developmental disabilities influence the successful outcome of the therapeutic interventions, enhancing the patient's quality of life. (*Pediatr Dent.* 2003;25:62-66)

**KEYWORDS: SELF-INJURIOUS BEHAVIOR, SELF-INFLICTED ORAL INJURY, ORAL MUTILATION**

*Received April 15, 2002    Revision Accepted August 21, 2002*

The behavioral and biochemical aspects of self-injurious behavior (SIB) are poorly understood.<sup>1</sup> SIB can occur as an isolated action or as a recurrent phenomenon, as is often seen. The background is usually of a psychic nature, and mutilation is a result of mental conflicts and emotions such as hate, jealousy, frustration, feelings of inferiority, etc.<sup>1</sup> Several syndromes and congenital conditions have been associated with SIB, including Lesch-Nyhan syndrome, Cornelia de Lange syndrome, Tourette's syndrome, Rett syndrome, XXXXY syndrome, XYY syndrome, autism, and sensory neuropathies.<sup>1-5</sup> SIB may also be seen in prisoners.<sup>1</sup> Additionally, the patient's level of impairment is a factor predisposing the development of SIB. Pervasive developmental disorders, blindness, Down syndrome, and Rett syndrome seem to increase the likelihood for development of SIB above that of mental retardation alone.<sup>5,6</sup> Better understanding of the biobehavioral factors that potentiate the development of SIB may aid in the prospective determination of which children are at great risk.<sup>6,7</sup>

Although SIB may be culturally sanctioned or pathological, its essence is the deliberate destruction or alteration of body tissue without conscious suicidal intent. SIB occurs in numerous forms and in every degree ranging from

insignificant lesions to crippling injury. Major self-inflicted injuries are mostly related to patients presenting psychiatric disorders, and many include eye enucleation, facial skinning, and amputations of limbs, breasts, and genitals.<sup>8</sup> Moderate and mild self-injuries include skin cutting and burning, head banging, self-hitting and scratching, hair pulling and self-biting among patients who are under the care of nonpsychiatric physicians.<sup>5,8</sup> It is important to emphasize that the episodic SIB seen in patients with cerebral palsy, mental retardation, developmental delay, or epilepsy is quite different from that seen in comatose patients or those with Lesch-Nyhan syndrome.

The prevalence of SIB in the general population is not well established, but is estimated to be around 750 in 100,000.<sup>8</sup> Sewerin<sup>9</sup> conducted a study with 8,589 people attending a routine examination in a dental school and found 42 cases (0.5%) of mucosal/lip chewing. The most common injury was simultaneous biting of cheek and lip (62%). On the other hand, a study conducted in a specialized, interdisciplinary inpatient unit, where 83% of the patients presented with mental retardation, showed a higher prevalence of physical injury. Most patients (81%) were engaged in at least one type of SIB.<sup>5</sup> In a cohort study with 95 mentally retarded patients presenting severe SIB,

**Table 1. Screening Sequence to Determine the Motivation of SIB\***

Step 1	Step 2	Step 3
Screen for genetic abnormalities. Screen for nongenetic abnormalities (otitis). If screening is positive, motivation may be organic. If step 1 is negative, proceed to step 2.	Does SIB increase under different circumstances: when the behavior is attended to? when reinforcers are withdrawn? when the child is in the company of adults, rather than alone? If yes, motivation may be positive reinforcement. If step 2 is negative, proceed to step 3.	Does SIB occur primarily when there are no activities available and/or the environment is barren? If yes, motivation may be self-stimulation.

\*Adapted from Edward G. Carr, 1977.<sup>16</sup>

Emerson and coworkers showed that this behavior could be predicted in 76% of the patients after 7 years of follow up.<sup>7</sup> This accuracy was based on a combination of 3 variables: (1) SIB topography (head-directed self injuries), (2) age (younger), and (3) reported stability (greater) of SIB at the study's baseline.

Self-inflicted injuries are classified as neuropathological chewing when they are correlated with comatose or decerebrate patients.<sup>10-14</sup> It was first described by Guyton in 1966

as uncoordinated myotonic activity of selected masticatory muscles and tongue following neurological damage in comatose patients, in individuals with moderate to severe neurological impairment, and those with insensitivity to pain. The chewing movements produced are clenching spasms, biting, gnawing, and, less often, bruxing.<sup>5,15</sup>

It is desirable for dentists, especially pediatric dentists who treat patients with special health care needs, to understand a self-inflicted oral trauma condition and develop effective methods for managing it. A major consideration for a successful outcome is the recognition of the different motivation sources of SIB and the developmental relationships existing among these sources (Table 1).<sup>16</sup> Some authors have discussed "alternative" therapies involving relaxation and behavior modification techniques. Romer<sup>17</sup> presented a case of a child with severe mental retardation and chronic SIB who was resistant to dental intervention. After a few months of behavioral therapy techniques and therapeutic touch, the patient exhibited no self-mutilation behaviors. The goal of behavioral therapy is to extinguish and/or modify patterns of behavior that have a negative impact on a person's quality of life.<sup>18</sup>

The literature has few reports on cheek biting in conscious patients, mainly limited to conditions such as self-inflicted mutilation of the tongue and lips or neuropathological chewing in decerebrate and comatose patients (Table 2).<sup>4,10-15,19-28</sup> This clinical report describes the use of

a modified orthodontic appliance in a patient with bilateral thalamic venous angiomas, hydrocephalus, and developmental delay who was chewing his buccal mucosa.

### Case report

A 16-year-old Caucasian male was referred to a hospital dental clinic by his neurologist for evaluation and treatment of a cheek-biting habit which had started 10 months before. Previous attempts to solve the problem by other dentists had resulted in failure. The patient had a history of bilateral thalamic venous angiomas, hydrocephalus with ventriculoperitoneal (VP) shunt, significant developmental delay, and spasticity. In September 2001, he had an episode of brain hemorrhage which was treated successfully. He weighed 114 lbs and was

**Table 2. Literature Review of the Methods for Managing Self-inflicted Oral Trauma**

Author	Year	Condition of the patient	Appliance/management	Material
Hanson <sup>10</sup>	1975	Comatose	Tongue stent	Acrylic
Fenton <sup>14</sup>	1982	Comatose	Modified retainer (max)	Acrylic
Fabiano <sup>19</sup>	1984	Multiple sclerosis	Occlusal splint (mand)	Acrylic
Peters <sup>13</sup>	1984	Comatose	Fixed tongue stent	Acrylic + wire
Ngan et al <sup>12</sup>	1985	Comatose	Bite block Mouth prop	Acrylic Rubber and Molt
Croglio <sup>20</sup>	1990	Comatose	Mouthguard (mand)	Plastic
Sonnenberg <sup>21</sup>	1990	Cerebral palsy	Modified headgear	Acrylic + headgear
Sheller <sup>15</sup>	1992	Comatose	2 bite blocks connected	Rubber
Walker <sup>22</sup>	1992	Habitual cheek biting	Occlusal splint (max)	Acrylic
Willette <sup>23</sup>	1992	Mentally retarded	Lip shield	Polycaprolactone
Hallet <sup>11</sup>	1994	Comatose	Silver cap splint	Silver + acrylic
Chen <sup>4</sup>	1996	Lesch-Nyhan syndrome	Maxillary splint with headgear	Acrylic resin + headgear
Rashid <sup>24</sup>	1997	Lesch-Nyhan syndrome	Teeth extraction	
Saemundson <sup>25</sup>	1997	Neurological and seizure disorders	Modified removable lip bumper	Wire + acrylic
Kozai <sup>26</sup>	1998	Type 2 Gaucher	Tongue protection	Acrylic
Nurko <sup>27</sup>	1999	Chiari type II	Lip bumper	Wire + acrylic
Pigno <sup>28</sup>	2000	Macroglossia	Removable tongue protector	Acrylic

wheelchair bound, although his motor strength remained normal in both upper and lower extremities. His current medications included baclofen, olanzapine, fluvoxamine, and bupropion hydrochloride. He had no known drug allergies.

The extraoral examination showed dystonic posturing of the neck and a reduced ability to perform voluntary movements of the oral musculature. The intraoral examination revealed poor oral hygiene, permanent dentition with several carious lesions, Class I malocclusion with moderate crowding in both arches, normal overjet, and no overbite. Generalized plaque and gingivitis were evident. The right buccal mucosa presented a small healing wound while his left side had an open ulceration (Figure 1). Constant, uncontrolled biting of the soft tissues caused pain and interfered with normal eating and swallowing. Before his appointment in the clinic, he had been given an acrylic occlusal splint which broke due to his strong biting forces. On another trial, composite bulbs were added on to the buccal surfaces of all his maxillary premolars and molars, but the amount of composite was not enough to keep the soft tissue from being injured.

After a clinical examination and review of oral hygiene instructions with the patient and his mother, the composite bulbs were removed. Alginate impressions were obtained and a modified Hawley appliance was fabricated with lateral shields to protect the buccal mucosa (Figures 2 and 3). Primary retention was achieved via a labial bow and ball clasps. The shields and the bow were reinforced with extra solder and acrylic placed on the internal surface of the shields. The patient tolerated all appointments well, and despite his developmental delay was cooperative and pleasant. He adapted well to the device which is now removed only for oral hygiene and cleaning. The patient does not need to remove the appliance before eating. Wound healing was noticed after a few days of use (Figure 4). The patient continues to return to the clinic for regular dental care and appliance checks. In his last visit, the mother reported that he had not worn it for a full week and he had not bitten his mucosa. Although the appliance herein described can be worn indefinitely without any damage to the dentition and soft tissues, the authors hope that the habit will disappear and that only sporadic use will be necessary in the future.

## Discussion

The oral and dental management of patients with SIB is greatly influenced by their ability, even if limited, to make a conscious contribution to their own treatment. The overall health status of the patient must also be considered, including patient comprehension, diet, and ability for movement. Furthermore, several challenges need to be overcome before delivering an effective device to prevent self injury to the oral tissues. According to Hanson,<sup>9</sup> the appliances should be designed to:

1. reflect away from the occlusal table those tissues likely to be damaged by the involuntary movements of the mandible;

2. not be a potential source of further injury to the patient;
3. permit full range of mandibular motion;
4. permit daily oral care;
5. withstand breakage and displacement forces over an indefinite period of time;
6. allow healing of traumatized oral tissues;
7. be easily fabricated and installed without discomfort or risk to the patient.

A further challenge is the subsequent maintenance of the appliance because it will be the responsibility of the health care providers and those directly caring for the patient.<sup>20</sup>

The materials and design of an appropriate appliance should be selected after careful consideration of the cause of the condition. A review of the literature showed many different approaches to prevent self-inflicted oral trauma (Table 2).<sup>4,10-15,19-28</sup> The merits and shortcomings of each of these must be considered and basic criteria should be met for the appliance to be successful. The authors' device prevents cheek-biting trauma, promotes healing, allows patients to eat during use, and permits removal for oral hygiene. No guidelines dictate how long these appliances are needed. The one described herein can be worn indefinitely because function or tooth position are not impaired during its use. The authors' hope is that the appliance will lead to discontinuation of the habit after a period of time. The authors are encouraged because the patient showed no injury during the one week he did not wear it.

Today, health care providers are being consulted more often to treat patients with SIB, because patients with different levels of impairment are increasingly becoming part of the community. Thus, early detection and intervention in patients with developmental disabilities and SIB will favorably influence the outcome, thereby enhancing the patient's quality of life.

## Acknowledgements

The authors gratefully acknowledge Dr. Nick Palmer, adjunct assistant professor of pediatric dentistry, Department of Orthodontics and Pediatric Dentistry, University of Michigan, for his assistance with the appliance design.

## References

1. Winchel RM, Stanley M. Self-injurious behavior: a review of the behavior and biology of self-mutilation. *Am J Psychiatry*. 1991;148:306-316.
2. Lesch M, Nyhan WL. A familial disorder of uric acid metabolism and central nervous system function. *Am J Med*. 1964;36:561-570.
3. Nyhan WL. Behavior in the Lesch-Nyhan syndrome. *J Autism Child Schizop*. 1976;6:235-252.
4. Chen LR, Liu JF. Successful treatment of self-inflicted oral mutilation using an acrylic splint retained by a head gear. *Pediatr Dent*. 1996;18:408-410.

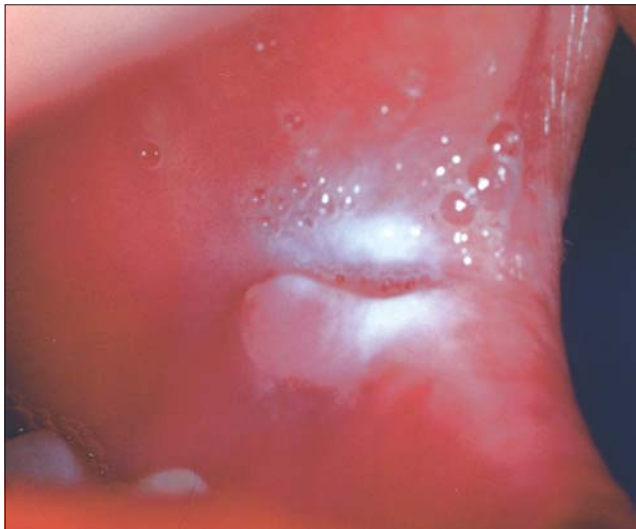


Figure 1. Lesion on the left buccal mucosa caused by SIB.

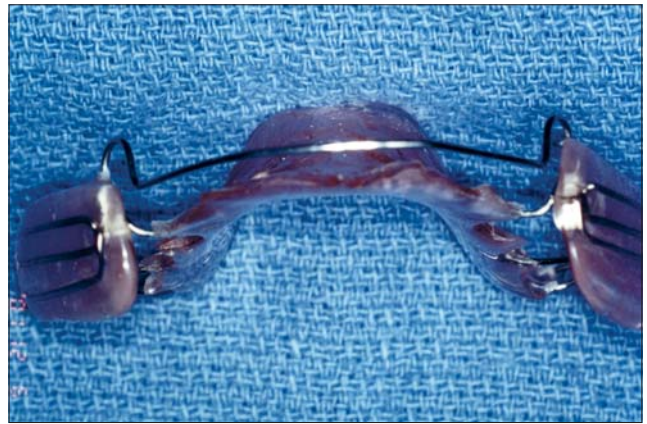


Figure 2. Modified Hawley with buccal shields.

5. Hyman SL, Fisher W, Mercugliano M, Cataldo MF. Children with self-injurious behavior. *Pediatrics*. 1990;85:437-441.
6. Murphy G, Hall S, Oliver C, Kissi-Debra R. Identification of early self-injurious behavior in young children with intellectual disability. *J Intellect Disabil Res*. 1999;43:149-163.
7. Emerson E, Kiernan C, Alborz A, Reeves D, Mason H, Swarbrick R, et al. Predicting the persistence of severe self-injurious behavior. *Res Develop Disabil*. 2001;22:67-75.
8. Favazza AR. Why patients mutilate themselves. *Hosp Commun Psych*. 1989;40:137-145.
9. Sewerin IB. A clinical and epidemiologic study morsicatio buccarum/labiorum. *Scand J Dent Res*. 1971;79:73-80.
10. Hanson GE, Ogle RG, Giron L. A tongue stent for prevention of oral trauma in the comatose patient. *Crit Care Med*. 1975;3:200-203.
11. Hallett KB. Neuropathological chewing: A dental management protocol and treatment appliances for pediatric patients. *Spec Care Dent*. 1994;14:61-64.
12. Ngan PWH, Nelson, LP. Neuropathologic chewing in comatose children. *Pediatr Dent*. 1985;7:302-306.
13. Peters TED, Blair AE, Freeman RG. Prevention of self-injurious trauma in comatose patients. *Oral Surg Oral Med Oral Pathol Oral Radiol Endod*. 1984;57:367-370.
14. Fenton SJ. Management of oral self-mutilation in neurologically impaired children. *Spec Care Dent*. 1982; 2:70-73.
15. Sheller B. Self-inflicted oral trauma: report of case. *Spec Care Dent*. 1992;12:28-29.
16. Carr EG. The motivation of self-injurious behavior: a review of some hypotheses. *Psychol Bull*. 1977; 84:800-816.

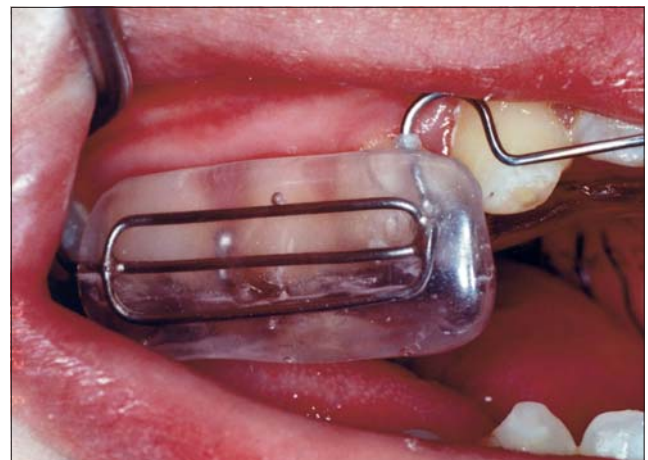

Figure 3. Lateral view of the appliance in the patient's mouth.

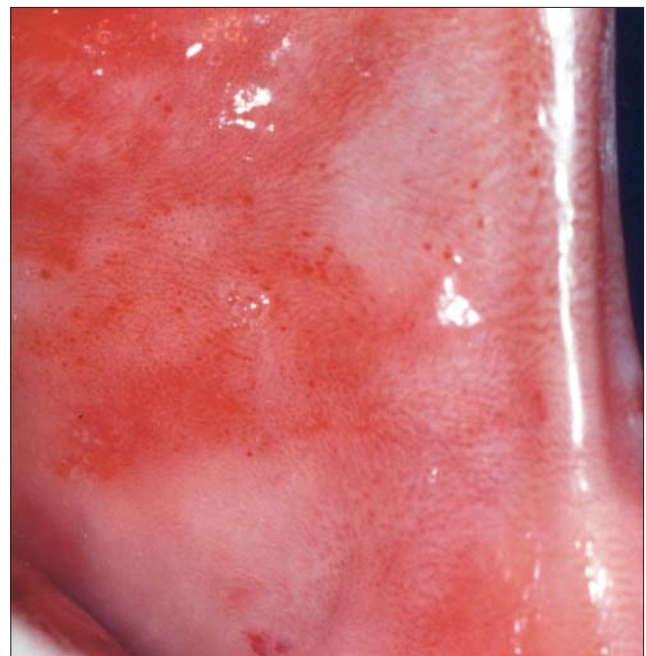


Figure 4. The wound is healed 28 days following insertion of the appliance.

17. Romer M, Dougherty N, Fruchter M. Alternative therapies in the treatment of oral self-injurious behavior: a case report. *Spec Care Dent.* 1998;18:66-69.
18. Gagne D, Toye RC. The effects of therapeutic and relaxation therapy in reducing anxiety. *Arch Psychiat Nurs.* 1994;8:184-189.
19. Fabiano JA, Thines TJ, Margarone JE. Management of self-inflicted oral trauma: report of case. *Spec Care Dent.* 1984;4:214-215.
20. Croglio DP, Thines TJ, Fleischer MS, Anders PL. Self-inflicted oral trauma: report of case. *Spec Care Dent.* 1990;13:58-61.
21. Sonnenberg, EM. Treatment of self-induced trauma in a patient with cerebral palsy. *Spec Care Dent.* 1990;13:89-90.
22. Walker RS, Rogers WA. Modified maxillary occlusal splint for prevention of cheek biting: A clinical report. *J Prosthet Dent.* 1992;67:581-582.
23. Willette JC. Lip-chewing: another treatment option. *Spec Care Dent.* 1992;12:174-176.
24. Rashid N, Yusuf H. Oral self-mutilation by a 17-month-old child with Lesch-Nyhan syndrome. *Int J Ped Dent.* 1997;7:115-117.
25. Saemundsson SR, Roberts MW. Oral self-injurious behavior in the developmentally disabled: Review and a case. *ASDC J Dent Child.* 1997;64:205-209.
26. Kozai K, Okamoto M, Nagasaka N. New tongue protector to prevent decubital lingual ulcers caused by tongue thrust myoclonus. *ASDC J Dent Child.* 1998;65:474-477.
27. Nurko C, Errington BD, Taylor WB, Henry R. Lip biting in a patient with Chiari type II malformation: case report. *Pediatr Dent.* 1999;21:209-212.
28. Pigno MA, Funk JJ. Prevention of tongue biting with a removable oral device: a clinical report. *J Prosthet Dent.* 2000;83:508-510.

## ABSTRACT OF THE SCIENTIFIC LITERATURE



### USE OF TONSIL SIZE IN THE EVALUATION OF OBSTRUCTIVE SLEEP APNEA

Obstructive sleep apnea syndrome in children is characterized by recurrent events of partial or complete upper airway obstruction during sleep, resulting in disruption of normal ventilation and sleep patterns. The prevalence is approximately 2% to 4% of the pediatric population, and, although there are many causes, adenotonsillary hypertrophy remains the most common cause. The purpose of this study was to determine the extent to which tonsil size contributed to the severity of obstructive sleep apnea (OSA) in children and to assess the use of tonsillar-pharyngeal (TP) ratio in differentiating patients with different severity of OSA. Lateral neck films were obtained for 35 children referred for evaluation of OSA secondary to tonsillary hypertrophy. Tonsil size was determined by measuring the TP ratio on the radiographs, and the severity of OSA was assessed by overnight polysomnography. The severity of the sleep apnea was positively correlated with the TP ratio but the clinical tonsil size did not correlate with the severity of sleep apnea or the TP ratio. The authors concluded that, in a population of children with OSA, tonsillary hypertrophy as assessed by lateral neck films positively correlated with the severity of OSA, and the TP ratio has high sensitivity and specificity in predicting those with moderate/severe disease.

**Comments:** Pediatric dental practitioners may use the size of the tonsils as a factor to consider prior to utilizing sedative agents for dental treatment. It was interesting that the authors of this paper did not find the clinical tonsil size to correlate with the severity of sleep apnea although the TP ratio, found on lateral neck films, did. This study has a small sample size and is biased by population characteristics as these children were sent for evaluation of suspected sleep apnea. I do not think that the results of this study could be used to negate the clinical consideration of tonsillar size as a relative contraindication for conscious sedation. **DARB**

*Address correspondence to A.M. Li, Department of Pediatrics, The Chinese University of Hong Kong, Prince of Wales Hospital, Shatin, Hong Kong, SAR, China. albertmli@cuhk.edu.hk*

Li AM, Wong E, Kew J, Hui S, Fok TF. Use of tonsil size in the evaluation of obstructive sleep apnea. *Arch Dis Child.* 2002;87:156-159.

17 references