



Oral Ulcerations as a Sign of Crohn's Disease in a Pediatric Patient: A Case Report

Franci Stavropoulos, DDS Joseph Katz, DMD Marcio Guelmann, DDS Enrique Bimstein, DDS

Dr. Stavropoulos is assistant professor, Dr. Katz is professor, Department of Oral and Maxillofacial Surgery and Diagnostic Sciences, Dr. Guelmann is assistant professor and Dr. Bimstein is visiting professor, Department of Pediatric Dentistry,

College of Dentistry, University of Florida, Gainesville, Fla.

Correspond with Dr. Stavropoulos at fstavrop@dental.ufl.edu

Abstract

Crohn's disease is an inflammatory intestinal disease of unknown etiology. The disease primarily affects whites, with both sexes being affected equally. A genetic predisposition exists. Symptoms frequently present in the second to third decades of life, although they may present in the pediatric and/or geriatric populations. Oral lesions are significant as they are frequently reported to precede intestinal symptoms. Treatment of Crohn's disease is palliative, with a focus on remission. Pediatric and general dentists play a critical role in the early diagnosis of Crohn's disease. Evaluation of a pediatric patient with complaints of oral ulcerations, as well as gastrointestinal symptoms, fatigue, and/or weight loss requires prompt referral to a gastroenterologist for further evaluation for Crohn's disease. (*Pediatr Dent.* 2004;26:355-358)

KEYWORDS: CROHN'S DISEASE, ORAL ULCERATIONS

Received December 12, 2002 Revision Accepted May 8, 2003

Crohn's disease, an inflammatory and likely immunologically mediated disease of unknown etiology, falls under the rubric of the diagnosis of inflammatory bowel disease (IBD).^{1,2}

IBD no. 2666600 in the On Line Mendelian Inheritance in Man (OMIM) occurs more commonly in whites and Ashkenazi Jews.² It is considered a complex genetic trait, as inheritance may not follow any simple Mendelian model, but is linked to chromosomes 16p12 to q13.³ Crohn's disease is a chronic, inflammatory, intestinal process affecting any site along the gastrointestinal tract, from the mouth to the anus. Symptoms frequently begin in early adult life, and approximately 25% of the cases begin before the age of 25.⁴ Oral lesions are of significance, as they are reported to precede the intestinal symptoms in 30% to 60% of the cases.^{1,5-8} Oral manifestations of IBD may precede the onset of intestinal lesions by as much as a year or more.⁹

Oral manifestations of Crohn's disease include hypertrophy of the lips and gingival soft tissue swelling resembling fibrous hyperplasia from an ill-fitting denture, a cobblestone appearance of the buccal mucosa and palate, and deep, granulomatous-appearing ulcers. The ulcers may appear linear in nature within the vestibule. Polypoid "tag" lesions may be found on vestibular or retromolar mucosa. Aphthous ulcerations are also present clinically in

approximately 20% of patients with Crohn's disease, although this prevalence is not significantly higher than in the unaffected population.¹⁰ Polystomatitis vegetans or "snail track ulcerations" may also be present, which is a rare presentation of IBD.¹ Secondary changes and symptoms include stomatitis, which is present in less than 1% of patients with Crohn's disease, and may be caused by *Staphylococcus aureus*.¹

Histological features of oral lesions of Crohn's disease include nonnecrotizing granulomatous inflammation within the submucosal connective tissue. The oral ulcerations do not differ from the common aphthous lesions, clinically or histopathologically.¹ Therefore, early recognition of the oral lesions and their association with Crohn's disease is essential in obtaining a timely diagnosis, preventing complications, and improving the prognosis.

This case report discusses an adolescent male who presented with oral ulcerations, that led to the diagnosis of Crohn's disease.

Case report

A 15-year-old male presented to the Oral Medicine Clinic at the University of Florida College of Dentistry with a chief complaint of oral ulcerations and consequential dysphagia. The symptoms began approximately 4 months

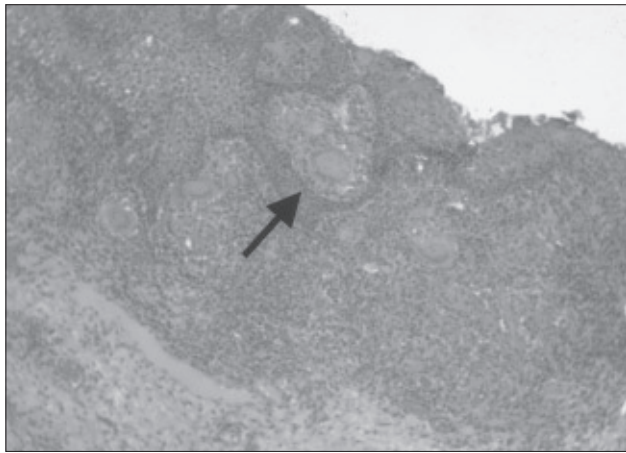


Figure 1. Photomicrograph of oral mucosal biopsy. Arrow points to epithelioid granuloma with giant cells. (Hematoxylin and eosin stain, original magnification $\times 10$).

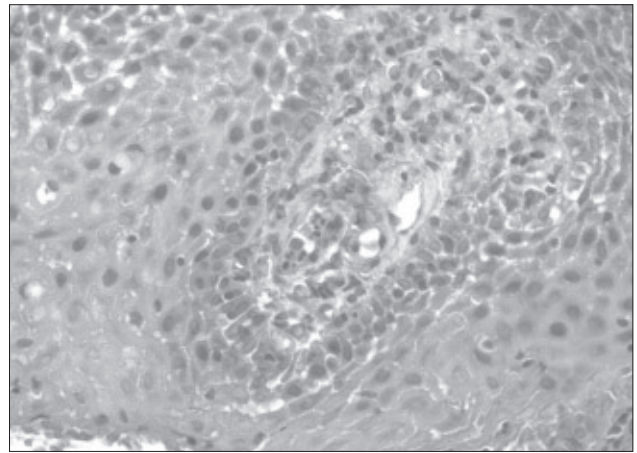


Figure 2. Photomicrograph of oral mucosal biopsy demonstrating eosinophilia. (Hematoxylin and eosin stain, original magnification $\times 40$).

earlier with continued ulcerations of about 2-week's duration each and associated soreness of his mouth. By report, the ulcerations were numerous, small, and healed over a 2-week period without scarring. In addition, he reported loose stools on a daily basis, a slightly elevated temperature, and weight loss of approximately 10 pounds. The patient had been seen by an otolaryngologist who had initially diagnosed the patient's signs and symptoms as a viral infection. His medical history was noncontributory, and he denied the use of medication. No allergies were reported. The clinical examination was significant for a pale, thin male of normal stature. Vital signs were normal. The head and neck examination was negative for masses, swelling, or lymphadenopathy. Intraorally, multiple minor aphthous-like lesions were present in the left mandibular buccal vestibule. Tissue tags and diffuse erythema were present on the frenum. The remaining intraoral examination was unremarkable without evidence of periodontal involvement.

The patient was referred for a routine serology work-up, which was normal except for an elevated C-reactive protein, an elevated erythrocyte sedimentation rate, and slight microcytic anemia. A working diagnosis of Crohn's disease was established. The patient was then referred to an oral and maxillofacial surgeon for a soft tissue biopsy and a pediatric gastroenterologist for an evaluation. The oral biopsy was remarkable for chronic granulomatous inflammation, acanthosis, eosinophilia, and intraepithelial abscesses (Figures 1 and 2). A chronic inflammatory infiltrate was present in the area surrounding the noncaseating granuloma, probably representing a host response. A colonoscopy was performed; endoscopic biopsy specimens were taken from the terminal ileum, cecum, and colon, which showed severe chronic active colitis.

A definitive diagnosis of Crohn's disease was obtained. The patient was started on oral mesalamine 800mg tid daily, an anti-inflammatory drug acting directly on the colon. He was also started on prednisone 50 mg daily for 4 weeks followed by a tapering dose to 20 mg daily. Within a week of

commencing drug therapy, the patient's oral and systemic symptoms improved. He reported decreasing episodes of loose stools and improvement in his symptom of dysphagia.

Discussion

The oral manifestations included recurrent oral ulcerations, tissue tags, and diffuse erythema over a 4- to 5-month period of time. Clinically, no mucosal scarring was evident. Unlike other case reports, periodontal involvement and geographic tongue did not exist in this patient nor did he complain of halitosis.^{6,8}

The incidence of Crohn's disease in the United States has increased over the past 30 years from 1 per 100,000 to as high as 10 per 100,000 individuals. Crohn's disease typically affects whites and individuals of Northern European descent. In the United States, whites are affected more frequently than blacks, Hispanics, and Asians, respectively.

The cause of Crohn's disease is unknown. However, a myriad of causative factors has been suggested including infectious, immunological, nutritional, and environmental. A genetic susceptibility exists based on elevated twin concordance rates and an increased frequency of Crohn's disease among first-degree relatives of affected patients.⁶ Both sexes are affected equally, and the disease may manifest itself at any age, although it is usually diagnosed by age 30. The elderly may also develop Crohn's disease.²

Signs and symptoms of Crohn's disease are variable and may exist in a subclinical state, making the diagnosis more difficult. Intermittent diarrhea, abdominal pain, cramping, nausea, fever, weight loss, and fatigue are common clinical findings. Abdominal pain associated with cramps is the most common initial complaint. The abdominal pain is described as periumbilical as opposed to lower abdominal pain. The latter is the location for the pain of ulcerative colitis, an intestinal disorder also described under the rubric of IBD.³ Malnutrition may occur, a consequence of similar intestinal malabsorption processes, leading to anemia, decreased growth, and a short stature.¹

The inflammatory process consists of noncaseating granulomas within the intestines, and is transmural in nature. It is more frequently located in the terminal ileum. The lesions are distinct from those seen in ulcerative colitis in that they are discontinuous, with areas of uninvolved normal bowel between diseased bowel segments.²

Extra-intestinal manifestations are reported to include nutritional abnormalities, hematologic abnormalities, skin manifestations, arthritis, uveitis, hepatic and renal abnormalities, and miscellaneous complications that include osteoporosis and thrombophlebitis.²

The diagnosis of Crohn's disease is obtained utilizing barium-enhanced imaging studies of the upper and lower gastrointestinal tract followed by a sigmoidoscopy or colonoscopy with biopsy. The extent of the disease is evaluated by either Crohn's disease activity index (CDAI),⁷ an index based on various clinical signs and symptoms within a week of the clinical evaluation, or by an activity-time index (ATI), a more comprehensive method that evaluates the cumulative duration of the active disease divided by the duration of follow-up, up to 3 years.⁹

Granulomatous and autoimmune-like changes in minor salivary glands, reduced salivation, halitosis, dental erosion secondary to vomiting,odynophagia, and dysphagia have all been reported. Katz et al⁹ reported a statistically significant higher incidence of dry mouth, nausea, and vomiting in patients with Crohn's disease in a high ATI group compared to nonaffected individuals. Moreover, a trend for a higher prevalence of those manifestations was seen in affected individuals with a low or moderate ATI of Crohn's disease.⁹

While periodontopathic bacteria are essential for the development of periodontitis, a susceptible host is also required for the development of periodontal diseases.^{12,13} Due to possible genetic factors causing a compromised immune system in patients diagnosed with Crohn's disease, the appearance of periodontal disease is not surprising. In fact, periodontal disease has been related to Crohn's disease.¹⁴⁻¹⁵ Bimstein et al reported on extended kindred affected with periodontitis.¹⁶ Several children and cousins were diagnosed with various degrees of periodontitis, with 1 parent diagnosed with Crohn's disease, further suggesting a possible relation between Crohn's disease and periodontal disease. Furthermore, since Crohn's disease may exist in a subclinical state, the presence of gingival and periodontal abnormalities may lead to its early diagnosis.

Histologically, tissue from the oral cavity and intestines exhibit nonnecrotizing granulomatous inflammatory changes within the submucosal connective tissue. The severity of the inflammation may vary from site to site and patient to patient.¹ Because of the depth of the noncaseating granulomas within the oral mucosa, a superficial incisional biopsy may be of little diagnostic value.

As previously mentioned, approximately 25% of Crohn's disease cases begin before the age of 25 and may even present in infancy and young children.^{3,17,18} Failure to thrive at the time of presentation, linear growth failure,

and colonic and perianal disease are reported to be the most common presenting clinical findings in young children diagnosed with Crohn's disease. In addition, common presenting symptoms include diarrhea, abdominal pain, vomiting, and chronic fever.^{17,18} Therefore, any adolescent or teenager presenting with complaints of chronic fatigue, persisting growth problems, fever, and oral ulcerations, should be evaluated for Crohn's disease.

No specific cure for Crohn's disease exists and symptomatic relief is the goal of therapy. Treatment includes the use of antidiarrheal/antispasmodic agents, topical steroids for oral lesions, systemic antibiotics, systemic steroids, and immunosuppressive drugs such as azathioprine. Surgery is reserved for severe cases exhibiting bowel obstruction, fistulae, or perforations.

Pediatric and general dentists play an important role in the early diagnosis of Crohn's disease. Awareness of the oral presentations of Crohn's disease, particularly as one of the first presenting signs of the disease, should alert the clinician to pursue an underlying systemic cause. Initial communication between the dental professional and a gastroenterologist is also paramount to an accurate and early diagnosis.

References

1. Oral Manifestations of Systemic Diseases. In: Neville BW, Damm DD, Allen CM, Bouquot JE, eds. *Oral and Maxillofacial Pathology*. 2nd ed. Philadelphia: WB Saunders Co; 2002:705-740.
2. Lacey SW, Richter JE, Wilcox CM. Inflammatory Bowel Disease. In: Andreoli T, Bennett J, Carpenter C, Plum F, Smith Jr L, eds. *Cecil Essentials Medicine*. 3rd ed. Philadelphia: WB Saunders Co; 1993:299-305.
3. Farmer M, Hunt L, Eichenberger MR, Petras RE, Janosky JE, Galandiuk S. Association of susceptibility locus for inflammatory bowel disease on chromosome 16 with both ulcerative colitis and Crohn's disease. *Dig Dis Sci*. 2001;46:632-636.
4. Boraz RA. Oral manifestations of Crohn disease: Update of the literature and report of a case. *J Dent Child*. 1988;55:72-74.
5. Plauth M, Henss H, Meyle J. Oral manifestations of Crohn's Disease: An analysis of 79 cases. *J Clin Gastroenterol*. 1991;13:29-37.
6. Rehberger A, Puspok A, Stallmeister R, Jurecka W, Wolf K. Crohn's disease masquerading as aphthous ulcers. *Eur J Dermatol*. 1998;8:274-276.
7. Kalmar J. Crohn's disease: Orofacial considerations and disease pathogenesis. *Periodontol 2000*. 1994;6:101-115.
8. Best WR, Bectel JM, Singleton JW, Dern F. Development of Crohn's disease activity index. *Gastroenterology*. 1976;70:439-444.
9. Katz J, Shenkman A, Stavropoulos F, Melzer E. Oral signs and symptoms and related manifestations in patients with inflammatory bowel disease. *Oral Dis*. 2003;9:34-40.

10. Siegel MA, Jacobson JJ. Inflammatory bowel disease and the oral cavity. *Oral Surg Oral Med Oral Pathol.* 1999;87:12-14.
11. Gagoh OK, Qureshi RM, Hendrickse MT. Recurrent buccal space abscesses. A complication of Crohn's disease. *Oral Surg Oral Med Oral Pathol.* 1999;88:33-36.
12. Ting M, Slots J. Microbiology of periodontal disease. In: Bimstein E, Needleman HL, Karimbux N, Van Dyke TE, eds. *Periodontal and Gingival Health and Diseases.* Children, adolescents, and young adults. London: Martin Dunitz, Ltd; 2001:169-187.
13. Hart TC. Genetic aspects of periodontal disease. In: Bimstein E, Needleman HL, Karimbux N, Van Dike TE, eds. *Periodontal and Gingival Health and Diseases.* Children, adolescents, and young adults. London: Martin Dunitz, Ltd; 2001:189-204.
14. Engel LD, Pasquinelli KL, Leona SA, Moncla BJ, Jielson KD, Rabinovitch PS. Abnormal lymphocyte profiles and leukotriene B4 status in a patient with Crohn's disease and severe periodontitis. *J Periodontol.* 1998;59:841-847.
15. Scheper HJ, Brand HS. Oral aspects of Crohn's disease. *Int Dent J.* 2002;52:163-172.
16. Bimstein E, Sela MN, Shapira L. Clinical and microbial considerations for the treatment of extended kindred with 7 cases of prepubertal periodontitis: A 2-year follow-up. *Pediatr Dent.* 1997;19:396-403.
17. Mamula P, Telega GW, Markowitz JE, Brown KA, Russo PA, Piccoli DA, Baldassano RN. Inflammatory bowel disease in children 5 years of age and younger. *Am J Gastroenterol.* 2002;97:2005-2010.
18. Marx G, Seidman EG, Martin SR, Deslandres C. Outcome of Crohn's disease diagnosed before 2 years of age. *J Pediatr.* 2002;140:470-473.

ABSTRACT OF THE SCIENTIFIC LITERATURE



ORAL HEALTH STATUS IN CHILDREN WITH CLEFT PALATE

Dental caries prevalence remains high in certain groups, including children with cleft palates. This study hypothesized that children with cleft palates would have increased oral clearance times for foods and, consequently, higher levels of caries and caries-associated micro-organisms than control children. Six- to 16-year-old children with (N=81) or without (N=61) cleft palates participated in this study. The children with cleft palates had significantly greater dmft/DMFT scores, poorer oral hygiene scores, greater plaque scores, greater gingival index, and longer oral clearance time. The number of caries-associated organisms was greater in the cleft palate children's saliva. The organic acid's concentration, however, were significantly greater in the control group, probably due to the altered physiology of the more mature dental biofilm. The results of this study support the hypothesis that children with cleft palates have greater levels of caries associated with the risk factors previously identified. Hence, caries-prevention programs in this group of children should be designed to address these risk factors.

Comments: This study demonstrated that children with cleft palate have particular difficulties and, therefore, are at higher risk for dental caries. **HA**

Address correspondence to David Beighton, Dental Caries Research Group, Guy's, King's, and St Thomas' Dental Institute, Caldecot Road, Denmark Hill, London, England. SE5 9RW. david.beighton@kcl.ac.uk

Ahluwalia M, Brailsford SR, Tarelli E, Gilbert SC, Clark DT, Barnard K, Beighton D. Dental caries, oral hygiene, and oral clearance in children with craniofacial disorders. *J Dent Res.* 2004;83:175-179.

25 references