



## Orthodontic alignment of permanent incisors following previous trauma of a primary tooth

Eli Tal, DMD Ari Kupietzky, DMD, MSc

*Dr. Tal is in private practice, Jerusalem, Israel; and Dr. Kupietzky is in private practice, Jerusalem, Israel, and a Diplomate of The American Board of Pediatric Dentistry.*

The primary aims of orthodontic treatment in the mixed dentition are to correct dental arch discrepancies, occlusal and jaw relation abnormalities, and to eliminate functional interferences<sup>1</sup>—in essence, preventive or interceptive orthodontics. Pediatric dentists should be trained and able to assist their patients if needed. Sequelae to trauma to primary incisors includes: defects in texture, malposition, or delayed eruption of the permanent successors.<sup>2</sup> This case report illustrates correction of rotated and ectopically erupting permanent incisors due to a discolored, over-retained, post-trauma primary central incisor.

### Case description

A seven-year old female patient was referred to a pediatric private practice from her general dentist, her primary dental caregiver. Her chief complaint was an over-retained upper primary incisor.

Clinical examination revealed a gray-colored, over-retained right primary central incisor with an ectopically positioned permanent central incisor erupting palatally, as demonstrated in a periapical radiograph (Fig 1). The patient had a mixed dentition with a Class I malocclusion: Class I molar relations, mesial-step second primary molars, and Class I canines. An anterior open bite with tongue thrust was noted. The primary

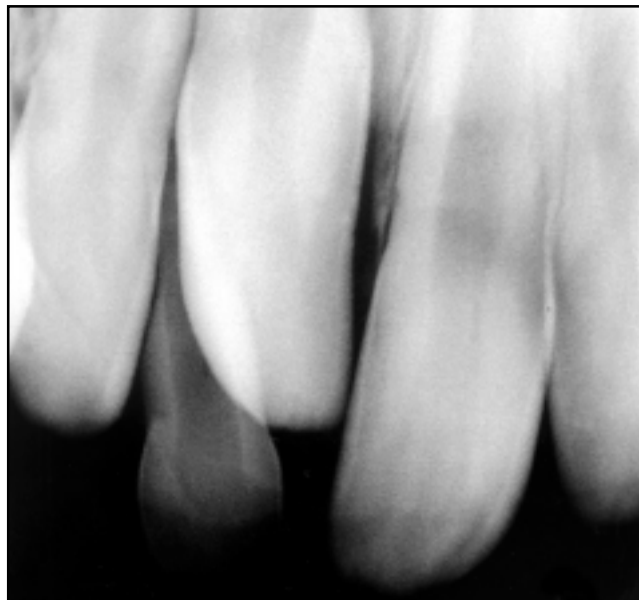


Fig 1. Periapical radiograph demonstrating retained primary central incisor and its ectopically positioned successor. Patient had previously reported trauma to the tooth, which had gray discoloration.

tooth was extracted and the patient was placed on a three-month recall.

Six months later at recall examination, all four incisors had erupted (Fig 2). The palatally placed central incisor had migrated labially but had a distal/palatal rotation of over 45 degrees. The right lateral also erupted rotated. Both patient and parent complained of the child's esthetically displeasing smile due to the malocclusion (Fig 3).

Treatment options were presented and discussed as follows:

1. Waiting for full comprehensive orthodontic treatment at approximately 12 years of age, following eruption of all permanent teeth. Until then the child will start myofunctional therapy to resolve the open bite due to tongue thrust, with or without a fixed tongue crib appliance; or
2. First phase orthodontic treatment with a fixed appliance with or without a tongue crib for a duration of approximately six months, to be followed with a retainer and myofunctional therapy.

The child and parent decided on the latter treatment option but refused to comply with a tongue crib. The limited goal of treatment was alignment of the incisors, thus improving the child's smile and self image. The open bite would be initially treated, following completion of phase one, with myofunctional therapy only. The limited goal of treatment and the probable possibility of the need for future, phase two orthodontic treatment, was emphasized. Also, the need for a retainer for a prolonged period of time to prevent relapse was understood by child and parent.

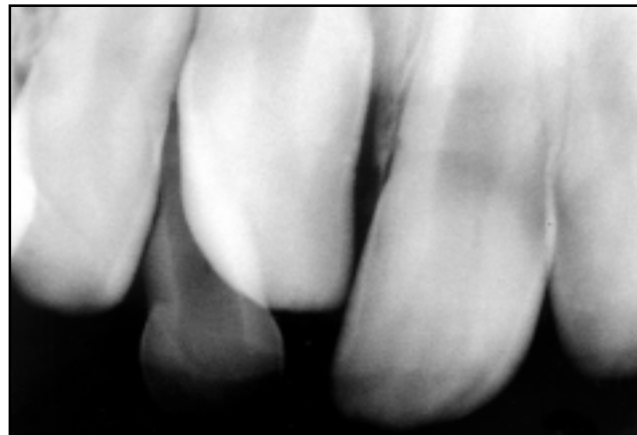


Fig 2. Six months following extraction of the primary incisor, the patient presented with severely rotated and malpositioned permanent upper incisors. Frontal view.

Received September 8, 1999 Revision Accepted December 22, 1999

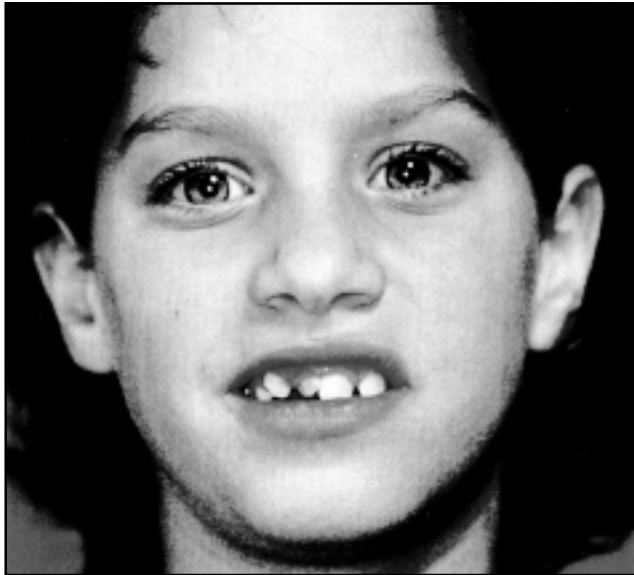

Fig 3. The patient's self-esteem and image were severely effected by her unesthetic appearance and smile.

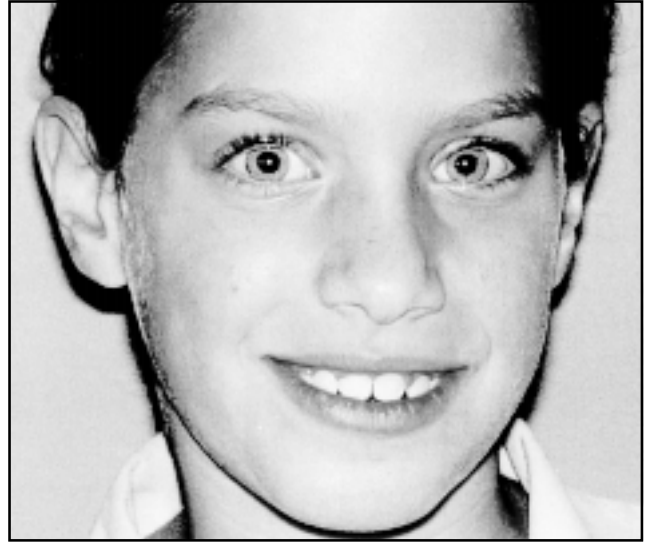

Fig 6. One year following commencement of treatment. Note the patient's improved smile and radiance. The limited treatment enhanced the child's self esteem and image.

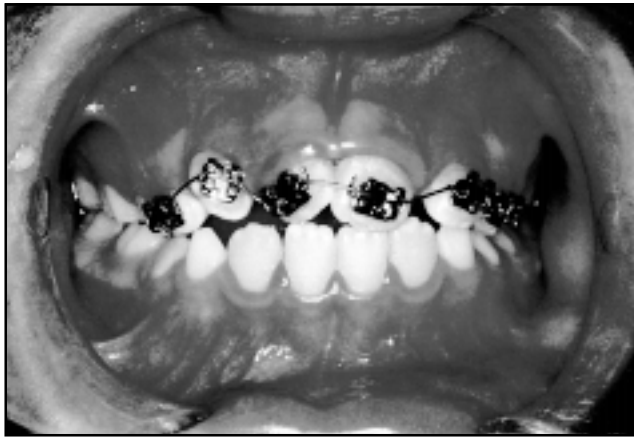

Fig 4. A .014 Ni Ti<sub>00</sub> nickel-titanium arch wire (Sybron Dental Specialties Inc., Orange, CA, USA) was placed and ligature ties were secured around all brackets. Frontal view.

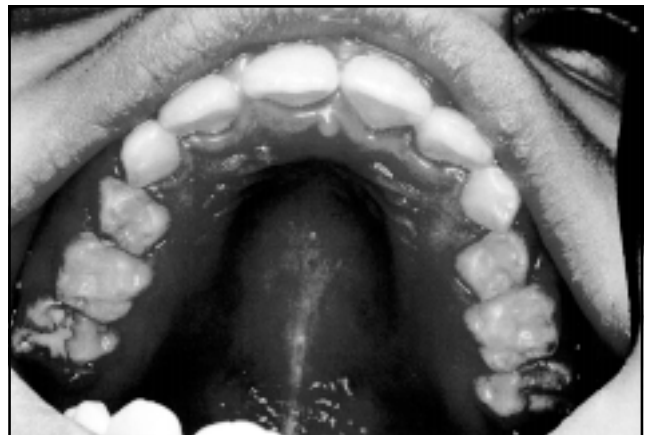

Fig 7. Occlusal view.

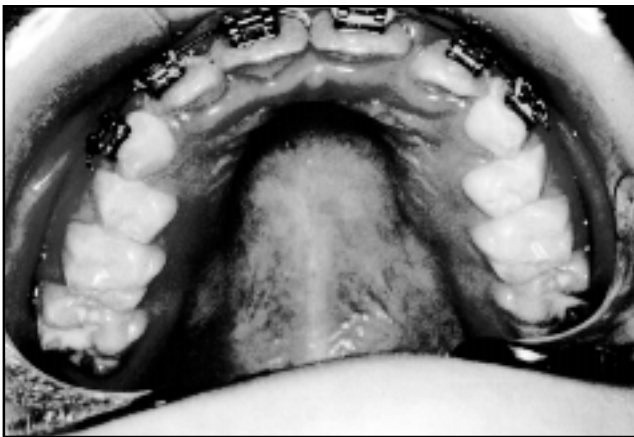

Fig 5. When the archwire was passive in all bracket slots, ligature ties were replaced with elastomers.

### Treatment

Ormco® Diamond™ pre-angulated orthodontic brackets (Sybron Dental Specialties Inc., Orange, CA, USA) were used. A segmental appliance was fabricated on primary canines and permanent centrals and laterals. A .014 Ni Ti™ nickel-titanium arch wire (Sybron Dental Specialties Inc., Orange, CA, USA) was placed and ligature ties were secured around all brackets (Fig 4). Wire progression advanced and after two months the wire was passive in all bracket slots (Fig 5). A .016 Ni Ti™ arch wire (Sybron Dental Specialties Inc., Orange, CA, USA) was placed with elastomeric ties. One month later a .016 stainless steel arch wire was placed. Three months later, brackets were removed and a retainer was given to the patient. The patient commenced speech therapy and was placed on recall (Fig 6 and 7).

### References

1. Fricker J, Jayasekera T: Orthodontic diagnosis and treatment in the mixed dentition. In *Handbook of Pediatric Dentistry*, 1st Ed. Cameron A, Widman R EDS. London: Mosby-Wolfe, 1997, pp 267.
2. Wilson CFG: Management of trauma to primary and developing teeth. *Dental Clinics of North America* 39:133-67, 1995