



A review of selected microstomia prevention appliances

Lincoln B. Taylor, BSc, DDS, MS Jerry Walker, BS, DDS, MA

Abstract

Perioral burns may occur due to electrical, thermal, or chemical agents. The resultant contracture of the facial tissue during healing causes limited oral access, compromised esthetics, and other related problems. This article presents various microstomia prevention appliances used by dentists and hospital burn centers. These appliances reflect different treatment concerns, ease of fabrication, age appropriateness, and cost effectiveness. An understanding of these factors and available appliances will aid the clinician in selecting or developing the best appliance for burn patients. (Pediatr Dent 19:413–18, 1997)

Facial burns can occur as a result of electrical, thermal, or chemical injury.¹ Burns of the face may involve the oral cavity, and if left untreated, result in microstomia. Perioral facial burns may be either partial or full thickness, which upon healing can cause tissue scarring and contraction² due to sphincter action of the orbicularis oris muscle.³ Contraction can interfere with vocalization, facial expression, eating, oral hygiene, dental care, and in children may affect the development of facial structures if proper treatment is not instituted immediately.² The literature has demonstrated that burn contractures and scar formation can be modified with pressure and splinting.^{4,5} If early splint therapy is not provided, the resultant contracture, will require later surgical reconstruction. The reconstruction involves linear release of the scar band with lateral advancement of the orbicularis oris muscle, recreation of modiolus labii, and reestablishment of vermilion continuity.⁶ A conservative appliance–therapy approach with no surgical consideration for approximately 1 year is considered to be the best approach. This literature review presents various treatment appliances and the conditions required for their success.

Etiology and characteristic

The common scenario leading to oral electrical burns involves preschool-age children chewing or sucking on live electrical wires.⁷ There are two types of electrical burns, arc and contact. In an arc burn, the saliva, tis-

ues, and the live wire make a complete circuit, generating heat from 2500–3000°C.⁸ In a contact burn, the electrical current passes through the body along the path of least resistance from the point of contact to the ground or exit site.

The initial appearance of the electrical burn of the commissure is a grayish-white, coagulated lesion outline with a rim of erythematous tissue.⁹ Two to 4 weeks later the eschar sloughs, leaving an ulceration. The tissue is replaced by collagenous fibrous connective tissue. It takes up to 1 year for the postburn scar to become stable due to the sphincter action of the orbicularis oris muscle.

The burn is usually painless, and drooling of food and saliva occurs because of destruction of the sensory innervation of the lip. Bleeding may occur at the time of injury or secondary to vacuolation of the vascular endothelium due to rupture of the labial artery and vessel walls during the necrosis stage of healing.^{7,8}

Dental dysplasia and malocclusion may occur depending on the severity, timing, and site of injury. The lip contracture in young children may cause lingual inclination and crowding of the teeth resulting in anterior crossbite or overbite.^{8,10}

Management

General

Although systemic complications occur infrequently, the patient should be evaluated for such problems as dehydration, hypothermia, shock, and cardiac arrhythmia.⁸ Tetanus prevention is recommended, as is prophylactic antibiotic therapy for the severely burned patient.^{8,10–12} Topical antibiotic may be used in the presence of secondary wound infection.⁸ It is thought that oral wounds do not benefit from prophylactic systemic antibiotic therapy and when applied topically, these agents have soothing effect rather than any antibacterial action.¹³

Daily home care with saline or hydrogen peroxide rinses and swabs may be used to debride the necrotic tissue and promote formation of healthy granulation tissue.⁸ Placement of a splint should be within 10–14 days of the initial injury to allow for proper approximation of the lip dimension before substantial healing has begun.

TABLE. THE CLINICAL CHARACTERISTIC OF MICROSTOMIA PREVENTION APPLIANCES

Type (A;P;AP)	Appliance Description, Fabrication, and Placement	Impression Necessary for Cast	Measurement Needed	Advantages	Disadvantages
Intraoral Maxillary Full ⁸ (P)	Full acrylic coverage with vestibular extension and acrylic covered wire post for commisure support	Yes	N/A	None	Poor compliance with pre-choolers Monitor erupting teeth
Mandibular Full ¹⁹ (P)	Full acrylic coverage with vestibular extension and acrylic covered wire post for commisure support	Yes	N/A	None	Poor compliance with preschoolers Monitor erupting teeth
Crown ¹⁸ (P)	Metal crown adapted on upper central incisor and 1st or 2nd primary molars. Avoid tooth preparation. Labial archwire soldered to crowns and acrylic post for the commissures.	Yes	Yes	Reduces compliance problems in pre-schoolers	None
Over-denture (P)	Same as above (Crown) but with acrylic overdenture with projecting post for commissures	Yes	Yes	Reduces compliance problems in pre-schoolers	None
Modified Hawley retainer ¹⁵ (P)	Upper Hawley retainer: Adams clasps on the primary 2nd molars and a labial bow from cuspid to cuspid. Two 0.036 extends labially to form acrylic-covered post. Occlusal anterior bite plane.	Yes	Yes	Minimal acrylic thus speaking and eating not affected Good retention	Limited to older children Monitor erupting teeth
Reverse Head-gear ¹⁵ (A/P)	A reverse headgear fitted to the face. Left and right outer bows of the headgear were reshaped to the commissures and covered with acrylic. This is positioned and shaped to maintain the lips at equidistance.	No	Yes	Parental and infant cooperation Easy insertion and removal	None
Poly-vinyl intra ¹ (A/P)	Polyvinyl stents made from mouthguards blanks. Each is 3 mm thick at mucogingival junction, and enlarging towards incisal/occlusal table (8 mm).	Yes	Yes	Easy insertion and removal No intraoral/ commissural ulceration	None
Extraoral Supported MPA2 (A/P)	Prefabricated: consists of 2 acrylic sections (fits into mouth commissures) joined by an adjustable stainless-steel bar with thumbscrew closure (2-mm increments). Available: S, M, L, and XL 3.8–9.0 cm for accommodation	No	Yes	Easy insertion and removal Prefabricated thus immediate delivery Range of sizes Slow expansile force	Potentiate tissue breakdown with excessive force Poor salivary retention

Acrylic holder ²¹ (A)	The commissure is adapted with wax; the wax is invested in flask for boil-out. The wax is replaced with heat curing resin. Angle of bent wire is adjusted so that forces are applied distally and parallel to facial contour. The 2 acrylic commissures are adapted to an Ω -steel wire self-curing resin	No	Yes	Easy insertion and removal with finger pressure, no lubrication required	None
Vancouver orthosis ¹⁴ (A/P)	U-shaped Kirschner wire is covered with thermoplastic. The flat ends of the thermoplastic are heated for attachment of the commissural ends, angled at 140° upwards and 160° backwards with respect to the wire spring. By the varying length of static wire bar, placed inside the U-wire, the desired pressure may be applied to the commissure.	No	Yes	Inexpensive material Slow expansile force Easy insertion/ removal	Limited to older children
Hyrax	Consists of 2 acrylic phalanges (fits into mouth commissures) between which is a Hyrax screw. Allows incremental expansion: 0.25 mm	No	No	Easy insertion/ removal Slow expansile force	None

A—Active P—Passive A/P—Utilized active or passive as needed

Commissure appliances

Numerous appliances have been used to manage oral burns. Selection of an appropriate microstomia-prevention device for a patient should be based on age, the presence or absence of teeth, condition of the dentition, type and extent of injury, patient's ability to comply with the regimen of use, comfort, cosmetics, durability, expense, complexity of fabrication, and need for repair and readjustment.¹⁴

There are two basic appliance types, tooth supported and tissue supported.¹⁵ Often, the tissue-supported appliances are indicated for infants who have few teeth, low tolerance for pain or discomfort, and lack the ability to understand the need for the appliance. Tooth-supported appliances may be designed for similar concerns but can either be further designated as removable or fixed. Another method for categorizing these labial commissure devices are passive stents and dynamic widening devices. The passive stent is applied for immediate (early) burn treatment while the dynamic device is for a delayed treatment situation where contracture of the commissure had already begun. This report will be presented according to support location: intraoral- and extraoral-supported appliances. The clinical characteristics of the appliances are summarized in Table 1.

Intraoral appliances

Most electrical burns of the mouth occur in children

aged 2 years or younger.^{16,17} At this age, the child has an incomplete primary dentition and is in the active stage of tooth eruption. Retention of an appliance can be a significant problem. Fig 1 is an example of a maxillary full-coverage acrylic denture base with posterior palatal seal and two .032-in wires extending from the

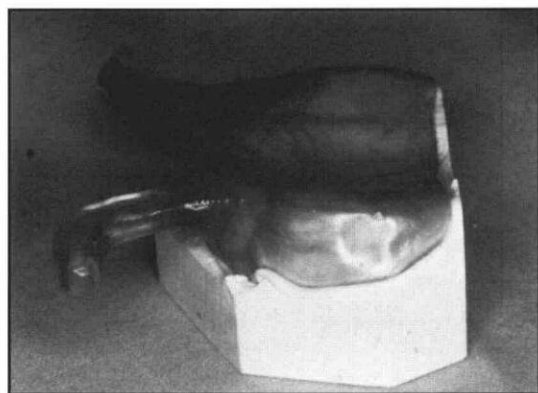


Figure 1. The maxillary full coverage denture base with posterior palatal seal.

base.⁸ The posterior palatal seal and vestibular extension provide its retention. The disadvantage as stated by Port et al.⁸ is the need for elbow restraints until the child accepts the appliance.

In a response to this report, Silverglade¹⁸ claims a

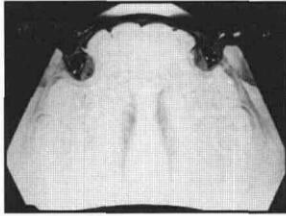


Figure 2a. The stainless steel crown fixed cemented appliance with anterior retention.

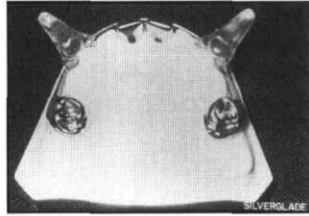


Figure 2b. The stainless steel crown fixed cemented appliance with anterior and posterior retention. (Courtesy of Silverglade)

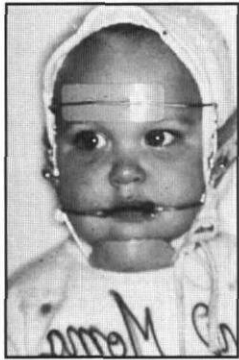

Figure 3. The modified reverse headgear. (Courtesy of P.E. Schneider)

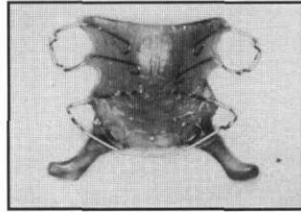


Figure 4. Modified Hawley Removable Retainer appliance (Courtesy of T.H. Larson).

high success rate using a stainless-steel crown, fixed, cemented appliance. The appliance consists of metallic crowns, orthodontic wire, and cold-cured acrylic. In situations where there are no erupted posterior teeth, a fixed overdenture type of splint may be considered with metal crowns on the anterior teeth (incisors can be surgically exposed). No preparation of the teeth is required in the presence of interproximal spacing. In the direct technique, an impression is obtained, the crowns are removed and then placed in the impression material. The working model with the crowns is produced for the acrylic adaptation. A labial arch wire is soldered to the stainless-steel crowns and enclosed in acrylic resin. The fixed appliance, if not adapted or cemented adequately, may be removed by the child. The effectiveness of this fixed appliance is dependent on the child's compliance and the skill of the dentist.

Fig 2 depicts another type of metal-crown, fixed appliance. Only the cuspids are utilized for retention. Silverglade, however prefers the use of the crowned central incisor and the first or second molars for improved retention. Mandibular retention has been considered by other authors. A mandibular acrylic splint with an extended, unilateral, ovoid, acrylic post to the affected side was used to maintain the burned oral commissure of a 16-month-old boy.¹⁹ The splint covered the mandibular arch, except for the primary dentition, and extended in the vestibule. The appliance may be fabricated as the previous maxillary appliance, except that the smaller central incisor is used, which offers less retention. Retention of the appliance may

be a problem with subsequent lack of compliance. It appears to require a greater ability of the wearer to adequately control the appliance from being dislodged by the tongue during oral function (speech and mastication).

Another removable appliance is the modified reverse-pull headgear (Fig 3). Schneider¹⁵ used a reverse-pull headgear modified to retain the lip commissure in a 9-month-old male infant with an electrical burn. The reverse headgear is normally used to manage skeletal maxillary retrusion as a positive-pressure appliance, and was modified to avoid any orthopedic or orthodontic results. The outer bows were reshaped to the commissures with acrylic adaptation.

The modified Hawley removable retainer appliance (Fig 4) offers a good alternative for the older, compliant patient with posterior teeth.²⁰ The basic design is that of a maxillary Hawley retainer with Adams clasps on the deciduous second molars and a labial bow extending from cuspid to cuspid. Two 0.036-in wires are incorporated into the palatal acrylic and extended labially to form an acrylic, covered post for commissural support. The appliance is fabricated on a cast with consideration for appropriate placement of the post based on commissure measurement. An anterior, acrylic, occlusal, bite plane may be placed for additional support to the post to minimize flexure and to allow mandibular function without occlusal interferences. The advantages consist of good retention, minimal bulk of acrylic, and excellent support for the acrylic, commissure-splinting posts. The minimal bulk of acrylic helps the patient to speak and function normally.²⁰ The only disadvantage, as with most removable appliances, is the patient's willingness to wear it as instructed.

Compliance may be a problem for the patient, despite age or level of understanding, because of the intense pain associated with appliance use, thus other treatment methods may be sought, depending on the situation. In a case report by MacMillan et al.,¹ a 21-year-old female with self-induced petrol burn was treated for perioral stricture incorporating a polyvinyl, intraoral splint. The patient was initially treated with an orthodontic headgear strap with cervical and acrylic retractors for each commissure. The device was poorly worn due to commissure ulcerations with resultant abandonment. After 10 weeks the patient returned with limited oral opening (lip separation of 20 mm). An active, polyvinyl, intraoral splint was fabricated and is shown in Figs 5a and 5b. The limited opening required sectioned, prefabricated, flexible, polyvinyl trays for impression of the dental arches. Each section was small enough to be inserted into the oral aperture. The combined sections were used to produce a cast for the fabrication of the polyvinyl microstomia appliance. The appliance was activated by progressively thickening (bulk) from the mucogingival junction the incisal/occlusal of the teeth. The patient wore this continually for 2 days and thereafter during sleep. Three months later, the patient's lip separation was 46 mm.

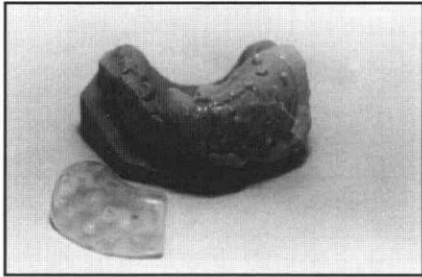


Figure 5a. Flexible Impression tray was made using polyvinyl mouthguard blanks and upper and lower study obtained from a randomly selected female patient. The polyvinyl moulds were sectioned into equal parts and perforated. Each sectioned was then used to obtain an alginate impression to produce the burn patient's study model. (Courtesy of A.R.G. MacMillan)

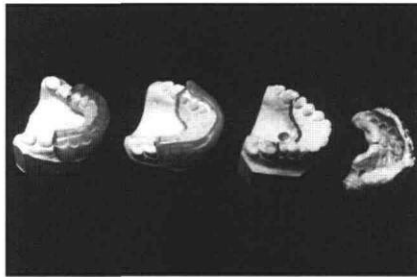


Figure 5b. The intraoral stents were processed using polyvinyl mouthguard blanks. The stents extended to the second premolar teeth and were 8 mm thick at the level of the incisal/occlusal table. (Courtesy of A.R.G. MacMillan)

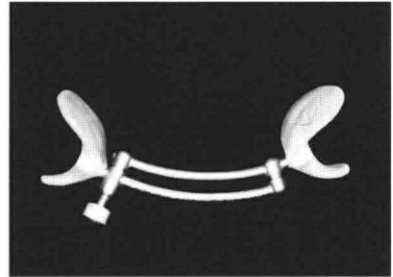


Figure 6. The microstomia prevention appliance with two acrylic sections. The arrow on the device is used for adjusting the appliance with respect to the patient's eye pupil.

Extraoral Appliances

Hartford and associates at the University of Iowa Hospitals and Clinics (UIHC) developed a microstomia prevention appliance (MPA, Fig 6, MPA Incorporation, Dallas, TX), which has been used since 1972.² The MPA consists of an adjustable stainless-steel bar with thumb-screw closure between two acrylic sections that fit around the oral commissures. The appliance is available in small, large, and extra large, ranging from 3.8 to 9.0 cm, each with 2-mm increments for a finer fit. The range is for accommodating mouths of small children to adults. The appliance may be used as an active or passive appliance. The acrylic section has an arrow demarcation to determine expansion. The expansion is based on the interpupillary width of the patient's eye, which corresponds to the commissure-to-commissure width. The device is removed only for oral care, eating, and visitations. The advantage of the appliance is its availability, immediate delivery, insertion and removal by patient or family member with minimal discomfort, and cost-effectiveness. The most common complaint is oral secretions because the lip borders are held apart.² As it is an active appliance, there is the potential for breakdown of viable tissue if too much pressure is applied. Madjar et al.²¹ presented a simplified, easily made widening device that consisted of two labial commissure acrylic holders connected with an omega-shaped stainless-steel wire. The device is fabricated using warmed base-plate wax cut to one-third the width of the commissure. The wax is then molded to the angle of the mouth labially and lingually. The wax is adjusted to increase the exit angle of the mouth. The wax patterns are flaked and replaced by heat-cured acrylic resin. The wire is adapted by autopolymerizing acrylic for anchorage to the labial commissures. The bent wire may be activated to accommodate expansile (lateral and distal) force on the lip commissures.

A similar device to the UIHC appliance is the Vancouver microstomia orthosis (VMO, Fig 7) which was

developed by the Vancouver General Hospital. This device is easily removed by the patient, inexpensive, uncomplicated in adjustment, requires no moulage for fabrication, and no anesthesia is necessary.¹⁴ The appliance can be fabricated in 30 min. The appliance is fabricated from Kirschner wire (10 cm length, 1.1 mm diameter) and a outrigger wire (3–5 cm length, 2 mm diameter). The Kirschner wire is bent into a U shape, based on the commissural distance, to form the spring portion of the appliance. The low thermoplastic material is adapted to both wires at 65–70°C. The encased outrigger wire is used to form the commissural piece which is then heated and adapted to the ends of encased U-shaped portion. The commissural portion is angled at 140° upward and 160° backward with respect to the wire spring. If a passive device is required, then holes 2 mm in diameter and 2–3 mm deep are drilled into both sides of the spring. A piece of outrigger wire is cut and fitted into the holes to act as a static bar and to maintain the desired pressure to the commissures. Without the bar, the device is dynamic. The device is inserted and removed without the bar. Horizontal pressure is altered by pulling the spring further apart. Pressure to the commissure may be altered by increasing or decreasing the bar length. Vertical opening of the mouth may be increased by increasing the size of the commissural opening. The advantages of the VMO appliance are that it does not require the presence of teeth, making a mold, expensive materials, or professional fabrication. Also, it applies graduated pressure in the horizontal and vertical directions. It is recommended for older children (> 2 years) if compliance is not a problem.

Another dynamic appliance is the individual mouth splint with a Hyrax screw (Dentaurum, West Germany) developed in Israel at Hebrew Univer-

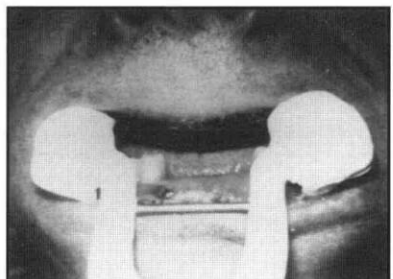


Figure 7. Static Vancouver microstomia orthosis in use.

sity-Hadassah School of Dental Medicine.²² An individual lip tray is used to obtain an impression from which a cast of the region of the lips is produced. The cast is used to fabricate the pink, acrylic-resin splint with a Hyrax screw. The horizontal splint provides an opening of 14 mm that may be achieved in 2 weeks, activating the screw only every other day, due to the pain experienced. The appliance is used as much as possible during resting periods.²²

Determining oral dimension

Although some authors did not provide information on oral or facial dimension for appliance delivery, the preburn commissural dimensions must be determined to achieve the most esthetic and functional results after healing.

Silverglade et al.²³ determines the post (tusk) placement from vertical and horizontal measurements. The vertical position is determined from the incisal edge of the maxillary central incisors in an imaginary line from commissure to commissure. The horizontal measurement is determined by measuring the distance from the unaffected commissures to the midline. If both commissures are involved, then the horizontal position is at the posterior embrasure of the canines. Another determinant in bilateral burns is the interpupillary width of the eye.

Conclusion

The use of MPAs in facial burns is the standard of care and definitely offers several advantages for the future. It eliminates or reduces the extent of surgical reconstruction needed. The appliance should restore function and esthetics, promote tissue healing, reduce scarring, improve symmetry, and maintain the size of the oral stoma.¹⁵ The use of any appliance is dependent on its availability, the clinician's knowledge, and the ability to fabricate the appliance. Compliance is the most important factor for determining the appropriateness of an appliance best suited for the patient. Appliance retention, compatibility with tissue-bearing areas, and comfort potentially solicit compliance.

Certain tissue-supported appliances are indicated for infants and children because of few teeth, low tolerance for discomfort, ease of insertion, and low expense. The tooth-supported appliances are best used in older, cooperative children because they can be stabilized intraorally and withstand oral contraction forces. The disadvantages for both appliances are patient compliance and adequacy in maintaining an optimal position to reduce complications caused by contractures. A more predictable outcome occurs with splinting for at least 6 to 8 months to facilitate scar maturation. Surgical reconstruction may then be determined after a 1-year follow-up.⁶

Dr. Taylor, was formerly assistant professor at the University of Tennessee, Dunn Dental Building, Department of Pediatric Dentistry, Memphis, Tennessee, and is in private practice in Oviedo, Florida. Dr. Walker is professor and clinical director at the University of Iowa, College of Dentistry, Department of Pediatric Dentistry, Iowa City, Iowa.

1. MacMillan AR, Oliver AJ, Richardson L, Reade PC: An intraoral splint for the prevention of microstomia from facial burns. *Burns* 17:72-74, 1991.
2. Heinle JA, Kealey GP, Cram AE, Hartford CE: The microstomia prevention appliance: 14 years of clinical experience. *J Burn Care Rehabil* 9:90-91, 1988.
3. Peacock EE Jr. *Wound Repair*, 3rd ed Philadelphia: WB Saunders Co, 1984, pp 445.
4. Evans EB, Larson DL, Abston S, Willis B: Prevention and correction of deformity after severe burns. *Surg Clin North Am* 50:1361-75, 1970.
5. Larson DL, Abston S, Evans EB, Dobrkovsky M, Linares HA: Techniques for decreasing scar formation and contractures in the burned patient. *J Trauma* 11:807-23, 1971.
6. Pensler JM, Rosenthal A: Reconstruction of the oral commissure after an electrical burn. *J Burn Care Rehab* 11:50-53, 1990.
7. Needleman HL, Berkowitz RJ: Electric trauma to the oral tissue of children. *ASDC J Dent Child* 41:19-22, 1974.
8. Port RM, Cooley RO: Treatment of electrical burns of the oral and perioral tissues in children. *J Am Dent Assoc* 112:352-54, 1986.
9. Ackerman AB, Goldfaden GL: Electrical burns of the mouth in children. *Arch Dermatol* 104:308-11, 1971.
10. Donly KJ, Nowak AJ: Oral electrical burns: etiology, manifestations, and treatment. *Gen Dent* 36:103-107, 1988.
11. Leake JE, Curtin JW: Electrical burns of the mouth in children. *Clin Plast Surg* 11:669-83, 1984.
12. Holt GR, Parel S, Richardson DS, Kittle PE: The prosthetic management of oral commissure burns. *Laryngoscope* 92:407-11, 1982.
13. Palin WE Jr, Sadove AM, Jones JE, Judson WF, Stambaugh HD: Oral electrical burns in a pediatric population. *J Oral Med* 42:17-21, 1987.
14. Conine TA, Carlow DL, Stevenson-Moore P: The Vancouver microstomia orthosis. *J Prosthet Dent* 61:476-83, 1989.
15. Schneider PE: Infant commissural burn management with reverse pull headgear. *Pediatr Dent* 10:34-38, 1988.
16. Thomson HG, Juckes AW, Farmer AW: Electrical burns to the mouth of children. *Plastic Reconstr Surg* 35:466-77, 1965.
17. Gifford GH Jr, Marty AT, MacCollum DW: The management of electrical mouth burns in children. *Pediatrics* 47:113-19, 1977.
18. Silverglade D: Fixed-cemented appliance for oral electrical burns [letter]. *J Am Dent Assoc* 112:806, 1986.
19. Salman RA, Glickman RS, Super S: Splint therapy for electrical burns of the oral commissure in children. *ASDC J Dent Child* 54:161-64, 1987.
20. Cooney BM: Conservative management of oral electrical burns: report of a case successfully treated. *Int J Orthod* 24:12-15, 1986.
21. Madjar D, Shifman A, Kusner W: Dynamic labial commissure widening device for the facial burn patient. *Quintessence Int* 18:361-63, 1987.
22. Sela M, Tubiana I: A mouth splint for severe burns of the head and neck. *J Prosthetic Dentistry* 62:679-81, 1989.
23. Silverglade D, Ruberg RL: Nonsurgical management of burns to the lips and commissures. *Clin Plast Surg* 13:87-94, 1986.