

Comparison of Proximal Caries Detection in Primary Teeth Between Laser Fluorescence and Bitewing Radiography

V. Virajsilp, DDS¹ A. Thearmontree, DDS, MSD, MPH, DrPH² D. Paiboonwarachat, DDS, MS³
S. Aryatawong, DDS, Dr Med Dent⁴

Abstract

Purpose: The purposes of this in vitro study were to: (1) compare the accuracy of a laser fluorescence system (DIAGNOdent) in proximal caries diagnosis in primary teeth with that of bitewing radiography, using the histological examination as a gold standard; and (2) evaluate the reliability of the DIAGNOdent examination.

Methods: Included were 107 extracted primary molars without obvious cavities on proximal surfaces. The teeth were examined by 2 examiners using DIAGNOdent directly on the lesions (without contact; ie, proximal surfaces were not in contact with other teeth) and indirectly (with contact; ie, proximal surfaces were in contact with adjacent teeth). To simulate contacting teeth, the studied surface was set adjacent to a sound surface in a wax base. The contacting teeth were also diagnosed using bitewing radiography. Results of the diagnoses were compared with a histological gold standard. Sensitivity and specificity were calculated for each diagnostic system. Inter- and intraexaminer reliabilities of DIAGNOdent were calculated using intraclass correlation (ICC).

Results: At the dentine caries (D₃) level, the sensitivities of bitewing radiography (with contacting teeth) and DIAGNOdent with and without contacting teeth (direct application) were 0.41, 0.85 and 0.93, respectively, and the specificities were 1, 0.89, and 0.87, respectively. Both inter- and intraexaminer reliabilities using DIAGNOdent with and without contacting teeth (direct application) were very high (ICC=0.97 to 0.99).

Conclusions: The reliability of DIAGNOdent is very high and its diagnostic validity (sum of sensitivity and specificity) is higher than that of bitewing radiography for proximal caries detection in primary teeth. (*Pediatr Dent* 2005;27:493-499)

KEYWORDS: PROXIMAL CARIES DETECTION, DIAGNOdent,
LASER FLUORESCENCE, PRIMARY TEETH

Received March 23, 2005 Revision Accepted September 23, 2005

Proximal caries detection in primary teeth is of great importance because of the rapid rate of caries progression and the difficulty in determining the presence or absence of a lesion. This is due to the peculiar morphologic characteristics of the primary tooth, which include less enamel and dentine thickness,¹ smaller degrees of mineralization,² and wider lumen of the dentinal tubule, compared to the permanent tooth.³ Difficulty in caries detection and rapid caries progression can also be due to

the wide proximal contact area of a primary molar⁴ allowing greater accumulation of cariogenic microorganisms, which are responsible for initiation and progression of the disease.

Existing diagnostic techniques for proximal caries detection include visual examination, bitewing radiography, and fiber-optic transillumination. Although these methods offer relatively good diagnostic performances, they provide varying sensitivities for detecting proximal carious lesions (sensitivities ranging from 0.08 to 0.90).⁵⁻¹⁰ Moreover, bitewing radiography, which is the most common method used to diagnose proximal caries, also exposes the patient to a relatively high dose of ionizing radiation.⁷ Alternative methods to detect proximal caries are expected to overcome the disadvantages of these conventional methods.

The laser fluorescence method, DIAGNOdent (KaVo, Biberach, Germany), has been available for the detection

¹Dr. Virajsilp is a graduate student, ²Dr. Thearmontree is an instructor, Division of Community Dentistry, Department of Preventive Dentistry, ³Dr. Paiboonwarachat is an instructor, Division of Pediatric Dentistry, Department of Preventive Dentistry, and ⁴Dr. Aryatawong is assistant professor, Division of Radiology, Department of Stomatology, all in the Faculty of Dentistry, Prince of Songkla University, Songkhla, Thailand.
Correspond with Dr. Thearmontree at angkana.t@psu.ac.th

of caries since 1998. It works by generating laser light with a wavelength of 655 nm.¹¹ The laser light is absorbed by both organic and inorganic materials in the tooth and re-emitted as fluorescence within the infrared region, which can be analyzed and quantified. The system provides quantitative measures of caries lesions on a scale from 0 to 99. The caries process alters the amount of fluorescence, which is measured as an elevated reading where the higher the number, the deeper the lesion.¹²⁻¹⁴

DIAGNOdent's accuracy has been studied both in vitro and in vivo for occlusal caries in primary and permanent teeth.^{12,15-18} Recent studies indicate that DIAGNOdent could be applied for use on smooth surface caries and proximal caries of permanent teeth.^{13,14,19-22} The results of these studies show that DIAGNOdent is accurate and reproducible in caries detection. There has yet to be a published study, however, in which DIAGNOdent is used for detection of proximal caries in primary teeth. Therefore, the aims of this study were to:

1. compare, in vitro, DIAGNOdent's accuracy at detecting proximal caries in primary teeth to bitewing radiography's accuracy using the histological examination as a gold standard;
2. evaluate, in vitro, DIAGNOdent's reliability.

Methods

Prior to the experiment, 2 examiners standardized the diagnosis of proximal caries on 10 extracted primary molars using bitewing radiography, DIAGNOdent, and the histological examination with dentists who were experienced in each technique. The results show high agreement in both the bitewing radiograph and the histological examination ($\kappa=0.85$ and 0.86 , respectively). DIAGNOdent, meanwhile, had very high intra- and interexaminer reliabilities (intraclass correlation coefficient [ICC]= 0.97 and 0.98 , respectively).

Tooth selection

Selected were 107 extracted first and second primary molars without obvious cavities (intact or cavity ≤ 1 mm in diameter) on the studied proximal surfaces. The teeth had been extracted because of either excessive mobility caused by normal exfoliation or due to caries-exposed pulp on the nonstudied surfaces. They were stored in 0.9% normal saline solution no longer than 1 week before collection. All soft tissue and extrinsic deposits of the collected teeth were removed using a hand scaler and were polished using a rotating rubber cup and pumice. The teeth were then stored again in 0.9% normal saline solution.

Visual inspection of 107 proximal surfaces revealed that 36 teeth were sound (intact, hard, normal, or discolored surface), 30 had initial caries (intact, rough white, or discolored surface), 20 had enamel caries (loss of enamel or cavity limited to enamel), and 21 had dentine caries (cavity extended to the dentine or dark translucent lesion) (Table 1). The teeth were numbered, and the occlusal and studied proximal surfaces were photographed. These pho-

tographs were used to record the area that had the highest DIAGNOdent value.

DIAGNOdent examination without contacting teeth (direct application)

The teeth were retrieved from the normal saline solution and dried with compressed air for about 3 seconds. Before measurement of each individual tooth, the machine was standardized on a sound area of the tooth, usually on the tooth's buccal surface, following the manufacturers' guidelines (KaVo DIAGNOdent 2095). Then, DIAGNOdent was applied directly to the lesion on the tooth's proximal surface using probe A. The highest reading was recorded and the spot of highest reading was marked on the tooth's photograph. Two examiners examined the teeth independently without input from each other to test interexaminer reliability. The same procedures were repeated 1 week later by 1 examiner to test intraexaminer reliability.

DIAGNOdent examination with contacting teeth

Two teeth were mounted in a wax base with the proximal surfaces contacting each other. The DIAGNOdent with probe A was placed at the marginal ridge of the occlusal surface and at the buccal and the lingual embrasures of the contacting proximal surfaces by each of 2 examiners. The highest value from these positions was recorded. To determine intraexaminer reliability, 1 examiner repeated the procedure 1 week later.

Bitewing radiography

Bitewing radiographs were taken under standardized conditions. Kodak ultraspeed film (Eastman Kodak, Rochester, NY) was used with a bitewing holder. The Gendex GX-1000 dental x-ray machine (General Electric Company, Milwaukee, Wis) operated at 60 kV, 10 mA, and a 0.26-second exposure time was used with the beam aimed perpendicular to the tooth. The focus-to-film distance was 10 inches. The exposed films were processed automatically for 4.5 minutes at 25°C in a Dent-X processing machine (Dent-X, Elmsford, NY). Radiographic interpretations were made using a standard viewbox and Viewscope (Flow X-ray, West Hempstead, NY) at $\times 2$ magnification. The bitewing radiography was repeated when the radiograph had a defect such as overlapping. Criteria for radiographic interpretations were set according to Pitts (Table 2).²³

Histological examination

A line was drawn on the occlusal surface in the mesiodistal plane perpendicular to the marginal ridge through the spot on the proximal surface where the highest DIAGNOdent value from the direct application was read. The tooth was mounted in a clear resin using a silicone box leaving the occlusal surface uncovered. The tooth specimen was hemisectioned, perpendicular to the occlusal surface immediately adjacent to the line, with an Exakt cutting machine (EXAKT Apparatebau, Norderstedt, Germany). Then, the

extension of caries was determined under a stereomicroscope at $\times 25$ magnification. The caries level was scored according to the criteria given by Russel and Pitts (Table 2).⁷

Statistical analysis

The intraclass correlation coefficient (ICC) was computed to assess intra- and interexaminer reliabilities of DIAGNOdent. Spearman's rank correlation was used to evaluate the correlation between DIAGNOdent, bitewing radiography, and the histological examination, whereas the correlation between DIAGNOdent values with and without contacting teeth was computed using Pearson's correlation. To assess the validity of the bitewing radiography and DIAGNOdent examination, the sensitivity and specificity were calculated at the initial (D_1), enamel (D_2), and dentine (D_3) caries levels using the histological examination as a gold standard. At each caries level, the disease negative (sound) and disease positive (caries) were defined, respectively, as follows:

1. initial caries level (sound vs initial caries and higher or D_0 vs D_1, D_2, D_3);
2. enamel caries level (less than enamel caries vs enamel caries and higher or D_0, D_1 vs D_2, D_3);
3. dentine caries level (less than dentine caries vs dentine caries or D_0, D_1, D_2 vs D_3).

The receiver operating characteristic (ROC) curve was conducted to determine the optimal cutoff point which gives the best balance between sensitivity and specificity at each caries level.

The ethics committee of the Faculty of Dentistry, Prince of Songkla University, Songhklā, Thailand gave approval for this study.

Results

The teeth used in this study comprised 22 primary maxillary first molars (20%), 36 primary maxillary second molars (34%), 15 primary mandibular first molars (14%), and 34 primary mandibular second molar (32%). Table 1 illustrates that the bitewing radiography and histological examination resulted in differing distributions of caries occurrences in 3 of the 4 caries levels.

The intra- and interexamination reliabilities of DIAGNOdent in this study were very high. The intraexaminer

Table 1. The Distribution of Each Caries Level Using Direct Visual Examination, Bitewing Radiography, and Histological Examination

Level of carious lesion	No. of sample (%)		
	Visual	Bitewing radiography	Histological examination
0 (sound)	36 (34%)	46 (44%)	18 (17%)
1 (initial)	30 (28%)	21 (19%)	18 (17%)
2 (enamel)	20 (19%)	17 (16%)	17 (16%)
3 (dentine)	21 (19%)	17 (16%)	54 (50%)
Total	107 (100%)	107 (100%)	107 (100%)

Table 2. Scores, Associated Caries Levels, and Criteria for Diagnosis of Proximal Caries for Bitewing Radiography and Histological Examination

Methods	Score	Caries level*	Criteria
Bitewing radiography (Pitts, 1984)	R0	D_0	No radiolucency
	R1	D_1	Zone of increased radiolucency confined to the outer half of the enamel
	R2	D_2	Zone of increased radiolucency involving both inner and outer halves of the enamel layer, including lesion extending up to but not beyond the dentino-enamel junction
	R3	D_3	Zone of increased radiolucency penetrating the enamel and dentino-enamel junction and progressing into the dentine
Histological examination (Russel and Pitts, 1993)	H0	D_0	No caries apparent
	H1	D_1	Cariou lesions in outer half of enamel only
	H2	D_2	Cariou lesions into the inner half of the enamel but not into dentine (up to and including the dentino-enamel junction)
	H3	D_3	Cariou lesions through enamel and dentine

* D_0 =sound; D_1 =initial caries; D_2 =enamel caries; D_3 =dentine caries.

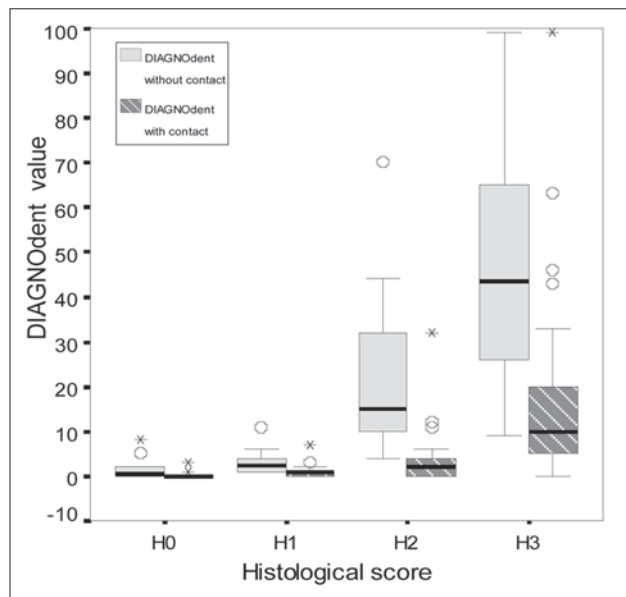


Figure 1. Box plot describing the relationship between the DIAGNOdent values and the histological examination of teeth without contact, compared to those with contact.

reliabilities measured by ICC were 0.99 for DIAGNOdent without contacting teeth and 0.97 with contacting teeth. The interexaminer reliabilities for DIAGNOdent without and with contacting teeth were 0.97 and 0.98 to 0.99, respectively.

DIAGNOdent values without contacting teeth were positively correlated with those with contacting teeth ($r=0.682$; $P<.01$). At all caries levels determined by the histological examination, the means of the DIAGNOdent values of teeth without contact were higher than those with contact (Figure 1). Spearman's rank correlation coefficient between the histological examination and DIAGNOdent values was higher than when the teeth were not in contact with adjacent teeth when they contacted teeth (Table 3).

Table 3. Spearman's Rank Correlations Among the Diagnostic Tests

Methods	Spearman's rank correlation coefficient (r)	P value
Histological examination vs DIAGNOdent without contacting teeth	0.849	<.01
Histological examination vs DIAGNOdent with contacting teeth	0.768	<.01
Histological examination vs bitewing radiography	0.793	<.01
DIAGNOdent without contacting teeth vs bitewing radiography	0.732	<.01
DIAGNOdent with contacting teeth vs bitewing radiography	0.711	<.01

The highest correlation coefficient between the histological examination and DIAGNOdent was found when the teeth were not in contact ($r=0.849$; $P<.01$).

ROC curves of DIAGNOdent without and with contacting teeth at the D_3 level are shown as examples in Figures 2 and 3. The cutoff values for proximal caries detection at the D_3 level were 4 and 16 for DIAGNOdent with and without contacting teeth, respectively. Table 4 presents the optimal cutoff values of DIAGNOdent with and without contacting teeth, with sensitivities and specificities for the 3 caries levels (D_1 , D_2 , and D_3). The results suggest that, at every caries level, bitewing radiography had the lowest sensitivity but the highest specificity. DIAGNOdent, however, resulted in higher validities (sum of sensitivity and specificity) than bitewing radiography at all caries levels.

Discussion

This study used the histological examination under stereomicroscope as a gold standard. This method was recommended as an appropriate gold standard, since it is precise and reproducible.²⁴ In the present study, the intra- and interexaminer reliabilities of DIAGNOdent were evaluated using intraclass correlation. The very high intraclass correlation coefficients confirmed the high reproducibility of DIAGNOdent on occlusal and smooth surface caries, as reported in previous studies.^{13,15,25-28}

The correlation between the DIAGNOdent values of the proximal surface without contacting teeth and those with contacting teeth were relatively high ($r=0.682$). It indicated that DIAGNOdent could be used for detection of proximal caries where there is a contacting tooth. This study showed that there were high correlation coefficients between the DIAGNOdent values (both with and without contacting teeth) and the histological examination ($r=0.849$ and 0.768 , respectively). These results were similar to the studies by Costa et al ($r=0.81$)²⁹ and Bamzahir et al ($r=0.93$),²⁶ in which occlusal caries in permanent teeth were examined.

The sensitivity at the D_3 level of bitewing radiography in this study (0.41) was lower than the sensitivities presented in previous studies (0.59 to 0.73).^{5,6} In addition, this study found that sensitivities at the D_1 and D_2 levels were higher than at the D_3 level. These results could be due to the fact that this study included only noncavitated teeth or teeth with no obvious cavity. The bitewing radiography had a high sensitivity for detecting cavitated surfaces but a low ca-

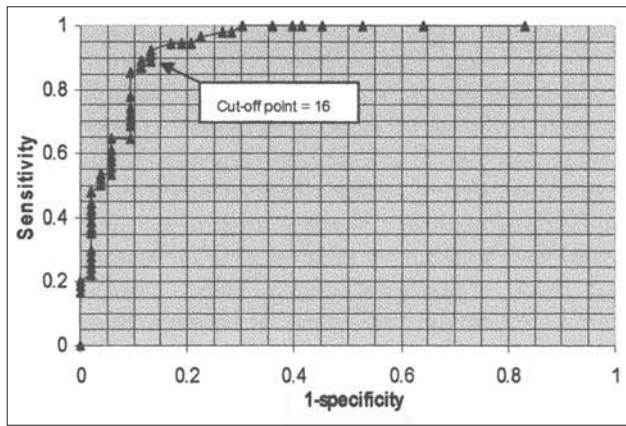


Figure 2. Receiver operating characteristic curve of DIAGNOdent without contacting teeth (direct application) at the D_3 level.

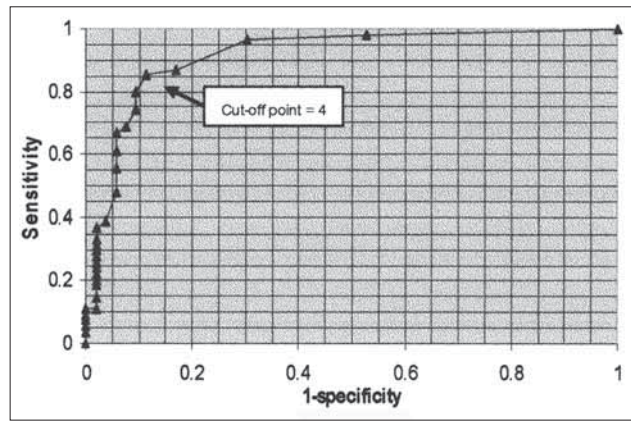


Figure 3. Receiver operating characteristic curve of DIAGNOdent with contacting teeth at the D_3 level.

capacity to distinguish the sound surface from noncavitated lesions.^{30,31}

DIAGNOdent's cutoff values for detecting proximal caries on surfaces without contacting teeth were similar to those for detecting occlusal caries in primary teeth.^{17,32} The optimal cutoff values of DIAGNOdent for detecting proximal caries on surfaces with contacting teeth were slightly lower than for those without contacting teeth (Table 4). In addition, cutoff values of DIAGNOdent for detecting proximal caries on surfaces with contacting teeth at the D_1 and D_2 level were the same, indicating that DIAGNOdent cannot distinguish the initial caries from enamel caries.

These results are supported by Lussi and Francescut,³² who studied the use of DIAGNOdent on occlusal caries in primary teeth and found that DIAGNOdent can distinguish dentinal caries from enamel caries much better than initial caries from enamel caries. Therefore, in contacting proximal surfaces of the primary teeth, DIAGNOdent can only distinguish dentine caries from initial or enamel caries. If the DIAGNOdent gives a value of 2 to 3, indicating initial or enamel caries, preventive measures and periodic recall would be suggested. These cutoff values, however, should be confirmed in clinical studies.

At all caries levels, the detection of proximal caries on primary teeth using DIAGNOdent generally showed lower sensitivity but higher specificity when the tooth had contact than when it did not have contact with adjacent teeth. This result can be explained by the fact that, even though most extrinsic stains were removed prior to the study, some extrinsic stains at the lesion or intrinsic stains remained. Stain was found in 38 out of 107 teeth (36%). This stain might produce a fluorescent signal that increases the DIAGNOdent value,^{25,33,34} and the contacting teeth could prevent false-positive readings from

the stain, therefore increasing the specificity. Concurrently, the contacting teeth also prevented the true positive readings from the carious lesions, leading to the reduction of the sensitivity. Furthermore, the high sensitivity of the DIAGNOdent, when detecting proximal caries of a surface without a contacting tooth, may be due to the use of the spot where the highest DIAGNOdent value was read to determine the line of cutting the tooth for histological examination. This increases the possibility of detecting true positive results.

In this study, it was found that proximal caries detection, when having contacting teeth using DIAGNOdent in every level of caries, had sensitivities ranging from 0.75 to 0.89. These values are slightly higher than those obtained from bitewing radiography, which had sensitivities ranging from 0.41 to 0.69. DIAGNOdent, however, had higher false-positive readings than bitewing radiography, which had perfect specificity or absolutely no false-positive readings. Despite its lower specificities (0.86 to 0.94), the DIAGNOdent examination has a higher sum of sensitivity and specificity compared to bitewing radiography. This can be interpreted to mean that DIAGNOdent is more accurate than bitewing radiography at detecting proximal caries of primary teeth.

In summary, DIAGNOdent is a simple tool that is well accepted by children and does not require high coopera-

Table 4. Cutoff Values for DIAGNOdent, Sensitivities, Specificities, and Sum of Sensitivities and Specificities for DIAGNOdent and BWR at Different Caries Levels (D_1 , D_2 , D_3)

	DIAGNOdent without contacting teeth			DIAGNOdent with contacting teeth			Bitewing radiography		
	D_1	D_2	D_3	D_1	D_2	D_3	D_1	D_2	D_3
Cutoff value	3	7	16	2	2	4	-	-	-
Sensitivity	0.89	0.98	0.93	0.75	0.89	0.85	0.69	0.55	0.41
Specificity	0.88	0.91	0.87	0.94	0.86	0.89	1	1	1
Sum of sensitivity and specificity	1.77	1.89	1.80	1.69	1.75	1.74	1.69	1.55	1.41

tion from a child because the reading can be processed within a few seconds. In addition, it does not produce hazardous results and, therefore, it can be reapplied without harm to the child. To yield the highest accuracy, DIAGNOdent should be used as an adjunct to other diagnostic methods. For example, DIAGNOdent can be used to detect proximal caries following visual examination when the carious lesion could not be detected visually. This is because it is highly sensitive.

When caries is indicated by DIAGNOdent, further diagnosis using bitewing radiography can be done to confirm the result. This is due to various clinical conditions, such as stains, plaque, and calculus, which can give false-positive DIAGNOdent readings, leading to an unnecessary invasive treatment of the tooth. Because of bitewing radiography's very high specificity, if no caries is indicated, then the tooth should not be treated and should be followed up periodically. If bitewing radiography is not possible, the tooth should be followed up by DIAGNOdent because of its high reliability. If the DIAGNOdent value increases, preventive or operative treatment should be considered. Recently, one study found that DIAGNOdent is useful for monitoring the progression and arrest of the occlusal caries in both primary and permanent teeth.³⁵ To use DIAGNOdent for monitoring proximal caries, however, requires more study.

Conclusions

Based on this study's results, the following conclusions regarding detection of proximal caries in primary teeth can be made:

1. DIAGNOdent has very high intra- and interexaminer reliabilities.
2. DIAGNOdent has higher diagnostic validity than bitewing radiography.
3. At D₁ and D₂ levels, the cutoff points of DIAGNOdent values of contacting teeth are the same.
4. It is impossible to distinguish initial caries from enamel caries.

This study was conducted in vitro. Further clinical study is recommended to confirm the use of DIAGNOdent in proximal caries diagnosis in primary teeth. At present, DIAGNOdent should only be used as an adjunct to other conventional caries diagnostic methods and practitioners should be aware of the procedure's additional cost.

Acknowledgement

The authors would like to acknowledge Prince of Songkla University, Songkhla, Thailand, for funding this study and gratefully thank all individuals who assisted in this project.

References

1. Mortimer KV. The relationship of deciduous enamel structure to dental disease. *Caries Res* 1970;4:206-223.
2. Wilson PR, Beynon AD. Mineralization differences between human deciduous and permanent enamel

measured by quantitative microradiography. *Archs Oral Biol* 1989;34:85-88.

3. Murray JJ, Majid ZA. The prevalence and progression of approximal caries in the deciduous dentition in British children. *Br Dent J* 1978;145:161-164.
4. Pitts NB, Rimmer PA. An in vivo comparison of radiographic and directly assessed clinical caries status of posterior approximal surfaces in primary and permanent teeth. *Caries Res* 1992;26:146-152.
5. Downer MC. Concurrent validity of an epidemiological diagnostic system for caries with the histological appearance of extracted teeth as validating criterion. *Caries Res* 1975;9:231-246.
6. Peers A, Hill FJ, Mitropoulos CM, Holloway PJ. Validity and reproducibility of clinical examination, fibre-optic transillumination, and bitewing radiology for the diagnosis of small approximal carious lesions: An in vitro study. *Caries Res* 1993;27:307-311.
7. Russel M, Pitts NB. Radiovisiographic diagnosis of dental caries: Initial comparison of basic mode videoprints with bitewing radiography. *Caries Res* 1993;27:65-70.
8. Ricketts DNJ, Whaites EJ, Kidd EAM, Brown JE, Wilson RF. An evaluation of the diagnostic yield from bitewing radiographs of small approximal and occlusal carious lesions in a low prevalence sample in vitro using different film types and speeds. *Br Dent J* 1997;182:51-58.
9. Angmar-Månsson B, ten Bosch JJ. Advances in methods for diagnosing coronal caries—a review. *Adv Dent Res* 1993;7:70-79.
10. Matalon S, Feuerstein O, Kaffe I. Diagnosis of approximal caries: Bitewing radiology vs the ultrasound caries detector. An in vitro study. *Oral Surg Oral Med Oral Pathol Oral Radiol Endod* 2003;59:626-631.
11. Hibst R, Gall R. Development of a diode laser based fluorescence caries detector [abstract]. *Caries Res* 1998;32:294.
12. Lussi A, Imwinkelried S, Pitts NB, Longbottom C, Reich E. Performance and reproducibility of a laser fluorescence system for detection of occlusal caries in vitro. *Caries Res* 1999;33:261-266.
13. Shi X-Q, Tranaeus S, Angmar-Månsson B. Comparison of QLF and DIAGNOdent for quantification of smooth surface caries. *Caries Res* 2001;35:21-26.
14. Shi X-Q, Tranaeus S, Angmar-Månsson B. Validation of DIAGNOdent for quantification of smooth-surface caries: an in vitro study. *Acta Odontol Scand* 2001;59:74-78.
15. Shi X-Q, Welander U, Angmar-Månsson B. Occlusal caries detection with KaVo DIAGNOdent and radiography: An in vitro comparison. *Caries Res* 2000;34:151-158.
16. Lussi A, Megert B, Longbottom C, Reich E, Francescut P. Clinical performance of a laser fluores-

- cence device for detection of occlusal caries lesions. *Eur J Oral Sci* 2001;109:14-19.
17. Attrill DC, Ashley PF. Occlusal caries detection in primary teeth: A comparison of DIAGNOdent with conventional methods. *Br Dent J* 2001;190:440-443.
 18. Francescut P, Lussi A. Correlation between fissure discoloration, Diagnodent measurements, and caries depth: An in vitro study. *Pediatr Dent* 2003;25:559-564.
 19. Wagner M, Longbottom C, Pitts NB. An in vitro comparison of a laser device with bitewing radiography for approximal caries detection [abstract]. *Caries Res* 1999;33:298.
 20. Longbottom C, Wagner M, Pitts NB, Lussi A. Simulated in vivo comparison of bitewing radiography and DIAGNOdent for approximal caries detection [abstract]. *Caries Res* 1992;33:298.
 21. Forgie AH, Pine CM, Pitts NB. Laser fluorescence detection of approximal caries: Initial in vitro results [abstract]. *J Dent Res* 1999;78:1044.
 22. Iwami Y, Shimizu A, Yamamoto H, Hayashi M, Takeshige F, Ebisu S. In vitro study of caries detection through sound dentin using a laser fluorescence device, DIAGNOdent. *Eur J Oral Sci* 2003;111:7-11.
 23. Pitts NB. Systems for grading approximal carious lesions and overlaps diagnosed from bitewing radiographs: Proposals for future standardization. *Community Dent Oral Epidemiol* 1984;12:114-122.
 24. Wenzel A, Hintze H. The choice of gold standard for evaluating tests for caries diagnosis. *Dentomaxillofac Radiol* 1999;28:132-136.
 25. Cârtes DF, Ellwood RP, Ekstrand KR. An in vitro comparison of a combined FOTI/visual examination of occlusal caries with other caries diagnostic methods and the effect of stain on their diagnostic performance. *Caries Res* 2003;37:8-16.
 26. Bamzahim M, Shi X-Q, Angmar-Månsson B. Occlusal caries detection and quantification by DIAGNOdent and electronic caries monitor: In vitro comparison. *Acta Odontol Scand* 2002;60:360-364.
 27. Alwas-Danowska HM, Plasschaert AJ, Suliborski S, Verdonschot EH. Reliability and validity issues of laser fluorescence measurements in occlusal caries diagnosis. *J Dent* 2002;30:129-234.
 28. Anttonen V, Seppä L, Hausen H. Clinical study of the use of the laser fluorescence device DIAGNOdent for detection of occlusal caries in children. *Caries Res* 2003;37:17-23.
 29. Costa AM, Yamaguti PM, De Paula LM, Bezerra AC. In vitro study of laser diode 655 nm diagnosis of occlusal caries. *J Dent Child* 2002;69:249-253.
 30. Feldens CA, Tovo MF, Kramer PF, Feldens EG, Ferreira SH, Finkler M. An in vitro study of the correlation between clinical and radiographic examinations of proximal carious lesions in primary molars. *J Clin Pediatr Dent* 2003;27:143-148.
 31. Espelid I, Tviet AB. Clinical and radiographic assessment of approximal carious lesions. *Acta Odontol Scand* 1986;44:31-37.
 32. Lussi A, Francescut P. Performance of conventional and new methods for the detection of occlusal caries in deciduous teeth. *Caries Res* 2003;37:2-7.
 33. Welsh GA, Hall AF, Hannah AJ, Foye RH. Variation in DIAGNOdent measurements of stained artificial caries lesions [abstract]. *Caries Res* 2000;34:324.
 34. El-Housseiny AA, Jamjoum H. Evaluation of visual, explorer, and a laser device for detection of early occlusal caries. *J Clin Pediatr Dent* 2001;26:41-48.
 35. Anttonen V, Seppä L, Hausen H. A follow-up study of the use of DIANOdent for monitoring fissure caries in children. *Community Dent Oral Epidemiol* 2004;32:312-318.