

CLINICAL techniques

A Method of Restoring Primary Anterior Teeth with the Aid of a Celluloid Crown Form and Composite Resins

David L. Webber, D.D.S.
Neil B. Epstein, D.M.D.
John W. Wong, D.M.D.
Anthi Tsamtsouris, D.M.D., M.S.

Abstract

The restoration of primary anterior teeth presents a problem to the clinician. This paper describes a technique for the restoration of carious or fractured primary anterior teeth, utilizing a transparent, removable, pedodontic crown form as a matrix and an acid-etched, composite resin as a restorative material.

Introduction

One of the problems facing the dental practitioner is the restoration of primary anterior teeth with caries, "baby bottle syndrome" and fractures. Recognition by the dental practitioner of the importance of appearance in a child's emotional development and the restoration of carious primary anterior teeth to an esthetic, functional, and natural looking relationship should be important objectives of dental service for children.

Many materials and techniques have been used in the restoration of primary anterior teeth.^{1,2,3} Amalgams, silicate cements, composite resins with various acid etch techniques, stainless steel crowns, open face stainless steel crowns, and polycarbonate crowns are frequently used today. Amalgams and stainless steel crowns are contraindicated when esthetics is a major consideration. Silicates, cements, and resins are indicated for small lesions, but often fail when used to re-

store large extensive areas of decay. Polycarbonate crowns provide excellent esthetics, but require careful cementation procedures for retention.^{4,5} Failure in the cementation of the polycarbonate crown is a major problem, resulting in early fracture and loss of the crown prior to the exfoliation of the restored tooth.

The objective of this paper is to describe a technique for the restoration of carious or fractured primary anterior teeth, using a transparent, removable, pedodontic crown form as a matrix for composite resins.

The use of pedodontic celluloid forms is indicated for anterior primary teeth having severe dental caries (Figure A); fractured teeth; malformed teeth including those having enamel hypoplasia; and discolored teeth. The forms are also indicated as a final restoration following pulpectomy or pulpotomy, and for extensive interproximal or lingual caries that preclude the use of silicate cements, composite resins or amalgam because of inadequate retention form.

However, the use of pedodontic celluloid crown forms is contraindicated for grossly decayed teeth with inadequate structure for retention; for extensive caries with no intact enamel left; impinging deep overbite; and in the presence of periodontal disease.

Technique

Initially, the tooth is cleaned thoroughly with a non-fluoridated prophylaxis paste. The surface enamel is

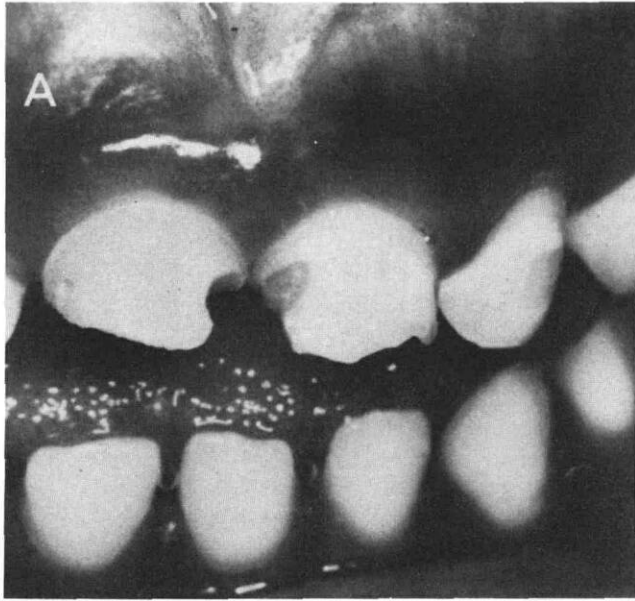


Figure A. Anterior primary central incisors with advanced caries and incisal fracture.

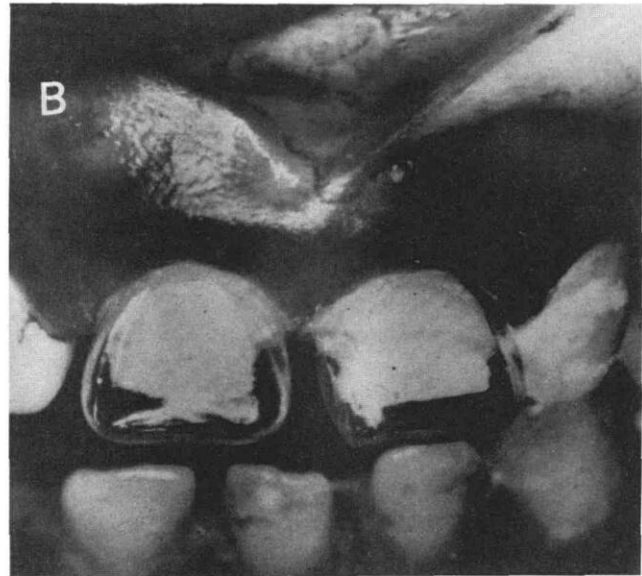


Figure B. Celluloid crown forms trimmed and fitted to anterior primary central incisors, incisal height adjusted.

prepared for acid etch bonding.^{6,7,8,9} A rubber dam may be used to isolate the tooth. Retention of this preparation depends on acid bonding to enamel^{10,11} and a gingival undercut, creating a mechanical lock. Therefore, the preparation should be conservative, retaining as much sound enamel as possible.

In properly etched enamel, there is evidence for mechanical bonding between enamel and resin in the form of resin tags in the microscopic pores of enamel.^{12,13,14}

Procedures for a Tooth Restoration Using a Celluloid Crown Form

- Administer local anesthesia as necessary.
- Isolate the anterior teeth using a rubber dam.
- Select an appropriate crown form to fit the mesial-distal width of the original tooth, taking care to maintain the original spaces or contacts present in the dentition.
- Reduce the mesial and distal proximal surfaces minimally using a fine tapered diamond. Reduction should be to the gingival margin, taking care to remove only as much tooth structure as necessary to allow a good fit of the celluloid crown form (Figure B).
- Reduce the incisal edge approximately 1 mm.
- Remove all caries with a spoon excavator or a #4 round bur.
- Create a slight undercut at the labial gingival margin, using a 33-1/3 inverted cone or a small round bur. Extend the undercut to the lingual gingival margin. Avoid reducing an excessive

amount of enamel at the labial and lingual surfaces.

- Place an appropriate pulp liner to all exposed dentin under a dry field before etching.^{15,16,17}
- Coat all enamel surfaces with a phosphoric acid etching solution. Leave on for at least 2 minutes.⁸ Wash and dry thoroughly. The prepared enamel should now be a uniform dull, chalky white texture.
- Trim the selected crown form with crown scissors to fit 1 mm below gingival margin. Be sure that the incisal height is at the desired level (Figure B).
- Place a vent on the lingual surface of the crown using a small round bur, to help prevent the entrapment of air bubbles in the composite filling material.
- Paint bonding sealant over the entire surface of the dried tooth.
- Mix the composite resin and fill the crown form, carefully avoiding entrapment of air bubbles.
- Seat the filled crown form carefully 1 mm below the gingival margin, making sure that it is in proper occlusion. While still soft, the crown form can be adjusted labially or lingually for occlusion and esthetics. Remove excess soft composite resin at the margins with an explorer.
- Allow the composite resin to harden completely before removal.
- Use a small green stone wheel to reduce the lingual surface of the celluloid crown form. An

explorer or scaler can then be used to peel the celluloid shell from the hardened composite resin.

Finishing (Figure C)

If the celluloid crown form was sized properly and positioned correctly, no further finishing of the labial surface should be required.

When composite resins polymerize in contact with a plastic form, they have the smoothest possible finish—no additional procedures can improve the surface luster.¹⁸ Leaving the labial resin surface intact will also insure against composite staining which can occur if roughened surfaces are left after clinical finishing and polishing.

The lingual areas should be adjusted to occlusion, if required.

Summary

A technique is described for the restoration of carious or fractured primary anterior teeth using a celluloid preformed crown with composite resin material. This has the advantage of producing an esthetic, functional and economical restoration easily and with minimal chair time. This technique has been used successfully for over three years with little fracture experience and very little color change as the composite resin ages. However, continued research is being conducted to evaluate the possibility of fracture and color change as the composite resin ages further.

References

1. Doyle, W. A.: "Esthetic Restorations of Deciduous Incisors, A New Class IV Preparation," *JADA*, 74:82, 1967.
2. Goto, G. and Jordan, R. E.: "The Effect of Full Crown Preparation on the Primary Pulp," *J Dent Child*, 41:23-27, Jan.-Feb. 1974.
3. Mink, J. R. and Hill, C. F.: "Crowns for Anterior Primary Teeth," *Dent Clin N Amer*, 17:85, 1973.
4. Tsamtsouris, A. and White, G. E.: "The Use of Preformed Crowns for the Primary Dentition—The Polycarbonate Crown," *J of Pedod*, 1:3-9, Fall 1976.
5. Tsamtsouris, A., White, G. E. and Ficarelli, J.: "An Improved Method to Cement Polycarbonate Crowns on Deciduous Anterior Teeth," *Quint Mt*, 2:1468: 47-50, Feb. 1977.
6. DePaola, P., Aasenden, R. and Brudevold, F.: "The Application of Acidulated Phosphate-Fluoride Preceded by Mild Enamel Etching," *J Dent Res*, 50:90, 1971 (abstract).
7. Goto, G. and Jordan, R. E.: "The Pulpal Effects of 50 Percent Phosphoric Acid," *J Can DA*, 30:248, 1972.
8. Silverstone, L. M. and Dogan, I. L.: "The Effect of Phosphoric Acid on Human Deciduous Enamel Surfaces In Vitro," *J IADC*, 7:11-15, 1976.
9. Stanley, H. R., Going, R. E. and Chaucy, H. H.: "Human Pulp Response to Acid Pretreatment of Dentin and to Composite Restoration," *JADA*, 91:817-825, Oct. 1975.

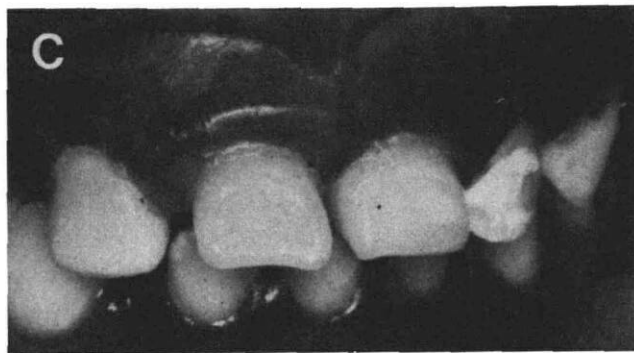


Figure C. Completed acid-etched composite resin crowns on anterior primary central incisors. Celluloid crown forms removed. Labial surfaces did not require finishing.

10. Lee, H. L.: "Adhesion Between Living Tissue and Plastics. 1. Adhesion of Epoxy and Polyurethane Resins to Dentin and Enamel," *J Biomed Material Res*, 3:349, 1969.
11. Newman, C. V. and Facq, J. M.: "The Effect of Adhesive Systems on Tooth Surfaces," *Amer J Ortho*, 59:67-75, 1971.
12. Gwinnett, A. J.: "Morphology of the Interface Between Adhesive Resins and Treated Enamel Surfaces as Seen by Scanning Electron Microscopy," *Arch Oral Biol*, 16:237, 1971.
13. Gwinnett, A. J. and Matsui, A.: "A Study of Enamel Adhesives: The Physical Relationship Between Enamel and Adhesive," *Arch Oral Biol*, 12:1615-1620, 1967.
14. Paklovan, A., Dennison, J. B. and Charbeneau, G. T.: "Penetration of Restorative Resins into Acid-Etch Human Enamel," *JADA*, 93:1170-1176, Dec. 1976.
15. Goto, G. and Jordan, R. E.: "Pulpal Response to Composite Resin Materials," *J Pros D*, 28:601-606, 1972.
16. Langeland, L. K., Dowden, W. E., Tronstad, L., et. al.: "Pulp Reactions to Composite Materials," *IADR Abstracts*, #832, 1972.
17. Liatukas, E. L. and Young, R. F.: "Sealing Composite Resin Restorations with a Cavity Sealant," *J Pros D*, 28:272-275, 1972.
18. Dennison, S. B. and Craig, R. G.: "Physical Properties and Finished Surface Texture of Composite Restorative Resins," *JADA*, 85:101-108, 1972.
19. Webber, D. L. and Epstein, N. B.: "Unitek's Pedo-form Strip Crowns: Technique Manual for Esthetic Composite Restorations of Primary Anterior Teeth," Unitek Corporation, 1977.

DAVID L. WEBBER AND NEIL B. EPSTEIN are in private practice of Pedodontics at 1795 Main Street, Springfield, Massachusetts.

JOHN W. WONG is affiliated with the Department of Oral Pediatrics, New England Medical Center, Boston, Massachusetts.

ANTHI TSAMTSOURIS is Assistant Professor, Department of Oral Pediatrics, Tufts University School of Dental Medicine, Boston, Massachusetts.

Requests for reprints may be sent to Dr. David L. Webber, 1795 Main Street, Springfield, MA 01103.