



## The esthetic stainless steel crown bridge: report of two cases

J. Timothy Wright, DDS, MS Scott Cashion, DDS, MS Roy Hoover

---

*Dr. Wright is professor, Department of Pediatric Dentistry, School of Dentistry, The University of North Carolina at Chapel Hill, NC, Dr. Cashion is in private practice in Winston-Salem, NC, and Mr. Hoover is a laboratory technician, Department of Pediatric Dentistry, School of Dentistry, The University of North Carolina at Chapel Hill, NC.*

---

The loss or congenital absence of permanent anterior teeth in young patients has significant psychological ramifications.<sup>1,2</sup> Typically, adolescent patients are acutely aware of their appearance and its importance in self-image and social acceptance. Although a variety of treatment approaches are available to provide esthetic replacement of missing anterior permanent teeth in young patients, there are numerous restorative and financial considerations. The continued eruption of teeth adjacent to the edentulous space, changing gingival contours and large pulp chambers generally contraindicate permanent restorative approaches. Transitional restorative approaches that optimize esthetics are frequently necessary until the patient is in late adolescence or early adulthood when definitive treatment can be performed (e.g., fixed appliances, implants).<sup>3</sup> Despite these restorative challenges, the dentist plays a crucial role in helping maintain optimal esthetics in this young patient population during a critical psychological and psychosocial period of development.

During the mixed or early permanent dentitions, transitional treatment often consists of removable tissue born partial dentures. This approach can provide excellent esthetics at a relatively low cost. While removable appliances are generally easy to fabricate and adjust, they also are easily broken and lost. Alternatively, a variety of fixed prostheses can be used in young adolescents having all their permanent anterior teeth. Over the past several decades, bonded prostheses have added substantially to our list of tooth replacement alternatives. Bonded prostheses include the Rochette bridge, Maryland bridge, ceramic-resin bridge, and direct bonding of pontics or natural tooth crowns lost from trauma.<sup>4,5</sup> Clinical studies have shown the success of bonded appliances to be variable and design dependent.<sup>4</sup> Clearly, all prostheses retained by bonding are predicated on having abutment teeth with adequate structure and sound enamel for bonding.

Clinicians can be faced with young patients requiring replacement of anterior permanent teeth where neither removable or bonded appliances are appropriate leaving few restorative options. For example, patients unable to maintain removable appliances or having soft tissue pathology may be poor candidates for removable partial dentures. Likewise, individuals with severe enamel hypoplasia or enamel hypomineralization may not be candidates for bonded prostheses. Because of our ongoing investigations and treatment of individuals with epidermolysis bullosa (EB); we have

been confronted with adolescent patients that are missing anterior teeth and have both soft tissue pathology and abnormal enamel, yet would benefit greatly from anterior-esthetic prostheses.

EB is a group of conditions characterized by blistering of the skin and oral mucosa.<sup>6,7</sup> In the dystrophic and junctional forms there can be marked fragility of the oral mucosa with frequent and severe blistering, ulceration, and depending on the EB type, scarring. The severe tissue fragility associated with EB makes the use of tissue born prostheses undesirable. Clinical studies show that 100% of individuals with the junctional forms of EB have enamel hypoplasia ranging from generalized pitting to near complete absence of the enamel.<sup>8</sup> While enamel bonding can be used successfully in some patients with junctional EB, those individuals with minimal enamel and small discolored teeth are not good candidates for restorations requiring bonding.

Children with recessive dystrophic EB are prone to developing rampant dental caries, apparently due to their severe soft tissue pathology.<sup>9,10</sup> These individuals typically have scarring of the oral vestibule, ankyloglossia, and a soft and high carbohydrate diet.<sup>11</sup> Traditional preventive approaches using mechanical plaque control and chemotherapeutic agents are also problematic due to the extreme tissue fragility and mucosal sensitivity. If uncontrolled, high caries activity in recessive dystrophic EB patients can lead to early anterior tooth loss. Junctional EB patients also can have an increased caries rate.<sup>9</sup> Increased caries in this population appears to be related largely to their enamel hypoplasia as their oral mucosa tends not to be scarred and have fragility of the magnitude seen in recessive dystrophic EB patients. In addition to having a high caries rate, junctional EB patients can have failure of eruption that affects selected anterior and/or posterior teeth. Missing anterior teeth in these special patient populations presents a tremendous restorative challenge where conventional treatment approaches are generally contraindicated or not possible.

We have treated two adolescents with severe forms of junctional EB that presented with missing anterior teeth. The purpose of this report is to describe a treatment approach using a resin-faced stainless steel crown bridge to achieve acceptable esthetics in this challenging population. This appliance has potential application in several patient populations that are poor candidates for more traditional restorative approaches.




Fig 1. Severe enamel hypoplasia and an unerupted central incisor resulting in poor anterior esthetics.

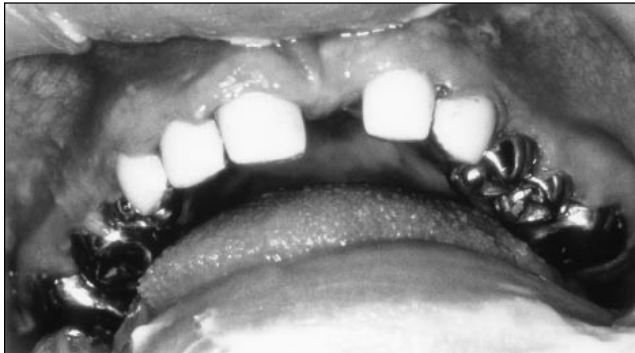

Fig 2. Esthetics are markedly improved by restoration with prefabricated resin-faced SSCs.




Fig 3. A wire framework is soldered to span the edentulous space and provide support for the pontic.

## Case reports

### Case 1

A 14-year-old male with the Herlitz variant of junctional EB presented with severe enamel hypoplasia and failure of the maxillary left central incisor to erupt (Fig 1). The unerupted tooth showed extensive crown resorption. The teeth were initially restored with individual Stainless Steel Crowns (SSCs) (Fig 2) with the aid of general anesthesia as has been previously described.<sup>12,13</sup> No attempt was made to surgically extract

or replace the unerupted central incisor at this time. While the patient was pleased with the esthetics of his anterior teeth, he continued to express concern regarding the esthetics of the missing tooth. After extensive discussions of the patient's and parents' expectations and the treatment options available (e.g., leaving the edentulous space, metal and/or ceramic full coverage prosthesis), the Esthetic SSC Bridge was selected as the treatment of choice. The patient was treated in a conventional manner using local anesthesia. The existing SSCs were removed from the permanent cuspid, lateral incisor, and central incisor and new crowns fitted. Permanent SSCs were selected, contoured, and seated on the prepared teeth. With the crowns in place, an alginate impression of the maxillary arch was made. The SSCs were then removed and securely seated in the alginate impression that was immediately taken to a laboratory for prosthesis fabrication.

### Prosthesis fabrication

The alginate impression was poured in stone with the SSCs in place providing a working model. Two stainless steel wires (positioned 0.020 inch incisally and 0.036 inch gingivally) were soldered to the lingual aspect of the central incisor and to the lateral incisor crowns to provide support for the pontic (Fig 3). The cuspid and lateral incisor crowns were soldered together in the proximal contact area to provide double abutment support for the distal aspect of the bridge. The solder joints were polished and a resin denture tooth attached to the wire framework using cold-cure methyl methacrylate (Fig 4). The pontic shade was selected to match the resin to be used for the open-face restorations of the abutment teeth. The gingival extension of the pontic was placed just above the tissue to allow for adequate cleaning while not allowing food entrapment or gingival irritation. The acrylic attachment was highly polished and the completed prosthesis returned for try in and cementation. The appliance was carefully assessed for gingival extension and the absence of soft-tissue blanching. The bridge was cemented with glass-ionomer cement. After allowing initial set of the cement, the abutment crowns were prepared for open-face resin restorations. Window preparations were extended just beyond the proximal line angles and incisal edge to provide maximum esthetics (Fig 5). The teeth were etched and resin windows applied to the preparations (Fig 6). The patient was extremely pleased with the esthetics of the restoration and had no postoperative soft-tissue complications from the procedure or proximity of the pontic to the tissue. The bridge has been in place for 12 months with no breakage and continues to display excellent soft-tissue acceptance.

### Case 2

A 15-year-old male with the Herlitz variant of junctional EB presented with severe enamel hypoplasia and missing the permanent left maxillary central and lateral incisors (Fig 7). The incisors had been lost in a traumatic vehicular accident creating a substantial bony defect in the alveolus. The patient had received facial skin grafts due to the presence of extensive perioral and facial skin lesions that are typically present in this EB type. Due to the patient's age, medical condition, and need for full coverage of all the permanent teeth, the family elected to proceed with treatment with the aid of general anesthesia. Despite the patient's medical status, both the patient and parents wanted an improved esthetic outcome. The options



Fig 4. The resin pontic is attached to the framework with methacrylate.

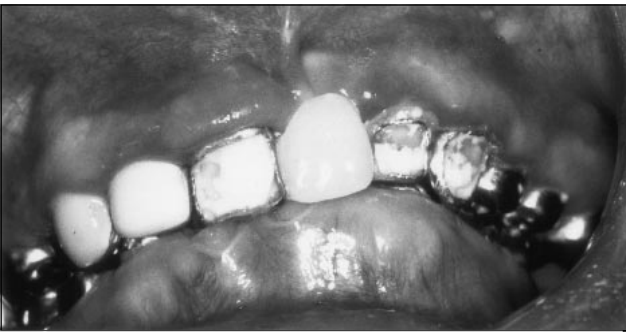

Fig 5. After cementation the SSC abutments are prepared for facial resin restorations.




Fig 6. The completed Esthetic SSC Bridge markedly enhances the dental appearance.

of fixed and removable appliances were discussed and the family elected to proceed with treatment using the Esthetic SSC Bridge.

An atraumatic approach using general anesthesia as previously described was used to provide comprehensive dental care to the patient.<sup>12, 13</sup> The restorative procedures were coordinated with the dental laboratory so the Esthetic SSC Bridge could be delivered at the end of the procedure. Restorative treatment was initiated by preparing the anterior abutments for SSCs. The maxillary central incisor, cuspid, and first premolar were

prepared and crowns were contoured and fitted. An alginate impression was taken with the crowns in place and immediately sent to the lab where the Esthetic SSC Bridge was fabricated using the same techniques as described previously. The distal extension of the bridge was double abutted by soldering the cuspid and first premolar crowns together. The appliance design was also modified by placing a tissue-colored gingival extension at the cervical area of the two pontics to cover the large alveolar defect (Fig 8). Again, care was taken to ensure that the acrylic extension did not impinge on the soft tissues. During prosthesis fabrication, the remaining dentition was prepared and restored with SSCs. The appliance was brought to the operating room, fitted, and cemented. Open-faced resin restorations were placed in the three abutment teeth after initial set of the cement (Fig 9). The patient and parents were very satisfied with the esthetics of the appliance and after 18 months the appliance remains intact with excellent soft-tissue health.

## Discussion

The Esthetic SSC Bridge offers an additional treatment modality for the management of missing anterior teeth in the adolescent patient. It provides several distinct advantages compared with other approaches. The appliance is fixed and tooth born thereby protecting the soft tissue from supporting a prosthesis. This is especially beneficial in people with EB where soft-tissue manipulation can lead to tissue separation and ulceration. In patients with soft-tissue pathology that contraindicates tissue-born appliances, the Esthetic SSC Bridge offers a tooth-born alternative with good esthetics. However, extreme care must be taken in patients with EB to ensure that the pontics of a fixed appliance do not cause soft-tissue irritation or impingement. While stainless steel crowns can be irritating to the gingival tissues if not properly adapted, the success of these SSC restorations in EB patients is well documented.<sup>13</sup>

The Esthetic SSC Bridge also negates the patient's need to maintain and care for a removable appliance thereby reducing the likelihood of loss or breakage. Although removable appliances are often less durable than fixed appliances, they do have the advantages of being relatively low in cost and allowing easy cleansing of the teeth proximal to the edentulous space. Having a fixed appliance requires additional oral hygiene care to ensure gingival health and to maintain caries-free and periodontally healthy abutments.

Patients with high caries rates are often best treated with full-coverage restorations due to the increased risk of new primary caries or secondary caries. The use of bonded bridges in patients with a high caries risk should be approached with caution as illustrated by a recent report describing the use of a Rochette bridge in a patient with recessive dystrophic EB.<sup>14</sup> Decalcification and carious destruction of the uncovered portions of the abutment teeth is a likely sequelae to this treatment approach. Fixed anterior prosthetic appliances to replace missing teeth that use orthodontic bands to secure the prosthesis have also been described for EB patients.<sup>15</sup> While orthodontic bands may protect the most caries prone areas of the abutment teeth, the remaining exposed tooth structure remains that can become carious. On the other hand, this type of appliance can be more easily removed and the abutment teeth treated with fluoride to reduce the likelihood of recurrent caries. The use




Fig 7. Esthetic restoration of this case is complicated by the severe enamel hypoplasia and alveolar defect associated with the missing lateral and central incisors.




Fig 8. The Esthetic SSC Bridge has an acrylic gingival extension attached to the pontics to help mask the alveolar defect.

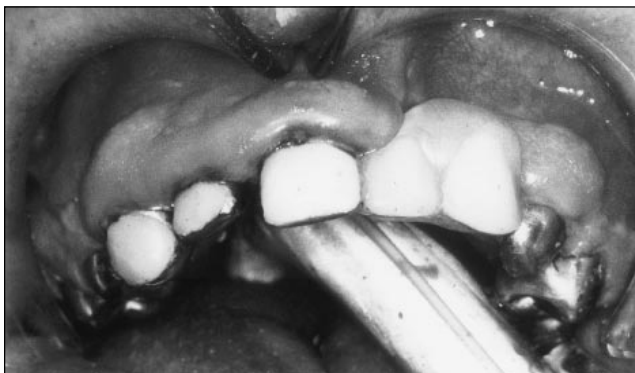

Fig 9. Insertion of the Esthetic SSC Bridge replaces the missing teeth and provides a more esthetic contour of the alveolus.

of the SSC bridge in high caries-risk patients offers the benefit of full coverage on the abutment teeth, thereby reducing the likelihood of developing new caries.

Another advantage of the esthetic SSC bridge is the short fabrication time and use of materials that are routinely used in the treatment of pediatric patients. The laboratory techniques are simple and can be accomplished in a short enough time to allow fabrication and delivery during one visit or an operating room procedure. Simplicity of the appliance and the materials used allow the appliance to be fabricated at a sub-

stantially lower cost compared with cast metal framework bonded appliances.

While individuals with EB clearly present unique and challenging oral manifestations, they show positive psychological benefit from enhanced dental esthetics.<sup>11, 15</sup> Although as yet untested, other patient populations that are appropriate for consideration of treatment with the Esthetic SSC Bridge include mentally handicapped patients that are unable to manage removable appliances. Patients with severe enamel hypoplasia and/or hypomineralization associated with conditions such as amelogenesis imperfecta, trichodonto-osseous syndrome, and focal dermal hypoplasia are also appropriate candidates for Esthetic SSC Bridge treatment. Adolescents with rampant caries may also be considered for this treatment approach.

Short- and long-term treatment goals must be considered and the benefits and alternatives for each treatment evaluated. Short-term treatment goals frequently include interim restorative approaches to maintain or establish optimum esthetics. Because of the numerous treatments available and unique dental and psychological requirements of each patient, a multidisciplinary approach may best meet the needs of the young patient with missing anterior teeth.<sup>3</sup> The Esthetic SSC Bridge is an alternative treatment approach that can provide excellent esthetics and enhanced self-image in patients who might not otherwise receive optimal treatment.

### Conclusions

1. The Esthetic SSC Bridge has been used to successfully address the anterior esthetic restorative needs in two adolescents with junctional EB.
2. Replacement of missing anterior teeth in the adolescent population is essential to optimal psychological and psychosocial development.
3. Patients with severe enamel hypoplasia, rampant dental caries, or soft-tissue involvement are often best treated with full coverage fixed appliances.
4. The Esthetic SSC Bridge is relatively easy to fabricate and offers an additional treatment modality for replacing missing anterior teeth in specific patient populations.

This research was supported in part by MCH Grant #MCJ379494.

### References

1. Belanger G: Early treatment considerations for oligodontia in ectodermal dysplasia: A case report. *Quintessence Int* 25:705-711, 1994.
2. Giddon D: Orthodontic applications of psychological and perceptual studies of facial esthetics. *Seminar Orthod* 1:82-89, 1995.
3. Bergendal B, Bergendal T, Hallonsten A-L, Koch C, Kurol J, Kvint S: A multidisciplinary approach to oral rehabilitation with osseointegrated implants in children and adolescents with multiple aplasia. *Eur J Orthod* 18:119-29, 1996.
4. Berekally T, Smales R: A retrospective clinical evaluation of resin-bonded bridges inserted at the Adelaide Dental Hospital. *Aust Dent J* 38:85-96, 1993.
5. Trushkowsky R: Replacement of congenitally missing lateral incisors with ceramic resin-bonded fixed partial dentures. *J Prosthet Dent* 73:12-16, 1995.
6. Fine J-D, Wright JT: Epidermolysis Bullosa, in: *Clinical*

- Dermatology, Demis, JD, Editor, Philadelphia:Lippincott-Raven. 1995 pp.1-35.
7. Wright J, Fine J-D: Hereditary epidermolysis bullosa. *Seminar Dermatol* 13:102-107, 1994.
  8. Wright JT, Fine J-D, Johnson LB: Developmental defects of enamel in humans with hereditary epidermolysis bullosa. *Arch Oral Biol* 38:945-55, 1993.
  9. Wright JT, Fine J-D, Johnson L: Dental caries risk factors in hereditary epidermolysis bullosa. *Pediatr Dent* 16:427-32, 1994.
  10. Kirkham J, Robinson C, Strafford SM, Bonass WA, Brookes SJ, Wright JT: The chemical composition of tooth enamel in recessive dystrophic epidermolysis bullosa: significance with respect to dental caries. *J Dent Res* 75:J672-78, 1996.
  11. Wright JT, Fine J-D, Johnson LB: Hereditary epidermolysis bullosa: oral manifestations and dental management. *Pediatr Dent* 15:242-48, 1993.
  12. Wright JT: Epidermolysis bullosa: dental and anesthetic management of two cases. *Oral Surg Oral Med Oral Pathol* 57:155-57, 1984.
  13. Wright JT: Comprehensive dental care and general anesthetic management of hereditary epidermolysis bullosa: A review of 14 cases. *Oral Surg Oral Med Oral Pathol* 70:573-78, 1990.
  14. Olsen CB, Bourke LF: Recessive dystrophic epidermolysis bullosa: Two case reports with 20-year follow-up. *Aust Dent J* 42:1-7, 1997
  15. Martinez C: Esthetic anterior restorations in a child with epidermolysis bullosa: Case report. *J Dent Handicap* 3:29-30, 1978.

## ABSTRACT OF THE SCIENTIFIC LITERATURE



### PROBLEMS IN THE MANAGEMENT OF ATTENTION-DEFICIT-HYPERACTIVITY.

This review article of attention-deficit-hyperactivity disorder (ADHD) discusses the clinical challenges for clinicians attempting to diagnose the condition, deciding when to medicate, and determining action when a child does not respond to standard interventions.

Diagnosis is based on history obtained from care givers, as there is no single test. The symptoms are impulsivity, inattention, and motor restlessness.

Head injury, petit mal seizures, and cerebral infections can lead to the symptoms of ADHD. Practice guidelines recommend that a complete medical history be taken and a physical examination be completed. No other specific laboratory tests are required.

The reviewers recommend that a diagnosis of ADHD only be made if the disturbance cannot be accounted for by another mental disorder. Mood disorders (notably depression) and anxiety disorders are most commonly misdiagnosed as ADHD. Any evidence of learning difficulty in children with ADHD warrants psychometric testing, as these two separate conditions can aggravate each other.

The various parts of the multimodal therapy are dictated by the individual. Educational material (patient and care givers), behavior-modification, educational interventions and accommodations, social skills training, individual counseling, medical intervention are included in treatment. With regard to the latter, this review summarizes the huge amount of data on the efficacy of stimulants for ADHD. However, they also caution that while stimulants may improve the child's academic performance, gains in long-term performance have not been documented.

A large multisite study is mentioned, which hopes to clarify the relative efficacy of each component of multi modal treatment. Neurobiologic research on ADHD has grown in the last decade and offers hope regarding the high degree of inheritance of ADHD.

This comprehensive review is of interest to pediatric dentists due to the seemingly increasing numbers of patients seen with who have been diagnosed with ADHD. Often their less than ideal behavior leads to their referral to a pediatric dentist and it is therefore important that we remain current on this disorder. LN

Zametkin AJ, Ernst M. *New Engl Jnl Med* 340:40-46, 1999.

*Reprint Information: Dr Zametkin Rm 3N238 Bldg 10 National Institutes of Health 10 Center Drive Bethesda MD 20892*