

## Effect of trauma to primary incisors on root development of their permanent successors

Yerucham Zilberman, DMD   Anna Fuks, CD  
Yocheved Ben Bassat, DMD   Ilana Brin, DMD  
Jehoshua Lustmann, DMD

### Abstract

*Trauma to the primary incisors may, by their displacement, cause developmental disturbances in the root formation of the permanent incisors. To verify this hypothesis, dental radiographs of 34 children, whose primary incisors had been previously injured, were evaluated. Only 6 children showed disturbances in root development of maxillary permanent incisors. Three cases in which trauma to the primary dentition resulted in pathology to the permanent dentition are presented, stressing the need for close periodic examination and early detection of possible developmental defects in the permanent dentition.*

The correlation between the presence of mineralization defects, observed in the maxillary permanent incisors of a group of school children, and the history of trauma to their primary dentition, has been reported.<sup>1,2</sup> The clinical and radiographic results of these studies demonstrated that most of the children with affected permanent incisors experienced trauma prior to age 5 years and during Nolla's developmental stages 3-6 (Table 1).<sup>3</sup>

The impact of the primary roots to the developing tooth at the time of the trauma may cause a deflection or displacement of the permanent successors.<sup>4</sup> The purpose of the present study was to investigate the eventual effects of trauma to the primary incisors on the root development of their permanent successors.

### Methods and Materials

The dental records of 34 children whose maxillary primary incisors had been traumatized previously were selected from a larger sample.<sup>2</sup> Only records of children whose clinical history and periapical radiographs taken at the time of the injury did not

disclose signs of previous trauma were included. In contrast to the previous report,<sup>2</sup> teeth presenting with deep carious lesions were not excluded from the present study, since it is doubtful that the presence of a carious lesion in a primary crown would affect root development of the permanent successor.

The majority of the children included in this report experienced trauma to their primary incisors between ages 1 and 3½ years, and the most common types of injury recorded were palatal displacement and luxation.

Periapical radiographs taken at the time of trauma were evaluated for:

1. The amount of resorption of the roots of primary incisors, and
2. The developmental stage of the permanent buds according to Nolla.<sup>3</sup>

Radiographic evaluation revealed that at the time of trauma the primary teeth had fully formed roots or were at the initial stages of root resorption. The buds of the permanent incisors were at Nolla's developmental stages 3-6.

One hundred twenty-nine fully erupted maxillary permanent incisors were examined and classified into 2 groups: (1) trauma group—comprising 68 permanent incisors which were the successors of traumatized primary teeth; (2) nontrauma group—including 61 permanent incisors, successors to nontraumatized primary teeth (i.e., teeth located adjacent to the injured ones).

The distribution of the sample according to age and dental development at the time of trauma was similar in both groups.

Standardized long-cone periapical and tangential radiographs of the permanent incisors taken at a recall examination were analyzed for developmental

**Table 1.** Stages of Dental Development (according to Nolla)

Stage 0	Absence of crypt
Stage 1	Presence of crypt
Stage 2	Initial calcification
Stage 3	One-third of crown completed
Stage 4	Two-thirds of crown completed
Stage 5	Crown almost completed
Stage 6	Crown completed
Stage 7	One-third of root completed
Stage 8	Two-thirds of root completed
Stage 9	Root almost completed—open apex
Stage 10	Apical end of root completed

disturbances of the roots and the surrounding bone as follows:

1. Root dilaceration in the mesiodistal and buccolingual dimensions
2. Arrest of root formation
3. Obliteration of pulp chamber and root canal
4. Severe malformation of the root or any other phenomenon involving the surrounding bone.

Root dilaceration has been defined by Andreassen<sup>4</sup> as a sharp deviation or bend of the root in relation to the long axis of the tooth. A slight distal angulation, frequently seen in lateral incisors, was considered as normal. The dilaceration was recorded according to its location, i.e., cervical, middle, and apical one-third of the root.

## Results

Six children (17.6%) presented with developmental disturbances in the root or a pathologic condition in the surrounding bone. The disturbances in root formation appeared in teeth which were traumatized between Nolla's developmental stages 2 and 8.

Root dilaceration was present in 6 permanent incisors (4.7%)—5 incisors were successors of trau-

matized primary teeth and 1 incisor was in the non-trauma group (Table 2).

In some of the cases more than 1 type of change occurred in the same tooth. Two teeth presented with an arrest in root formation and demonstrated extremely short, thinner than normal and grossly deformed structure (patients 2 and 57).

Other pathological phenomena observed were: obliteration of pulp chamber (patient 39); severe crown and root malformation (odontoma-like formation in patient 57); tooth bud and bone sequestration (patient 83); and transposition of a lateral incisor and the adjacent canine (patient 2). These cases were the expression of extensive and severe traumatic events to the primary dentition.

The small number of teeth with affected roots did not allow statistical correlation between the consequences of the trauma and the type of trauma or Nolla's developmental stages. However, in the following cases some of these relations are suggested.

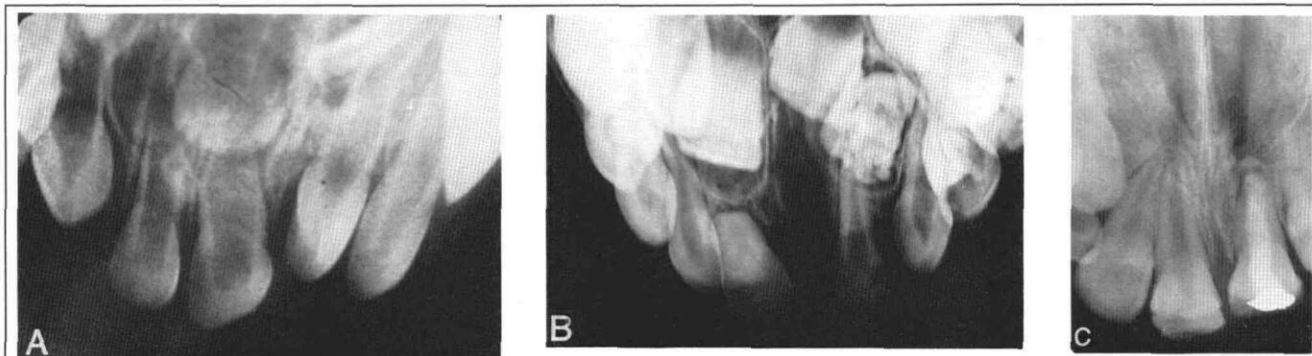
Patient 57 demonstrated the effect of a severe injury at a young age on the developing tooth buds. A 1-year-old girl fell off a staircase. The clinical examination revealed luxation A, intrusion of A, and laceration of the gingivae around these teeth. No additional injuries could be observed on a periapical radiograph.

Five months following the injury, a periapical radiograph (Fig 1A) demonstrated that the primary left central incisor remained in an intruded position and rotated with a resultant mesial and distal bony defect. The right primary central and lateral incisors showed very wide pulp chambers, with an unexplained "mineralized" area in the middle third of the root of B. The permanent tooth bud of 1 was at developmental stage 3 and showed evidence of a mineralization defect. The permanent tooth buds of 12 were poorly visualized and their location appeared to be more apical than their contralaterals.

**TABLE 2.** Distribution of Permanent Tooth Root Malformations According to the Most Common Types of Trauma to the Primary Incisors

Type of Trauma	Total No. of Primary Incisors	Permanent Teeth with Root Dilaceration	Permanent Teeth with Other Root or Surrounding Bone Malformations	Permanent Teeth with Normal Root
Luxation	26*	3	1	23
Palatal displacement	22	1	—	21
Intrusion	9*	1	2	7
Exfoliation	8	—	—	8
Others	10	—	1	9
Nontrauma	61	1	1	59
Total	136*	6	5	127

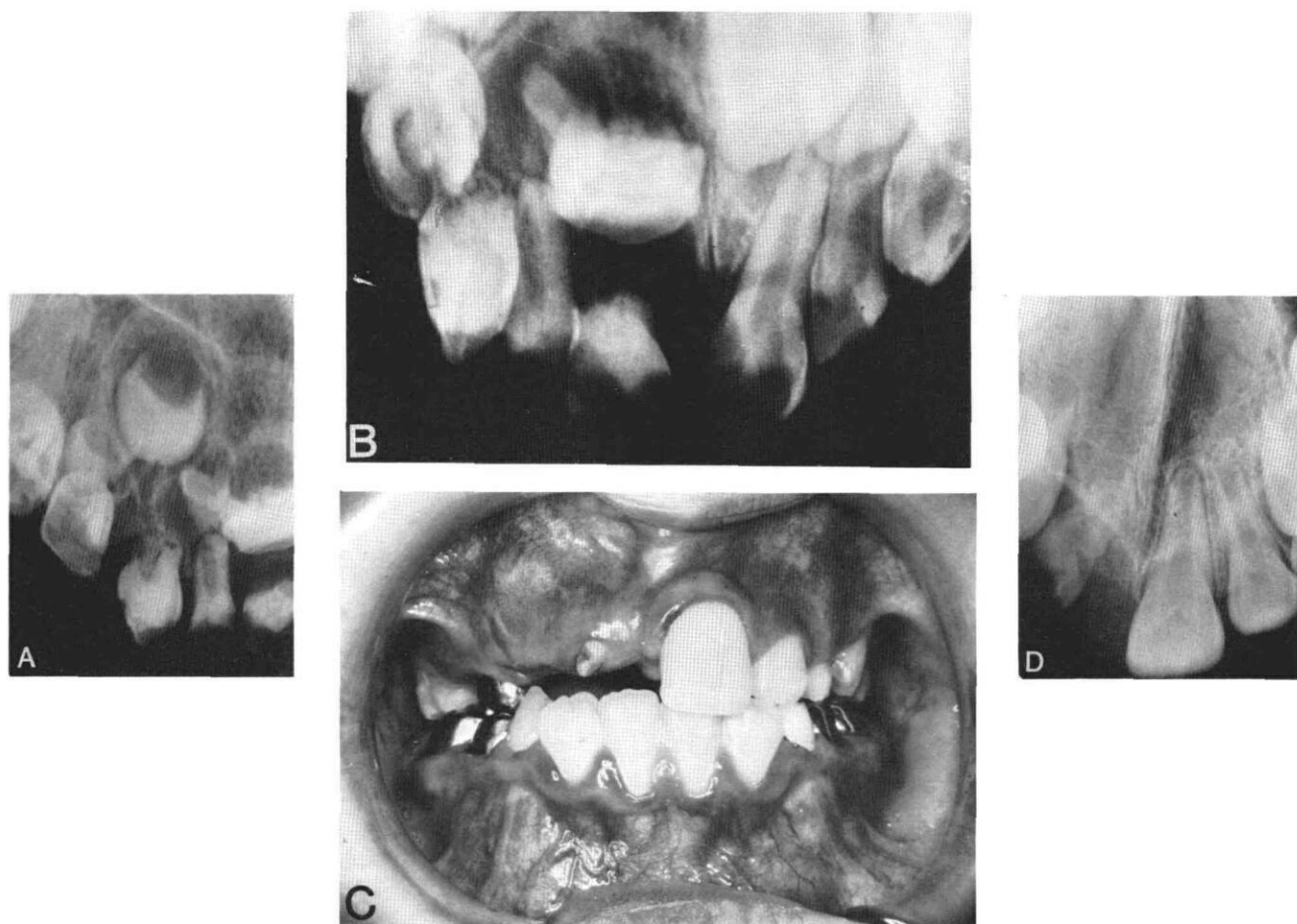
\* In a few cases more than 1 type of root malformation occurred in a tooth.



**FIG 1.** Patient 57. **A.** Periapical radiograph taken 5 months after the trauma. Note the intruded and rotated 1A and the poorly visualized 12 and their more apical location compared to their contralaterals. **B.** Radiograph taken 4 years, 4 months following the injury. Note the mineralization defects of 11 and the severe crown and root malformation (odontoma-like formation) of 2. **C.** Radiograph taken at age 12 years. Note the poorly developed root of 1 following apexification and root canal filling.

Radiographs taken 4 years, 4 months following the injury revealed mineralization defects of 11, malposition of 1 and a severe crown and root malformation (odontoma-like formation) of 2 (Fig 1B).

1A previously had been extracted due to an infected periapical lesion. The right primary central incisor presented with obliteration of the pulp chamber and pulp canal as well as premature resorption of the



**FIG 2.** Patient 83. **A & B.** Periapical radiographs taken at the first examination, 2 years following the injury. Note the pathological conditions of the primary teeth, especially on the right side. The crowns of 21 are underdeveloped and their follicles disturbed. **C & D.** Clinical photograph and periapical radiograph taken at age 9 years. Note the rudimentary crown and irregular root formation of 2.

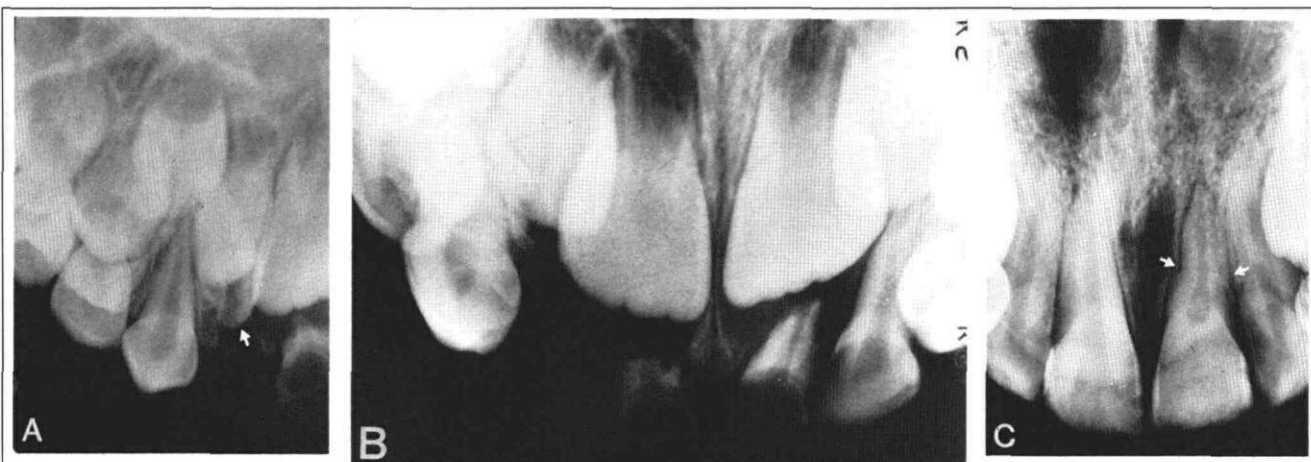

FIG 3. Patient 39. A & B. Periapical radiographs taken 2 days after the trauma. Note the intruded B| and the pathologic root resorption of A|A accompanied by periapical bone destruction. C. Periapical radiograph taken at age 10 years. Note the dilaceration at the middle one-third of the root of 1| and an obliteration of its pulp chamber.

apical third of its root. At this stage, A|B were extracted and the severely malformed left permanent lateral incisor was removed surgically. At a further follow-up examination, delayed eruption of 1| was observed.

At age 12 years, 11 years following the injury, the crowns of the maxillary central incisors presented with severe hypoplasia accompanied by brown discoloration. Additional white discoloration appeared on 1|. The left permanent canine erupted adjacent to 1| replacing the extracted 2|. The periapical radiograph taken at this stage (Fig 1C) showed 1| with a poorly developed root. This tooth underwent an apexification followed by a conventional root canal filling which had been performed 1 year earlier, due to periapical infection.

Patient 83 presented severe sequelae to an early intrusion of primary teeth. The child first presented for examination 2 years after having fallen on a hard object at age 1 year. According to the information obtained from his mother, 3 of his anterior teeth (CBA|) were intruded. Periapical radiographs taken at the time of examination demonstrated extensive pathologic root and bone resorption of A|, surrounded by a periapical radiolucency, and pulp chamber obliteration of BA| (Figs 2A, B). The maxillary right primary canine presented with an obliterated pulp chamber and stunting of the root, as well as hypoplastic defects on the incisal edge. Extensive carious lesions were present in all anterior teeth. Underdevelopment of the crowns of 21| as well as disturbances in their follicles also were evident. The bud of 1| underwent sequestration and was removed surgically. Although the bud of 2| presented signs of developmental disturbance of the crown, the decision was made to retain it.

At age 9 years a rudimentary crown of 2| erupted

ed into the oral cavity (Fig 2C). A periapical radiograph revealed irregular root formation in addition to the deformed crown (Fig 2D). The patient was referred for combined orthodontic and restorative treatment.

Patient 39 represents the nontrauma phenomenon, namely, damage to a permanent successor of a primary tooth which was adjacent to a traumatized primary incisor. The patient was a 4½-year-old girl who presented to the Oral Surgery Department 2 days after having fallen at home. Clinical examination revealed intrusion of B| and soft tissue lacerations. The maxillary primary central incisors had extensive carious lesions. Periapical radiographs taken at this time (Figs 3A, B) confirmed the clinical diagnosis and showed pathologic root resorption of A|A accompanied by periapical bone destruction. The maxillary permanent central and lateral incisors appeared to be normal and were at developmental stage 6. The 2 primary central and the right lateral incisors then were extracted.

At age 10 years no enamel mineralization defects were observed in the permanent central incisors. However, a periapical radiograph (Fig 3C) revealed, in addition to mesial caries of 1|, dilaceration of the middle one-third of the root of 1| and an obliteration of its pulp chamber. Its periodontal ligament was also wider when compared to its contralateral.

## Discussion

The influence of trauma to the primary incisors on their permanent successors can be related to several factors such as the spatial relationship of the involved teeth, to the child's age at the time of injury, mainly to its dental developmental stage, and to the type of injury.<sup>5,6</sup>

In the present study the findings were similar to

those reported by Andreasen.<sup>4,6</sup> The permanent incisors with affected root development comprised only 4.7% of the examined permanent teeth. The wide range of developmental stages (2-8) of the tooth buds of the affected teeth suggests that the vulnerability of the developing root is not directly related to its developmental stage. The severity of root malformation may, however, be related to the severity of the trauma. In the present sample the children with severe disturbances in root development suffered an extremely traumatic injury.

The possible explanation to this assumption might be the different mode of transmission of the traumatic force to the enamel organ and to the Hertwig's epithelial root sheath. The trauma to the primary tooth is transmitted directly to the developing crown of the permanent bud due to the close proximity of the primary tooth root and the developing enamel organ.<sup>5,6</sup> This hypothesis was confirmed in a previous report in which most of the mineralization defects were found in the incisal one-third of the crown, regardless of the developmental stage of the tooth bud.<sup>1</sup> In contrast to that, the effect of trauma to the Hertwig's epithelial root sheath is the result of the transmission of the traumatic force through the surrounding bone or through the primary tooth, causing deflection or displacement of the permanent bud. Such a course of events requires a traumatic force of a considerable magnitude. This element and the direction of the traumatic force are probably the crucial factors in the observed root deformities rather than the developmental stage of the affected tooth bud.

Another factor which could be of importance in the transmission of the traumatic force might be the length of the primary incisor root. In the investigated sample, most of the primary incisors had fully formed roots or were in the early stages of root resorption at the time of the injury. This did not allow evaluation of the effect of primary root length on the

development of the permanent tooth root. However, when this factor was studied previously in relation to mineralization defects on the permanent crowns no association could be established.<sup>2</sup>

The cases presented stress the need for close periodic clinical and radiographic examination, since some of the pathological conditions developed a long time after the trauma occurred. Parents should be informed of this fact because lack of awareness leads to noncompliance. These patients "disappear" and only return when the clinical problem is already fully evident.

This study was supported in part by a grant from the Joint Research Fund of the Hebrew University—Hadassah School of Dental Medicine, founded by the Alpha Omega Fraternity and the Hadassah Medical Organization.

Dr. Zilberman is a senior lecturer, Dr. Ben-Bassat and Dr. Brin are lecturers, orthodontics; Dr. Fuks is a senior lecturer, pedodontics; and Dr. Lustmann is a senior lecturer, oral and maxillofacial surgery, The Hebrew University. Reprint requests should be sent to: Dr. Yerucham Zilberman, Dept. of Orthodontics, The Hebrew University, Hadassah Faculty of Dental Medicine, PO Box 1172, Jerusalem, Israel.

1. Brin I, Ben-Bassat Y, Fuks A, Zilberman Y: Trauma to the primary incisors and its effect on the permanent successors. *Pediatr Dent* 6:78-82, 1984.
2. Ben-Bassat Y, Brin I, Fuks A, Zilberman Y: Effects of trauma to the primary incisors on permanent successors in different developmental stages. *Pediatr Dent* 7:37-40, 1985.
3. Nolla CM: The development of the permanent teeth. *J Dent Child* 27:254-66, 1960.
4. Andreasen JO: *Traumatic Injuries of the Teeth*, 2nd ed. Copenhagen; Munksgaard, 1981, ch 9.
5. Smith RJ, Rapp R: A cephalometric study of the developmental relationship between primary and permanent maxillary central incisor teeth. *J Dent Child* 47:36-41, 1980.
6. Andreasen JO, Ravn JJ: The effect of traumatic injuries to primary teeth on their permanent successors. II. A clinical and radiographic follow-up study of 213 teeth. *Scand J Dent Res* 79: 284-94, 1971.