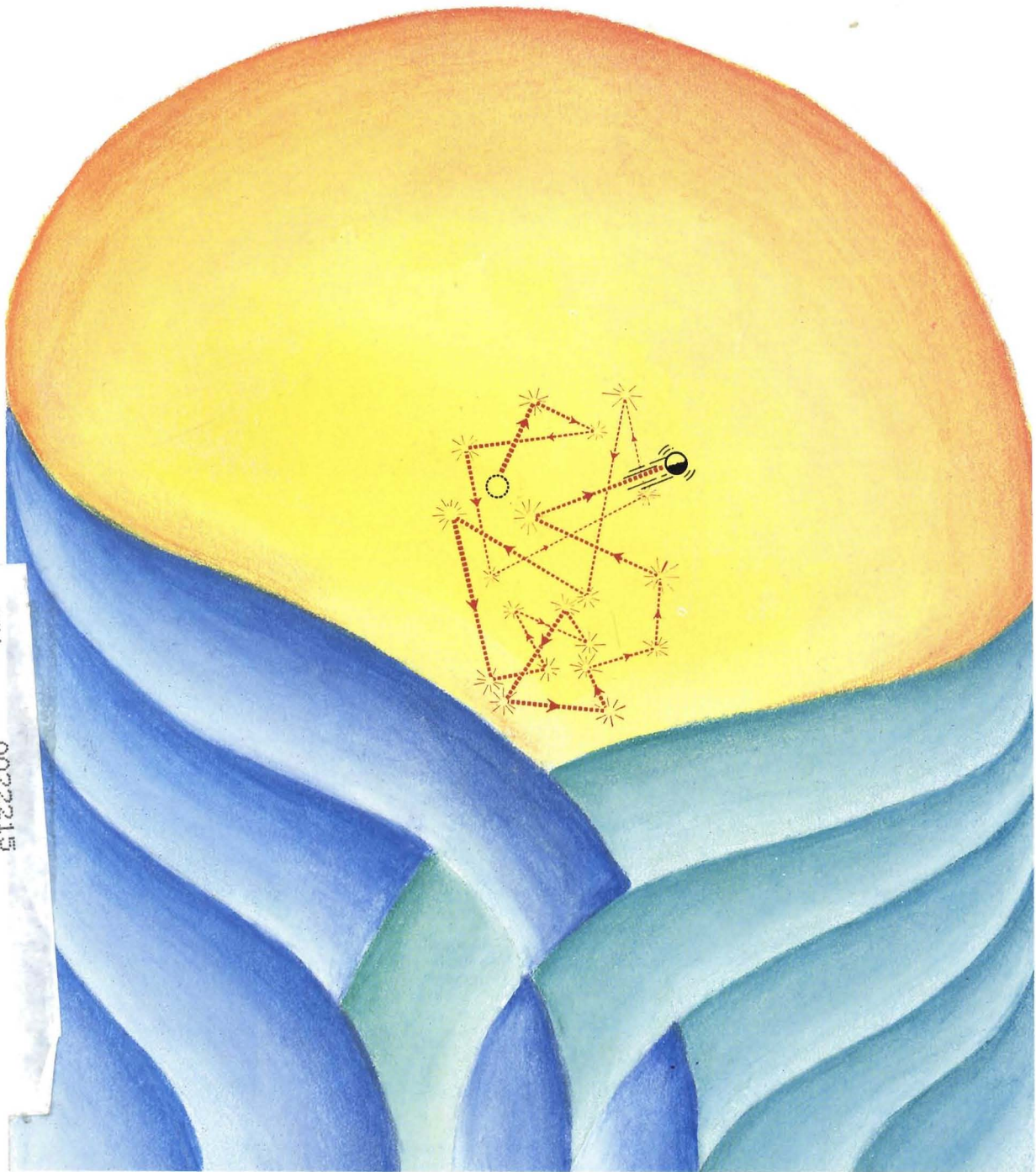


# ASDC

AMERICAN SOCIETY OF DENTISTRY FOR CHILDREN

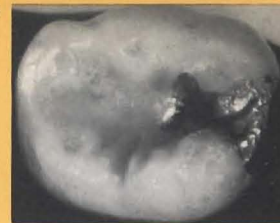SEPTEMBER-OCTOBER 1986

## JOURNAL OF DENTISTRY FOR CHILDREN



7MU 0022215  
DR. Milton I Haupt  
251 Maple St  
Englewood  
N.J. 07631

**FROM A BROWNIAN REACTION A NEW PROFILE  
OF PEDIATRIC DENTISTRY IS EMERGING**



# JOURNAL OF DENTISTRY FOR CHILDREN

Volume 53 Number 5 September-October 1986


Copyright 1986 by the American Society of Dentistry for Children—ASDC JOURNAL OF DENTISTRY FOR CHILDREN. USPS # 279-480. Issued bimonthly—in January-February, March-April, May-June, July-August, September-October, and November-December—at 211 E. Chicago Avenue, Suite 920, Chicago, IL. Second class postage paid at Chicago, IL and additional mailing office. Subscription prices: within U.S.A., individuals \$40.00 per volume, institution, \$50; Foreign (including Canada and Mexico) individual, \$50.00 per volume, institution, \$60; to members of the ASDC \$25.50 per volume (six issues per volume). Single copies \$12.50. Member—American Association of Dental Editors.

All copy and manuscripts for the journal should be sent directly to the Editorial Office, 730 Blaney Drive, Dyer, Indiana 46311, (219) 865-1184.

Prospective authors should consult "Information for Authors," which appears in the January and July issues. Reprints of this document may be obtained from the Editorial Office.

#### POSTMASTER

Change of address, subscriptions, advertising and other business correspondence should be sent to Executive Secretary, 211 E. Chicago Ave., Suite 920, Chicago, Illinois 60611.



The cover shows a formulation of the brownian movement superimposed on "the dawn of a new era." The forces that change the profile of a profession go largely unobserved, much like the molecular forces of liquids and gases that keep contained particles in continual motion, known as the brownian movement, and discernible only through a microscope. Design and art by Sharlene Nowak.

- |                           |  |
|---------------------------|--|
| <b>326 Abstracts</b>      | <b>336 Editorial</b>                   |
| <b>333 Annual Meeting</b> | <b>399 Index to advertisers</b>        |
| <b>324 Busy reader</b>    | <b>391 News</b>                        |
| <b>398 Classified ads</b> | <b>391 Nominating committee report</b> |

## SEALANTS

- 337 A survey of private dental practitioners' utilization of dental sealants in Washington state**

Robert C. Faine, DDS, MPH; Taylor Dennen, PhD

*More than 50 percent of current sealant users in the study sample began using sealants within the last three years.*

- 343 Assessment of marginal leakage of class II amalgam-sealant restorations**

Anna B. Fuks, CD; Rafael Grajover, PhD; Eliecer Eidelman, Dr. Odont, MSD

*The degree of leakage in these samples was minimal.*

## FLUORIDE RESEARCH

- 346 Acid-etching of caries-like lesions of enamel treated with acidulated phosphate fluoride: an *in vitro* study**

M. John Hicks, DDS, MS, PhD

*The mean depths of the surface zones were determined for both the control and treatment groups, as well as the mean loss of surface enamel for the treatment groups.*

- 354 The effect of fluoridated water on DMF scores of first permanent molars in mixed dentitions**

Eeva Linkosalo, LDS

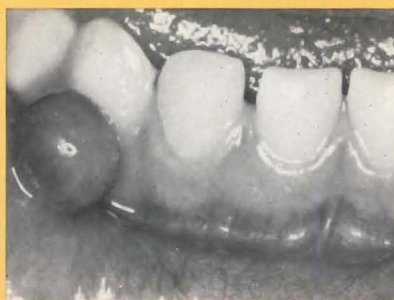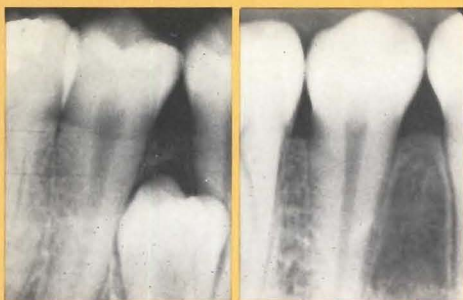*The health status of first permanent molars is studied in two groups of Finnish children.*

## CLINIC

- 359 Management of dental caries as an infectious disease**

Norman Tinanoff, DDS, MS; Roland Cantin, DMD

*With unlimited supplies of glucose or sucrose, the end product of plaque bacterial metabolism is lactic acid.*



**364 Consequences of endodontic treatment in primary teeth, Part I: A clinical and radiographic study of the influence of formocresol pulpotomy on the life-span of primary molars**

W.E. van Amerongen, DDS, PhD; G.R. Mulder, DDS; P.A. Vingerling

*The authors made paired comparisons of primary molars with and without formocresol pulpotomy.*

**371 The psychosocial aspects of adolescent pregnancy: a dental perspective**

Melanie S. Thwaites, DDS; Georgeta Manning Cox, DDS, MPH

*Adolescence, pregnancy, and visits to the dentists are each perceived by many to be stressful events—sometimes, they occur simultaneously.*

**375 Supernumerary mandibular premolar: the importance of radiographic interpretation**

Clara Turner, DMD; Clem J Hill, DMD

*In the permanent dentition, the presence of a supernumerary tooth often results in a variety of occlusal irregularities.*

**378 Eating disorders: anorexia and bulimia nervosa**

Karen B.W. Gross, RDH, MS; Kathleen M. Brough, RDH, MS; Patricia M. Randolph, PhD

*Eating disorders have become recognized as potential life-threatening illnesses with distinct physical and oral manifestations.*

## CASE REPORT

**382 A dental protocol for the pediatric cardiac transplant patient**

Robert A. Boraz, DDS

*A definitive dental protocol agreed to by the cardiac transplant team for the management of these patients is essential.*

**386 Bilateral lower lip mucoceles: cause of functional malocclusion in a three-year-old child**

John G. Meechan, BSc, BDS, FDSRCPS; G. Stewart Blair, BDS, DDS, FDSRCPS, HDD

*Both lesions had been present without obvious change in appearance since the child was a few days old.*

**388 Differential diagnosis of enlarged dental pulp chambers: a case report of amelogenesis imperfecta with taurodontism**

Richard P. Elzay, DDS; Dana H. Chamberlain, DDS

*The clinician should learn to recognize the plethora of conditions associated with large pulp chambers.*

### OFFICERS

Robert B. James . . . . . President  
Elliott J. Gordon . . . . . President-elect  
Prem S. Sharma . . . . . Vice-President  
Weldon W. Crompton Secretary-Treasurer  
George W. Teuscher . . . Executive Officer

### EDITORIAL STAFF

George W. Teuscher . . . . . Editor-in-Chief  
and Managing Editor  
Jane W. Teuscher . . . . . Assistant Editor  
730 Blaney Drive  
Dyer, Indiana 46311

### EDITORIAL AND PUBLICATIONS COMMISSION

Thomas K. Barber  
Donald F. Bowers  
Irving W. Eichenbaum  
Donald W. Kohn  
Ralph E. McDonald  
Prem S. Sharma  
Robert Spedding  
Paul P. Taylor

### EXECUTIVE COUNCIL

James N. Clark  
Peter J. Fos  
Alfred C. Griffin  
John N. Groper  
Frank L. Herbert  
Donald W. Kohn  
Ralph E. Lassa  
James T. Rundle

### EDITOR EMERITUS

Alfred E. Seyler

# For the busy reader

## **A survey of private dental practitioners' utilization of dental sealants in Washington state—page 337**

The effectiveness of sealants in protecting the occlusal surfaces of teeth has been demonstrated in many clinical investigations, yet many dentists in private practice have been slow to offer sealants to their patients. The majority of dentists (80.7 percent) who responded to the survey in Washington state are currently using sealants. There appears to be a relationship between the use of sealants and the organizational structure of the practice.

Requests for reprints should be directed to Dr. Robert C. Faine, 7015 SE 32nd Street, Mercer Island, WA 98040.

## **Assessment of marginal leakage of class II amalgam sealant restorations—page 343**

This study addresses the question of whether conservative methods of restoration may be applied efficaciously in permanent posterior teeth with proximal lesions and intact occlusal sealants. It evaluates the effect of *in vivo* experimental conditions on micro-leakage, using primary molars in this study, for information applicable to permanent molars.

Requests for reprints should be directed to Anna B. Fuks, C.D., The Hebrew University, Hadassah Faculty of Dental Medicine, P.O.B. 1172, Jerusalem, Israel.

## **Acid-etching of caries-like lesions of enamel treated with acidulated phosphate fluoride: an *in vitro* study—page 346**

Using the scanning electron microscope and the polarized light microscope, the effects of acid-etching on acidulated phosphate fluoride (APF)-treated caries-like lesions of enamel were investigated, with respect to the etching patterns produced and the suitability of those patterns for resin bonding, and the histopathological features of the caries-like lesions.

Requests for reprints should be directed to Dr. M. John

Hicks, c/o Dr. C.M. Flaitz, Pediatric Dentistry Associates, 5150 W. 80th Ave., Westminster, CO 80030.

## **The effect of fluoridated water on DMF scores of first permanent molars in mixed dentitions—page 354**

New aspects of the problem of estimating the differences in caries activity between groups living in towns with and without a fluoride supplement in the drinking water are considered in this report. Two groups of Finnish children born in 1963, living in two towns, formed the study and control groups. The results show that fluoridated water alone is not sufficient for an effective preventive regimen.

Requests for reprints should be directed to Dr. Eeva Linkosalo, Institute of Dentistry, University of Kuopio, Kuopio, Finland.

## **Management of dental caries as an infectious disease—page 359**

Dental caries is an infectious disease that demineralizes tooth structure as a consequence of bacterial metabolism. Chemical suppression of bacteria, especially using stannous fluoride, is gaining popularity because of its practicality and clinical efficacy.

Requests for reprints should be directed to Dr. Norman Tinanoff, Department of Pediatric Dentistry, University of Connecticut Health Center, Farmington, CT 06032.

## **Consequences of endodontic treatment in primary teeth, Part I: A clinical and radiographic study of the influence of formocresol pulpotomy on the life-span of primary molars—page 364**

The authors made paired comparisons of primary molars with and without formocresol pulpotomy. As no significant differences in life-spans were found between the 152 test teeth and their corresponding control teeth,

formocresol pulpotomy is a successful method of treating primary teeth with exposed pulp.

Requests for reprints should be directed to Dr. W.E. van Amerongen, Division of Pediatric Dentistry, Free University, Amsterdam. The Netherlands.

**The psychosocial aspects of adolescent pregnancy: a dental perspective—page 371**

This paper presents some of the psychological and social aspects of the adolescent who is pregnant, and how the combination of adolescence and pregnancy affect the dental management of these patients.

Requests for reprints should be directed to Dr. Melanie S. Thwaites, Howard University, College of Dentistry, 600 W. Street, N.W., Washington, DC 20059.

**Supernumerary mandibular premolar: the importance of radiographic interpretation—page 375**

The authors describe a patient, aged 10 years 9 months, in whom a mandibular supernumerary premolar developed late and was not diagnosed properly because of the lack of a thorough radiographic examination.

Requests for reprints should be directed to Dr. Clara Turner, J.H.M.H.C., Box J-426, Gainesville, FL 32610.

**Eating disorders: anorexia and bulimia nervosas—page 378**

From both ethical and legal standpoints, knowledge of the symptoms of eating disorders is imperative, since early diagnosis and treatment are directly related to successful therapy. This article provides the dentists with information to aid in the recognition, diagnosis, treatment, referral, and dental support of patients with eating disorders.

Requests for reprints should be directed to Ms Karen B.W. Gross, School of Dentistry, University of Missouri at Kansas City, 650 E. 25th Street, Kansas City, MO 64108.

**A dental protocol for the pediatric cardiac transplant patient—page 382**

Dental protocols are presented for the pediatric cardiac transplant patient, both pre-and postoperatively, and the case report of a three-year-old boy treated successfully is presented.

Requests for reprints should be directed to Dr. Robert A. Boraz, Associate Professor of Surgery and Pediatrics, University of Kansas Medical Center, 39th and Rainbow Blvd., Kansas City, KS 66103.

**Bilateral lower lip mucocoeles: cause of functional malocclusion in a three-year-old child—page 386**

The case report of a three-year-old girl is presented, who had two nontender, bluish, fluctuant swellings diagnosed as superficial mucocoeles present since the child was a few days old. The child had a unilateral crossbite with the mandibular midline shifted almost one tooth width to the left, a longstanding function adaptation producing malocclusion. The mucocoeles were surgically removed, and the cross-bite disappeared.

Requests for reprints should be directed to Dr. John G. Meechan, Department of Oral Surgery, The Dental School, Framlington Place, Newcastle Upon Tyne, NE 2 4BW, United Kingdom.

**Differential diagnosis of enlarged dental pulp chambers: a case report of amelogenesis imperfecta with taurodontism—page 388**

This paper reviews pathological conditions that are associated with enlarged pulp chambers. A case of amelogenesis imperfecta associated with taurodontism is presented as an example of one of the conditions with enlarged dental pulps.

Requests for reprints should be directed to Dr. Richard P. Elzay, Department of Oral Pathology and Genetics, University of Minnesota, School of Dentistry, 515 Delaware St., S.E., Minneapolis, MN 55455.

# A survey of private dental practitioners' utilization of dental sealants in Washington state

Robert C. Faine, DDS, MPH  
Taylor Dennen, PhD

## Sealants

Application of resin sealants for the prevention of dental caries in occlusal pits and fissures was first reported in 1967 by Cueto and Buonocore.<sup>1</sup> Since then, the effectiveness of sealants in protecting the occlusal surfaces of teeth has been demonstrated in many other clinical investigations.<sup>2-7</sup> While systemic and topical fluorides remain the cornerstone of any preventive dentistry program, fluoride appears to be less effective in reducing occlusal caries.<sup>8</sup> Children exposed to fluoride have experienced a marked decline in smooth surface caries; the incidence of occlusal caries, however, remains relatively high.<sup>9</sup> If sealants were used extensively in conjunction with fluoride therapy, the incidence of dental caries could be greatly reduced.

Although the safety and efficacy of sealants have been widely reported in the dental literature, private dentists have been slow in offering sealants to their patients.<sup>10-14</sup> According to a 1982 survey conducted by the American Dental Association Health Foundation, 57.7 percent of dentists in private practice offered sealant therapy.<sup>15</sup> Ninety percent of the dentists questioned felt that other preventive procedures such as tooth brushing and community water fluoridation were more effective in preventing caries.

At the conclusion of a Consensus Development Con-

---

Dr. Faine is Former State Dental Consultant Department of Social and Health Services State of Washington.

Dr. Dennen is Administrator Health Service Analysis, Department of Labor and Industries, State of Washington.

ference in 1983 sponsored by the National Institute of Dental Research, it was recommended that intensive efforts should be undertaken to promote the widespread adoption of pit and fissure sealants by private and public health care providers.<sup>16</sup>

## PURPOSE OF THE STUDY

- To determine how many dentists in Washington State are applying sealants.
- To determine the attitudes of dentists about sealant use and to ascertain the reasons why sealants were not being utilized.
- To obtain information on the fees dentists were charging to place sealants.
- To obtain comments on proposed guidelines or standards for sealant use.
- To identify methods of enhancing continuing education programs for dentists on sealant application.
- To find out how many dentists in the study sample accepted Medical Assistance patients.

## METHODS

Information sought by the survey included patterns of sealant use, costs of sealants, concerns about using sealants, continuing education needs on sealants, comments on proposed guidelines on sealant use put forth by third party payment plans, and practice characteristics.

Only general practitioners and pedodontists in private practice in Washington State were surveyed in April 1985. All retired dentists and specialists other than pedodontists were eliminated from the study sample by using the telephone yellow pages from each community and a directory published by the Washington State Dental Association.

Out of a total of 1,960 dentists eligible to receive the questionnaire, 941 were chosen through a random sampling technique. The questionnaire was sent to practitioners with a letter from the President of the Washington State Dental Association urging participation in the study. A total of 606 dentists (64.4 percent) responded by completing the survey form.

## RESULTS

### Sealant practice patterns

The majority of dentists (80.7 percent) who responded to the survey in Washington State are currently using

sealants. This is a remarkable increase in sealant use, compared to the 1974 nationwide figure of 38 percent, and the 1982 figure of 58 percent.<sup>17</sup> Of respondents who place sealants, 65 percent apply them to one to five patients per week, and only 2.5 percent to more than eleven patients per week.

When asked how long they have been using sealants, 31.5 percent reported their use for longer than three years; 33.5 percent for one to three years; and slightly under 20 percent, for less than a one-year period.

A majority of dentists, nearly 60 percent, were using a light-cured sealant, while 20 percent used a chemically cured sealant. It is not clear why the Washington dentists favored light-activated sealants by a three to one margin over the chemically cured type.

One of the objectives of the study was to determine the costs of sealants for state program planning purposes. A slight majority of the survey participants (50.8 percent) charged between \$10 and \$15 per tooth, which is close to the national average, \$11.14.<sup>18</sup> Almost 15 percent of the dentists charged under \$10 per sealant, 10 percent charged \$16 to \$20 and only 2 percent charged over \$21 for the procedure.

### Profile of practices surveyed

Responses were sorted by geographic and by dental practice characteristics, to identify patterns in the provision of sealants. The sorting characteristics were:

- Size of city where practice is located.
- Urban (SMA) versus rural (non-SMA) county of practice location.
- Group versus solo practice.
- Number of assistants and hygienists employed in the practice.
- Respondent age.
- Number of patients under the age of fifteen seen per week.

Use of sealants does not vary significantly according to practice location. In cities under 25,000 population, 81.7 percent of the respondents use sealants; in cities of 25,000 to 100,000 population, 85.9 percent use them, and 78.6 percent of those located in cities of over 100,000 population use them. Similarly, 82.7 percent of respondents in urban locations use sealants, while only slightly fewer, 78.4 percent of rural county dentists use sealants.

There does appear to be a relationship between use of sealants and the organizational structure of the practice. Among solo practitioners, 81.1 percent use sealants. For those in solo practices, but sharing services with another

practitioner, 85.6 percent use sealants. Dentists in partnership arrangements or those reporting they are employees are most likely to apply sealants, 88.2 percent.

The number of auxiliaries employed is also associated with use of sealants. Among dentists employing one assistant, 77.5 percent use sealants, compared with 100 percent of dentists practicing in offices with five or more assistants. Similarly, where there is no hygienist in the office, 73.1 percent of dentists apply sealants, while 100 percent of the dentists in practices employing four or more hygienists use sealants. Together with the fact that dentists in partnerships or functioning as employees are more likely to use sealants, this implies that greater use of sealants is associated with larger practices.

Age of respondents is strongly associated with use of sealants, as shown in the following table:

Respondent age:	Under 30	30-40	40-50	50-60	60 +
Percent using sealants:	96.7	92.8	86.2	65.1	47.5

Dentists that see a number of patients under the age of fifteen years, each week, also are more likely to provide sealants, as seen in the following table:

Number of patients under age fifteen years seen per week:	Under 10	10-14	15-19	20+
Percent using sealants:	74.3	86.8	85.1	88.2

### Attitudes about sealants

All respondents were asked to express their opinions on specific issues and concerns that might limit sealant use. When reviewing the responses on the sealant effectiveness issue (Table 1), only 14.3 percent of the dentists feel sealants are not retained very long. A large number of dentists, 62.7 percent, still fear sealing in decay. It would be difficult, however, to interpret this response as a reason why some dentists limit their use of sealants. Perhaps the most encouraging response in this segment is that 80.3 percent of the dentists believe sealants can be effective in preventing occlusal decay. This correlates closely with the total number (80.7 percent) who said they are using sealants.

Over 72 percent of the dentists surveyed thought that sealants were cost-effective (Table 2). This is an important perception, because, if the dental profession believes the procedure is cost-effective and scientifically effective, sealant use may increase rapidly in this country.

Only 14.2 percent stated they do not apply sealants, because third-party payment plans do not pay for them. This figure is almost similar to results reported by Call and Hicks in a Colorado survey, where 16.7 percent did

Table 1 □ Conditions that could limit the use of sealants.

Effectiveness issues	Percent				
	Strongly agree	Agree	Disagree	Strongly disagree	No opinion
Sealants are not retained very long	1.8	12.5	41.4	32.7	6.3
When a sealant is placed, decay may be sealed in	7.6	55.1	17.7	7.9	4.1
I would rather place an occlusal amalgam	5.3	12.7	35.1	37.3	4.0
I do not think they are effective in preventing occlusal decay	4.8	5.8	23.4	56.9	4.3
The use of sealants has not been substantiated by research	1.2	6.3	34.7	37.0	5.0

Table 2 □ The issues related to the cost of sealants.

Cost issues	Percent				
	Strongly agree	Agree	Disagree	Strongly disagree	No opinion
Sealants are not cost-effective	5.4	11.2	31.2	41.6	6.1
Patients are opposed to the cost of a sealant	2.3	8.3	43.6	29.0	12.0
I do not place sealants because third-party payment plans do not pay for them	1.2	13.0	36.0	23.4	10.4
It takes too much time for the cost of the procedure	1.7	10.7	43.2	23.4	6.4

Table 3 □ Questions regarding the use of sealants.

Application problems	Percent				
	Strongly agree	Agree	Disagree	Strongly disagree	No opinion
I am confused about the many types of sealants	0.7	10.2	36.1	28.1	10.4
My staff is not interested	0.7	1.0	36.6	38.6	7.9
Auxiliaries should not apply sealants	5.8	10.9	27.6	36.8	4.0
I am unfamiliar with the procedure of placing sealants	0.8	4.5	25.9	49.7	3.1

not use sealants, because they were not covered by insurance.<sup>19</sup> Many dentists (72.6 percent) feel that patients, if properly educated, are willing to pay for sealants and are placing them accordingly.

Washington dentists report that slightly over three-fourths (75.2 percent) of their dental staffs are interested in sealant use, while only 1.7 percent are not (Table 3). Almost two-thirds (64.4 percent) of the dentists approved of auxiliaries applying sealants. In Washington State, dental hygienists and dental assistants are permitted to place sealants. Only 5.3 percent of the dentists



said they were unfamiliar with the procedure. In the Colorado survey, 3.5 percent of the respondents indicated they were not familiar with sealant technology.

### Sources of information on sealant technology

The increase in sealant use in the United States has come about for several reasons. Since 1981, there have been four major conferences and forums on the status of sealant use and on recent research findings. Most of these meetings were well attended and the information was disseminated widely through a variety of professional journals, including the *Journal of the American Dental Association* and *Journal of Public Health Dentistry*.<sup>20-21</sup>

Newer generations of sealants are proving to be of high quality and show impressive retention results.<sup>22</sup> With more and more studies demonstrating the efficacy of sealants in reducing occlusal caries, additional practitioners seem willing to use them. The public is also being educated through informative articles featured in "popular" magazines.<sup>23</sup>

A question was asked in this survey about the sources of information about sealants. Most dentists gave multiple responses to this question. Dental journal articles were the most frequently mentioned source (48.2 percent) and were closely followed by continuing education courses (41.4 percent). Schools of dentistry were cited by 16 percent of the respondents and dentists sharing knowledge with each other accounted for 10 percent of the total sample.

When asked about the preferred method of obtaining information on sealant technology, the dentists selected dental journal articles as their first choice (46.5 percent). Over one-third (38.0 percent) would like an opportunity to attend a continuing education course in their own community. State and national dental meetings rated a 14 percent response and 7 percent of the dentists said they were not interested in receiving any more information.

### Sealants standards

In January 1985, the *Journal of the American Dental Association* published proposed standards for the use of sealants.<sup>24</sup> These standards are intended to provide guidance to dental professionals and to define conditions that will enable third-party carriers and purchasers to feel comfortable about paying for sealants. Some carriers have expressed concern that dentists may use them indiscriminately. Respondents were asked to

Table 4 □ Proposed standards related to the use of sealants.

	Agree	Disagree
	Percent	
Sealants should be applied only to the occlusal pits and fissures of permanent 1st and 2nd molars	25.0	57.0
Teeth to be sealed must be free of proximal caries	76.4	8.1
Sealants should be restricted to children six to fourteen years of age	28.2	55.4
There can be no previous restorations on the surface to be sealed	52.3	31.2
Only colored or white sealants should be used	61.4	25.7

comment on some of the proposed guidelines or standards on sealant use (Table 4).

Although over half (57 percent) of the dentists disagreed with the statement that sealants should only be applied to the pits and fissures of permanent 1st and 2nd molars, it should be noted that most of the occlusal decay of permanent teeth is found on permanent molars, not on the premolars. Some restrictions may become necessary as there is increased competition for health care funds available through group purchasers.

There is a high level of agreement (76.4 percent) that sealants should not be placed on teeth with proximal decay. This is a straightforward standard as indicated by the large number agreeing with it but probably should be expressed to discourage inappropriate sealant use.

On the issue of age restrictions for sealant application, many dentists (55.4 percent) did not want to limit use to six to fourteen-year-old children. This age segment is the high-risk period for children who may develop pit and fissure caries without sealant intervention.

In Washington State, the Division of Medical Assistance has begun paying for dental sealants and one feature of the program is that dentists must use colored or white sealants. This requirement has the approval of 61.4 percent of the dentists. Approximately two-thirds (66 percent) of the dentists surveyed are treating medical assistance patients.

Other comments were solicited and 123 individuals presented additional remarks to the open-ended questions. Many dentists like the concept of using "white" sealants because they could be identified and checked easily at recall visits.

### DISCUSSION AND SUMMARY

In Washington State, 80.7 percent of dentists surveyed are applying sealants either routinely or on a limited

basis. A nation-wide study recently conducted by the University of Maryland revealed that among general dentists, over 75 percent of the respondents had attempted using sealants and of those dentists, 90.4 percent were still using them.<sup>25</sup> A study of Colorado dentists showed that approximately 70 percent of practitioners utilize sealants with 40.1 percent applying them routinely and 32.6 percent occasionally.

These recent surveys demonstrate that sealant use is on the increase, when compared to 38 percent in 1974 and 58 percent in 1982; many dentists still do not provide sealants, however, as a routine preventive service. Age of dentists is strongly associated with the delivery of sealants, as 96.7 percent of dentists under thirty years of age use them, compared with 47.5 percent of dentists over age sixty. Also, 88.2 percent of dentists in partnerships, groups or salaried dentists report using sealants. In the Washington State study, dentists in larger practices applied sealants more frequently than dentists in solo practices.

The number of auxiliaries employed is directly associated with a greater use of sealants. The greater the number of auxiliaries in a practice, the greater the use of sealants.

It is interesting to note that over 50 percent of current sealant users in the study sample began using sealants three years ago or less. This increase in use undoubtedly reflects the wide dissemination of sealant information through professional journals, conferences, and the news media. There should be continued emphasis on this topic so additional dentists will participate in the delivery of sealants.

Journals appear to be a convenient medium for providing information to Washington dentists. In the past two years, an increased number of sealant articles have been published and a greater editorial emphasis has been given to the utilization of sealants.

A large majority of dentists (80.3 percent) reported they believe sealants can be effective in preventing occlusal caries. If dentists feel confident that sealants are effective, they will be used with greater frequency and by more practitioners. Over 72 percent of those surveyed thought that sealants were cost-effective.

One dentist in ten was of the opinion that patients are opposed to paying for sealants and 14.2 percent do not place sealants because third-party payment plans do not pay for them. As consumer knowledge about sealants increases, it is anticipated that demand will also increase. A 1983 study of third-party payers revealed that nineteen of forty-nine commercial carriers provided reimbursements for sealants and only three of sixteen

Blue Cross and Blue Shield Association plans included funding for sealants.<sup>26</sup> The coverage for sealants was conditional in twelve of the nineteen commercial carriers who did pay for sealants. Some of the conditions mentioned were: age limits, use on permanent teeth only, and no existing decay in the teeth that were to receive sealants. It appears that the dental profession will have to provide leadership on the issue of third-party payment and work closely with the carriers to encourage and even demand that sealants be part of the preventive services offered.

Washington State dentists disagreed with restricting sealant use to permanent first and second molars and also did not want to limit sealants to children six to fourteen years of age. Perhaps they wanted more discretion in deciding who should receive sealants, and in which teeth they should be used.

There has been extensive debate during the past five years on who will pay for sealants. Third party carriers have not been very enthusiastic about paying for them or even encouraging group purchasers to include sealants as a benefit.<sup>27,28</sup> To date, only ten state medical assistance programs provide sealants as a service. Clearly, a lot of education and promotional work must be accomplished, if sealants are to become a popular benefit among the purchasers of prepaid dental care.

## REFERENCES

1. Cueto, E.I. and Buonocore, M.G.: Sealing of pits and fissures with an adhesive resin: its use in caries prevention. *JADA*, 75:121-128, July, 1967.
2. Ripa, L.W. and Cole, W.W.: Occlusal sealing and caries prevention: results 12 months after a single application of adhesive resin. *J Dent Res*, 49:171-173, January-February, 1970.
3. Mertz-Fairhurst, E.J. *et al*: A comparative study of two pit-and-fissure sealants: results after 4.5 years in Augusta, GA. *JADA*, 103:235-238, August, 1981.
4. Horowitz, H.S.; Heifetz, S.B.; Poulsen, S.: Adhesive sealant clinical trial: an overview of results after four years in Kalispell, Montana. *J Prev Dent*, 3:38-49, May-June, 1976.
5. Simonsen, R.J.: The clinical effectiveness of a colored pit-and-fissure sealant at 36 months. *JADA*, 102:323-327, March, 1981.
6. Going, R.E. *et al*: Four-year clinical evaluation of a pit-and-fissure sealant. *JADA*, 95:972-981, November, 1977.
7. Cons, N.C.; Pollard, S.T.; Leske, G.S.: Adhesive sealant clinical trial: results of a three-year study in a fluoridated area. *J Prev Dent*, 3:14-29, May-June, 1976.
8. Stamm, J.W.: Is there a need for dental sealants?: Epidemiological indications in the 1980's. *J Dent Ed*, 48:9-17, February, 1984.
9. Graves, R.C. and Burt, B.A.: The pattern of the carious attack in children as a consideration in the use of fissure sealants. *J Prev Dent*, 2:28-34, May-June, 1975.
10. Gwinnet, A.J.: Pit-and-fissure sealants: an overview of research. *J Pub Health Dent*, 42:298-304, Fall, 1982.
11. Gift, H.C.; Frew, R.; Hefferren, J.J.: Attitudes toward the use of pit-and-fissure sealants. *J Dent Child*, 42:460-466, November-December, 1975.

12. Jerrell, R.G. and Bennett, C.G.: Utilization of sealants by practicing pedodontists. *J Pedodont*, 8:378-386, Summer, 1984.
13. Ripa, L.W.: Occlusal sealants: an overview of clinical studies. *J Pub Health Dent*, 43:216-223, Summer, 1983.
14. Horowitz, A.M. and Frazier, P.J.: Issues in the widespread adoption of pit-and-fissure sealants. *J Pub Health Dent*, 42:312-323, Fall, 1982.
15. American Dental Association: The role of the health professional in the delivery of caries prevention. ADA: Health Foundation, December, 1983.
16. National Institutes of Health: Consensus development conference statement on dental sealants in the prevention of tooth decay. *JADA*, 108:233-236, February, 1984.
17. Gift, H.C. and Frew, R.A.: Sealants: changing patterns. *JADA*, 112:391-392, March, 1986.
18. Bureau of Economic and Behavioral Research: Dental fees charged by general practitioners and selected specialists in the United States. 1982. *JADA*, 108:83-87, January, 1984.
19. Call, R.L. and Hicks, M.J.: Sealant utilization patterns and attitudes among Colorado dentists. Paper presented at AADR, Washington, D.C., 1986.
20. Pit and fissure sealant use: an issue explored. Report. *JADA*, 108:310-322, March, 1984.
21. Proceedings of a forum on the use of fissure sealants in public health programs. *J Pub Health Dent*, 43:198-254, Summer, 1983.
22. Mertz-Fairhurst, E.J. *et al*: A comparative clinical study of two pit and fissure sealants. Six-year results in Augusta, GA. *JADA*, 105:237-239, August, 1982.
23. Tooth decay: the early problem. *Consumer Reports*, 49:130-132, March, 1984.
24. Council on Dental Research: Cost-effectiveness of sealants in private practice and standards for use in prepaid dental care. *JADA*, 110:103-107, January, 1985.
25. Doherty-LaBelle, A.; Romberg, E.; Cohen, L.: Pit and fissure use by pedodontists in private practice. Paper presented at AADR, Washington, D.C., 1986.
26. Glasrud, P.H.: Insuring preventive dental care: are sealants included? *Am J Public Health*, 75:285-286, March, 1985.
27. Fields, J.F.: Third party carrier's role in sealant use - delta dental plans. Conference on pit and fissure sealants: Why their limited usage? Chicago: American Dental Association, 1981.
28. Daun, L.: Third party carrier's role in shaping the delivery of dental services—pit and fissure sealants. Conference - *Am Assoc Public Health Dent*. San Francisco, 1985.

---

#### DEPARTMENT OF PEDODONTICS AND ORTHODONTICS

The results of an analysis of clinical procedures accomplished by third-year dental students in a children's dentistry (pedodontic and orthodontic) clinic demonstrate that a change in the pattern of care has occurred during the nine-year period from 1976 to 1985. Fewer restorations are being placed and more procedures not associated with caries sequelae are being performed. Similar findings from three dental schools located in the northeastern, southeastern, and north central regions of the United States suggest that the observed changes are not regional and probably are associated with the nationwide decline in caries prevalence that has been reported by the National Institute of Dental Research (*J Dent Res*, 1982, pp 1346-1351).

As more patients with less disease entered the care system, students provided more primary preventive services and also placed more orthodontic appliances. During the nine years surveyed, there was a 66 percent increase in appliances placed. This greater emphasis on tooth guidance and interceptive orthodontics represents a major shift in the type of care provided.

Greater emphasis should be placed on teaching appliance therapy in children. In the Children's Dentistry Department at Stony Brook there was a natural evolution toward increased appliance therapy as restorative care decreased and more children entered the system. This evolution was facilitated by the joint pedodontic-orthodontic nature of the department. At other schools, an adjustment in clinical curriculum time between the pediatric dentistry and orthodontic departments might be necessary. The changing dental care pattern in children, however, also provides the impetus to consider combining pedodontics and orthodontics into a single department to accomplish the most efficient delivery of care to children.

Ripa, L.W.: Change in care patterns  
in a dental school children's dentistry clinic. *J Dent Educ*, 50: 309-311, 1986.

---

# Assessment of marginal leakage of class II amalgam-sealant restorations

Anna B. Fuks, CD  
Rafael Grajover, PhD  
Eliecer Eidelman, Dr Odont, MSD

**T**he effectiveness of fissure sealants for the prevention or treatment of incipient caries lesions was demonstrated in numerous studies.<sup>1-6</sup> For larger occlusal lesions, a conservative technique, involving the removal of carious tooth structure only, was proved to be clinically successful.<sup>4-6</sup> Prevention of secondary caries in this technique is achieved by sealing the composite resin restoration, rather than extending the cavity preparation. Composite resins have been recommended for class II restorations in primary molars with a "life expectancy" shorter than three years.<sup>7</sup> No resin, furthermore, has been shown to be as durable as amalgam, for use in posterior class II restorations.<sup>8</sup>

The question arises whether conservative methods of restoration may be efficaciously applied in permanent posterior teeth with proximal lesions. The object of this investigation was to answer this question for a specific kind of case: namely for teeth with intact occlusal sealants on which proximal decay was diagnosed. Instead of conventional class II restorations, proximal amalgam restorations were to be prepared with a conservative lock, replacing only part of the sealant and forming an interface with this material. The results of *in vitro* leak-

age tests of amalgam-sealant restorations were favorable, but the applicability of *in vitro* tests to *in vivo* conditions is always questionable.<sup>9-13</sup> It is difficult to simulate the attrition and wear that occur in the oral cavity, and to estimate to what extent differences in wear, thermal expansion, strength and modulus of elasticity between amalgam and sealant would affect the interface between these materials *in vivo*. Placement of the restorations *in vivo* was, therefore, of primary importance for relevant test conditions. The analyses of leakage, however, can only be carried out *in vitro*. These experimental requirements could only be realized by using primary teeth. The investigation was, therefore, carried out on primary teeth, although the conclusions were intended for application to permanent teeth.

## METHODS AND MATERIALS

### Selection of teeth

All treatments were performed by the principal author (ABF). Informed consent was obtained from the parents. Preoperative bitewing radiographs were taken of sixth grade children, 10.5 to 11.5 years of age. Ten children who had primary molars with proximal decay, intact occlusal surfaces in contact with antagonists, and resorption of at least half the length of their roots, were selected for treatment.

Dr. Fuks is Senior Lecturer, Department of Pedodontics; Dr. Grajover is Associate Professor and Head, Unit for Dental Materials; Dr. Eidelman is Associate Professor and Chairman, Department of Pedodontics, The Hebrew University, Hadassah Faculty of Dental Medicine, P.O.B. 1172, Jerusalem, Israel.

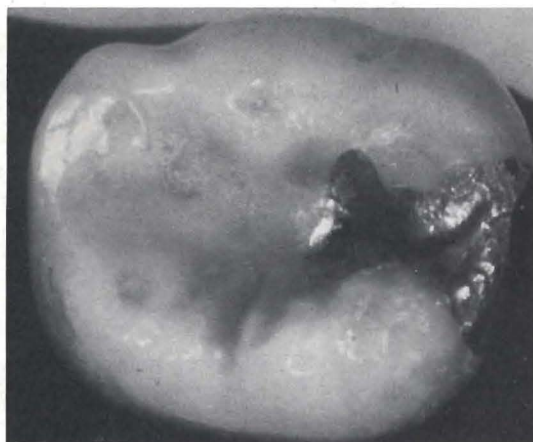


Figure 1. Exfoliated primary molar restored with sealant-amalgam, before placement into the dye. Notice the conservative occlusal lock.

### Cavity preparation and restorative procedures

The teeth were anesthetized and isolated with a rubber dam. Occlusal surfaces were cleaned with an aqueous slurry of pumice, using a rubber cup at slow speed. The teeth were then washed, etched, and sealed with Dclon\*, following the manufacturer's instructions. After polymerization, retention of the sealant was checked by attempting to pry it off the tooth surface with an explorer. Conservative class II cavity preparations were made, using a 330 bur in a high-speed, water-cooled handpiece. Proximal boxes were cut, following a standard design recommended by Project Tapp.<sup>14</sup> The outline of the occlusal lock was limited to a dove-tail large enough to keep a proportioned lock-box ratio and to provide retention of the restoration. The pulpal floor was prepared just below the dentinoenamel junction (Figure 1).<sup>14</sup> The cavity preparations were washed thoroughly, and dried with compressed air. A calcium hydroxide lining (Dycal)\*\* was then applied, and a T-band matrix contoured and wedged before insertion of the restoration. Amalgam\*\*\* restorations were placed in the cavities and the margins were burnished with a small ball burnisher. After forty-eight hours, the restorations were finished, using pear-shaped finishing burs, to approximately 1 mm from the amalgam-sealant junction. The children were given a prize token every time they came for removal of a loose restored tooth or would bring a tooth after its natural exfoliation.

Twenty-two of the thirty-two teeth in which combined amalgam-sealant restorations had been prepared,

\* Johnson & Johnson, 20 Lake Drive, East Windsor, NJ

\*\*The L.D. Caulk Company, Milford, DE 19963

\*\*\* Silver Star 70, Silmet - POB 812, Givatayim, Israel.

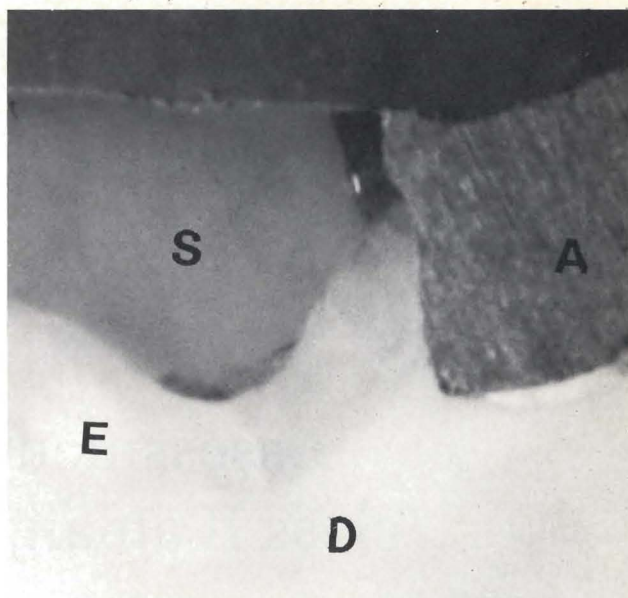


Figure 2. Photograph of a longitudinal section of an amalgam-sealant restoration. Note that the penetration of the dye is limited to the sealant-amalgam interface (arrow). S = Sealant; A = Amalgam, E = Enamel; D = Dentin. x40.

were recovered. Four of these restorations were in the mouth for approximately six months and the remaining eighteen functioned for periods varying from one to 1.5 years. Twelve exfoliated teeth with conventional class II amalgam restorations were used as controls. The latter were done in the same school clinic, using the same type of amalgam, and functioned for three to four years.

### Dye penetration procedure

The surfaces of the teeth were entirely covered with nail polish with the exception of the amalgam-sealant interfaces of the experimental teeth and the amalgam-enamel interfaces in the control group. The cervical ends of teeth with resorption up to the pulp chamber were covered with self-curing acrylic. The teeth were also covered with a layer of melted utility wax and a second layer of nail polish.<sup>15</sup> The triple-coated teeth were immersed in a 2 percent solution of basic fuchsin for twenty-four hours. After removal from the dye, the coatings were peeled from the teeth and, where necessary, scraped. The teeth were then thoroughly washed, dried and embedded in acrylic resin. Mesiodistal sections were obtained by grinding the embedded teeth longitudinally. These sections were examined and photographed under a dissecting microscope. The procedure of grinding and inspection was repeated, to allow analyses of at least five sections of each tooth.

### RESULTS

The results of the leakage tests are summarized in the Table. Dye penetration was observed in only two experimental samples and in one control sample. The

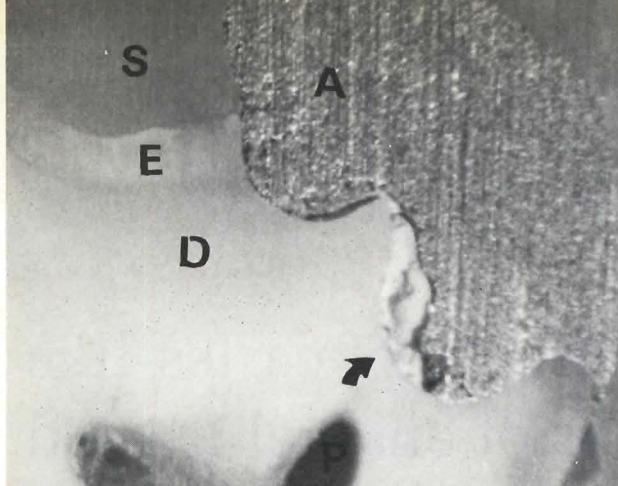


Figure 3. Photograph of a longitudinal section of another amalgam-sealant restoration. Notice the absence of dye penetration and the butt-joint between the sealant (S) and the amalgam (A). The cavity liner is partially missing (arrow) due to the grinding process. E = Enamel; D = Dentin; P = Pulp. x 40.

degree of leakage in these samples was minimal, and dye penetration was limited to the sealant-amalgam interface or amalgam-enamel interface, but did not reach the dentin (Figure 2). Adaptation of the amalgam to the sealant was good in most teeth (Figure 3). Voids at the interface were not observed at a magnification of x40, even in the samples that showed leakage (Figures 2 and 3). Steps at the margin of the amalgam-sealant interface were not observed. This indicates that wear of the sealant at the interface margin was not greater than that of amalgam, after 1.5 years.

## DISCUSSION

The marginal leakage of combined amalgam-sealant restorations was tested *in vitro* by means of dye penetration.<sup>9</sup> A good marginal adaptation was observed with total absence or only minimal penetration of the dye in over 80 percent of the samples. Similar or better results were obtained in the present study, since marginal leakage, when present, was minimal. Most studies on penetration of dyes have been made *in vitro*. McCurdy and co-workers observed a good correlation between *in vitro* and *in vivo* findings, when studying marginal leakage, and concluded that *in vitro* tests would be appropriate for screening marginal leakage of dental materials.<sup>16</sup> Other investigators, however, found that dye penetration was less pronounced under *in vitro* conditions.<sup>10,11</sup> In a review of microleakage, Jodaikin concluded that no direct comparison can be made between *in vitro* and *in vivo* microleakage experiments.<sup>13</sup> The present investigation evaluates the effect of *in vivo* experimental conditions on microleakage. There is no reason to suggest that the information concerning the amalgam-sealant interface, which was obtained on primary molars in this study, would not be applicable to permanent molars. Data in the literature indicate that the enamel-sealant bond strength for permanent teeth

Table 1 Assessment of marginal leakage by depth of dye penetration.

	Number of teeth examined	Teeth with marginal leakage	
		Number	Percent
Experimental group	22	2	9.1
Control group	12	1	8.3

is at least as high as for primary teeth.<sup>17</sup> The results, therefore, indicate by extrapolation, that conservative proximal amalgam fillings would be successful in permanent molars with intact sealants. Information is needed, however, regarding the long term wear and leakage of this type of restoration. Long term follow-up studies of conservative class II sealant-amalgam restorations, placed in permanent molars with good intercuspation, could provide this information. Some restorations of this type are already being tested clinically.

## REFERENCES

- Mertz-Fairhurst, E.J.; Fairhurst, C.W.; Williams, J.E. *et al*: A comparative clinical study of two pit and fissure sealants: six-year results in Augusta, GA. *J Am Dent Assoc*, 105:237-239, August, 1982.
- Haupt, M. and Shey, Z.: The effectiveness of fissure sealant after six years. *Pediatr Dent*, 5:104-106, June, 1983.
- Simonsen, R.J.: The clinical effectiveness of a colored sealant at 36 months. *J Am Dent Assoc*, 102:323-327, March, 1981.
- Simonsen, R.J.: Preventive resin restorations: three year results. *J Am Dent Assoc*, 100:535-539, April, 1980.
- Haupt, M.; Eidelman, E.; Shey, Z. *et al*: Occlusal composite restorations: 4 year results. *J Am Dent Assoc*, 110:351-353, March, 1985.
- Mertz-Fairhurst, E.J.; Newcomer, A.P.; and Callsmith, K.M.: Caries arrestment and prevention by sealed conservative filled resin restorations. *J Dent Res* (special issue), 62:478, 1983.
- Nelson, G.V.; Osborne, J.W.; Gale, E.N. *et al*: A three-year clinical evaluation of composite resin and a high copper amalgam in posterior primary teeth. *J Dent Child*, 47:414-418, November-December, 1980.
- Alberts, J.F.: *Tooth colored restoratives*. Cotati, CA: Alto Books.
- Fuks, A.B. and Shey, Z.: *In vitro* assessment of marginal leakage of combined amalgam-sealant restorations on occlusal surfaces of permanent posterior teeth. *J Dent Child*, 50:425-429, November-December, 1983.
- Loiselle, R.J.; Goldberg, A.F.; Gross, R.L. *et al*: Marginal microleakage - an *in vivo* assessment. *J Am Dent Assoc*, 78:758-760, April, 1969.
- Stuever, C.H.; Goldberg, A.F.; and Gross, R.L.: The effect of pulpal tissues on microleakage around dental restorations. *Oral Surg*, 31:568-570, April, 1971.
- Going, R.E.: Microleakage around dental restorations: a summarizing review. *J Am Dent Assoc*, 84:1349-1357, June, 1972.
- Jodaikin, A.: Experimental microleakage around aging dental amalgam restorations: a review. *J Oral Rehab*, 8:517-526, November, 1981.
- Project TAPP - Cavity preparation for primary teeth. Quercus Corporation, pp 53-79, 1978.
- Fuks, A.B.; Grajower, R.; and Shapira, J.: *In vitro* assessment of marginal leakage of sealants placed in permanent molars with different etching times. *J Dent Child*, 51:425-427, November-December, 1984.
- McCurdy, C.R.; Swartz, M.L.; Phillips, R.W. *et al*: A comparison of *in vivo* and *in vitro* microleakage of dental restorations. *J Am Dent Assoc*, 88:592-602, March, 1974.
- Doyle, W.W. and Brose, J.A.: A five-year study of the longevity of fissure sealants. *J Dent Child*, 45:127-129, March-April, 1978.

The authors express their appreciation to Mrs. Esther Sadovnik for her excellent technical work.

## Acid-etching of caries-like lesions of enamel treated with acidulated phosphate fluoride: an *in vitro* study

M. John Hicks, DDS, MS, PhD

The surface zone of enamel caries has been shown to be an intact layer of enamel that is approximately 25 to 30  $\mu\text{m}$  in depth.<sup>1,2</sup> Its histological structure appears very similar to that for sound enamel despite a pore volume of 10 to 50 times that for sound enamel. The pore volume for the surface zone has been shown to be typically between 1 percent and 5 percent, whereas sound enamel has a pore volume of 0.1 percent. The surface morphology and integrity of sound enamel and the early lesion of enamel are very similar, with a slight increase in the number of prism markings observable in the enamel lesion.<sup>3,4</sup> The surface zone of enamel overlies the body of the lesion that represents the area of greatest demineralization in the enamel lesion, with a minimal pore volume of 5 percent at its periphery and usually a pore volume in excess of 25 percent in its central portion.

Remineralization of enamel lesions with oral fluids and synthetic calcifying fluids has been shown to occur both *in vitro* and *in vivo*.<sup>5-10</sup> The process, however, requires relatively lengthy and numerous treatments. It has been suggested that although the intact, relatively unaffected surface zone may provide protection from cavitation for the underlying lesion, it may impede the

---

Dr. Hicks is Assistant Professor and Director of Basic Sciences in Dentistry, Dental Research Unit and Department of Growth and Development, School of Dentistry, University of Colorado Health Sciences Center, Denver, CO 80262.

Supported by National Institute for Dental Research, New Investigator Award 5R23 DE06829-03.

process of remineralization. Acid-etching of enamel lesions has been suggested as a means to render the surface zone slightly porous while maintaining its integrity.<sup>3,11</sup> The effects of acid-etching on enamel lesions are similar to those seen with sound enamel:

- Loss of surface enamel.
- Creation of a qualitative porous zone.
- Formation of etching patterns suitable for resin bonding.<sup>3,11-16</sup>

If the acid-etching technique could be used in conjunction with fluoride treatment, it may be possible to allow the caries lesion of enamel to receive the caries-resistant benefits provided by both fluoride treatment and sealant placement.

The purpose of this study, using the scanning electron microscope and the polarized light microscope, was to evaluate the effects of acid-etching on acidulated phosphate fluoride (APF)-treated caries-like lesions of enamel with respect to:

- The etching patterns produced and the suitability of those patterns for resin bonding, based upon morphological characteristics.
- The histopathological features of the caries-like lesions.

## MATERIALS AND METHODS

### Caries-like lesions formation

Thirty-six caries-free human molar and premolar teeth were cleaned thoroughly with a fluoride-free prophylaxis paste, using a slow-speed handpiece. An acid-resistant varnish was applied to each tooth, leaving windows of sound enamel exposed on the buccal and lingual surfaces (Figure 1). These windows were approximately 1 mm in height, occlusocervically, and 4 mm in width, mesiodistally. Each tooth had four windows of exposed sound enamel. Caries-like lesions were created in sound enamel, using an acidified gelatin gel brought to pH 4.0 by the addition of lactic acid. This artificial caries system creates lesions in enamel that are histologically indistinguishable from naturally occurring caries lesions.<sup>17</sup> After a twelve-week exposure to the gel, caries-like lesion formation occurred and longitudinal ground sections were prepared from the specimens to serve as controls.

### Acidulated phosphate fluoride treatment

Before treatment with the APF solution, the cut surfaces of the tooth-halves were varnished, to prevent any

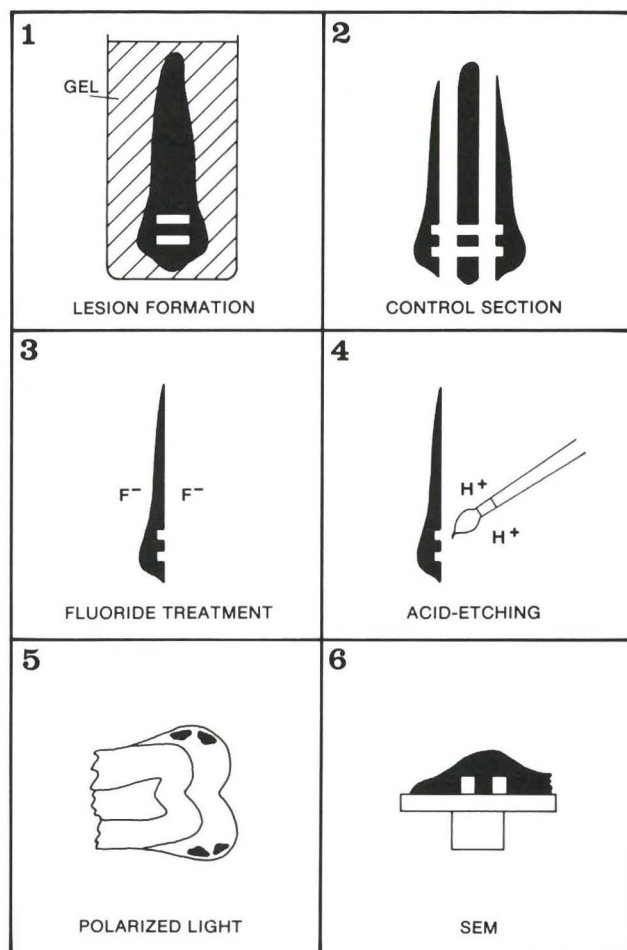


Figure 1. Experimental design.

contact between the cut surfaces of the lesions and the fluoride solution. The tooth-halves with caries-like lesions were then exposed to a freshly prepared, 1.23 percent APF solution (20 ml/tooth-half) for a single, 4-min treatment period. This treatment was followed by two consecutive, 5-min rinses in deionized/distilled water (20 ml/tooth-half) to remove any readily soluble reaction products. Five additional tooth-halves with caries-like lesions were exposed to the fluoride solution and water rinses. These tooth-halves with a total of ten lesions were prepared for scanning electron microscopic (SEM) examination, to determine whether coatings existed on the surfaces of the lesions treated only with the APF solution.

### Acid-etching procedure

The tooth-halves were examined to determine whether the acid-resistant varnish protecting the cut faces of the



lesions was intact following fluoride treatment; and where necessary, varnish was reapplied before the acid-etching procedure. The tooth-halves were then divided into twelve separate groups according to the concentration of phosphoric acid used as the etching solution and the period of exposure. The concentrations of phosphoric acid used were 20, 30, 40 percent, unbuffered, and 50 percent, buffered with 7 percent zinc oxide. The exposure periods were 30 s, 1 min and 2 min. The lesions were etched with the appropriate concentration of phosphoric acid for the appropriate exposure period. The etching solutions were applied to the surfaces of the lesions with sable's hair brushes, using a gentle painting motion for the entire application period. The specimens were then washed with deionized/distilled water for 60 s, followed by drying with a gentle stream of compressed air for an additional 60 s. Ground sections were prepared from the tooth-halves for polarized light examination. The remaining portions of the tooth-halves were prepared for SEM examination.

Ground sections from the control lesions and the etched lesions pretreated with APF were examined by polarized light microscopy after imbibition with water. Two zones of enamel caries can be seen, when a lesion is viewed in water: the negatively birefringent surface zone and the positively birefringent body of the lesion.<sup>17</sup> Ten lesions were examined for each of the twelve treatment groups and compared with their control lesions. The mean depths of the surface zones were determined for both the control and treatment groups, as well as the mean loss of surface enamel for the treatment groups.

SEM examination was carried out on ten lesions from each of the treatment groups, to determine the treatment effect on the surface topography of the caries-like lesions. The etching patterns were evaluated for the treated specimens and considered to be acceptable for resin bonding, if the patterns appeared to be comparable to those described previously for etched sound enamel (types 1, 2 and 3 etching patterns).<sup>12,13</sup> In addition, ten lesions that had been treated only with APF and washed were examined, to determine whether coatings were present on the surfaces of the lesions.

## RESULTS

### Polarized light microscopic results

Loss of enamel from the surface zone due to acid-etching was determined (Figure 2). Surface losses ranged from 5  $\mu\text{m}$  to 6  $\mu\text{m}$  for all phosphoric acid concentrations

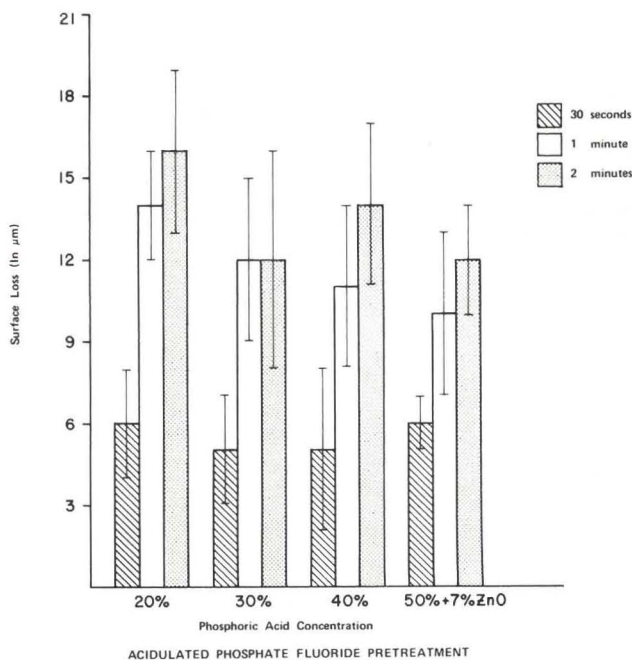


Figure 2. Histogram of mean surface loss ( $\bar{X} \pm SD$ ) due to acid-etching of APF-treated, caries-like lesions of enamel. ( $N = 10$  lesions per etch time).

using an exposure time of 30 s. With an exposure time of 1 min, the mean surface losses varied from 10  $\mu\text{m}$  to 14  $\mu\text{m}$  with the buffered etching solution having the lowest mean value. With a 2 min etching period, mean surface losses ranged from 12  $\mu\text{m}$  to 16  $\mu\text{m}$ . The greatest loss of enamel from the surface zones occurred, when lesions were etched with 20 percent phosphoric acid for a 2 min period.

The mean depth of surface zones for the control lesions was 27  $\mu\text{m}$  (Figure 3). The mean depth of surface

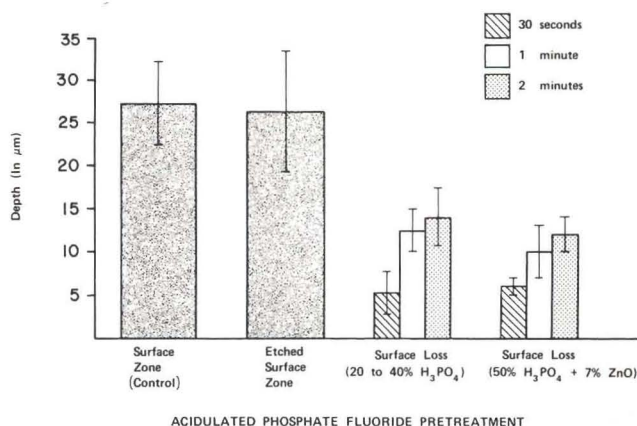


Figure 3. Histogram of mean depths ( $\bar{X} \pm SD$ ) for control and etched surface zones, and surface losses due to acid-etching APF-treated, caries-like lesions of enamel ( $N = 120$  lesions).

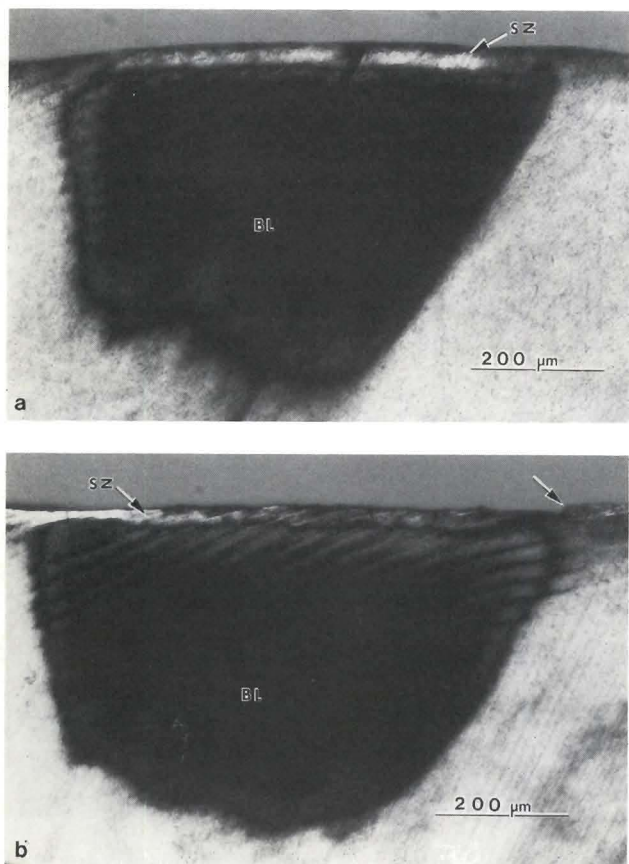


Figure 4. Polarized light appearance of a caries-like lesion prior to and following APF treatment and subsequent acid-etching for 1 min with unbuffered phosphoric acid. Water imbibition. a. Lesion prior to treatment (control). Surface zone (SZ) depth = 31  $\mu\text{m}$ . Body of the lesion (BL) depth = 527  $\mu\text{m}$ . b. Acid-etched lesion following APF-treatment. Loss of surface enamel (arrow) for this lesion was 12  $\mu\text{m}$ . Surface zone (SZ) depth = 29  $\mu\text{m}$ . Body of the lesion (BL) depth = 516  $\mu\text{m}$ .

zones for APF-treated lesions that had been etched was 26  $\mu\text{m}$ , when measured from the etched enamel surface. The depths of both control and etched surface zones were very similar, despite the loss of surface enamel from the etched lesions. When measured from the original enamel surface, the mean surface zone depths for the APF-treated lesions etched with unbuffered phosphoric acid were 31  $\mu\text{m}$ , 38  $\mu\text{m}$  and 40  $\mu\text{m}$  for the 30 s, 1 min, and 2 min etching times, respectively. Following acid-etching with the buffered solution, surface zone depths measured from the original enamel surface for the APF-treated lesions were 31  $\mu\text{m}$ , 36  $\mu\text{m}$  and 38  $\mu\text{m}$  for the 30 s, 1 min, and 2 min etching periods.

The representative control lesion (Figure 4a) possessed a negatively birefringent, intact surface-zone

overlying the positively birefringent body of the lesion, following imbibition with water. The surface zone was 31  $\mu\text{m}$  in depth. Following acid-etching with 30 percent phosphoric acid and the subsequent APF treatment, the histological appearance of the corresponding lesion may be seen in Figure 4b. This longitudinal section was prepared from the same tooth-half and illustrates the typical histological changes associated with the experimental treatment. Although the surface of the lesion appeared to be slightly roughened, when compared to its control, the etched surface zone measured 29  $\mu\text{m}$  in depth. The lesion had also lost 12  $\mu\text{m}$  of enamel from its surface zone. Despite both the surface roughening and loss of surface enamel, the surface of the lesion appeared to be intact. The depth of the etched surface zone was 41  $\mu\text{m}$ , when measured from the original enamel surface. The bodies of the lesions were comparable in depth: 527  $\mu\text{m}$  for the control lesion and 516  $\mu\text{m}$  for the etched lesion.

### Scanning electron microscopic results

Surface coatings were observed overlying caries-like lesions treated with APF and rinsed with deionized/distilled water, but not acid-etched (Figure 5). These coatings were found to be very dense with a surface composed of globules of adherent reaction products. Occasional breaks in the surface coating occurred, revealing the internal aspect of the coating, which appeared to be formed by a relatively fine precipitation product. In addition, the underlying surface of the lesion seemed to be somewhat porous and slightly roughened, an appearance consistent with the mild etching




Figure 5. Surface coating (SC) overlying a caries-like lesion following APF treatment may be seen as well as the lesion surface (LS). SEM photomicrograph.

effect that typically occurs, when sound enamel is treated with APF, due to the acidity of the fluoride solution.

Acid-etching of APF-treated lesions with unbuffered phosphoric acid solutions produced marked changes in surface morphology. When a 30 s etching time was used, the presence of small globular precipitation products of less than  $1\ \mu\text{m}$  in diameter adhering to the etched prism cores was observed. The ultrastructural appearances of these globules were consistent with the morphological features associated with calcium fluoride and could be suggestive of this mineral phase.<sup>18-22</sup> The surface appeared to be slightly etched with a significant number of adherent reaction products. Predominantly type 1 etching patterns were found, when the etching time was increased to 1 min (Figure 6). The prism cores were preferentially removed, leaving behind prism peripheries projecting toward the original lesion surface. Reaction products represented by small globules could be seen adhering to the etched prism peripheries. With an etching time of 2 min, the surfaces of the APF-treated lesions became partly obscured by an increased deposition of reaction products (Figure 7). A type 1 etching pattern could be distinguished; spherical globules, suggestive of calcium fluoride, however, were found most often adhering to the etched prism cores and peripheries (Figure 8).

When the etching solution used was 50 percent phosphoric acid, buffered with 7 percent zinc oxide, the surface morphology of the APF-treated lesions was obscured, in varying degrees, by the presence of surface coatings and precipitation products, for all three etching periods. With the 30 s etching time, a surface coating was present that appeared to be only slightly porous, with a uniform distribution of fine, spherical reaction products (Figure 9). Apparently, only the outer aspect of the surface coating was affected by the buffered etching solution. Exposure of the lesion surface did not occur. Following a 1 min etching time, the surface of the lesion appeared to be slightly etched and in certain areas prism outlines could be distinguished (Figure 10). The surface possessed, however, a discontinuous coating composed primarily of spherical globules of less than  $1\ \mu\text{m}$  in diameter. With a 2 min etching time, the etched prism morphology was more distinct, but significant amounts of precipitation products were observed to be adhering to the prism peripheries (Figure 11). Once again, the precipitation products were primarily of the minute, spherical type, suggestive of the morphology associated with calcium fluoride.




Figure 6. Etched enamel prisms with adherent spherical reaction products may be seen on this lesion surface following APF treatment and subsequent acid-etching for 30 s with unbuffered phosphoric acid. SEM photomicrograph.

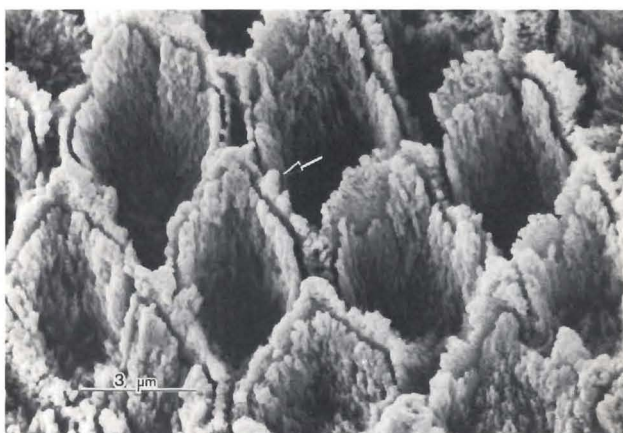


Figure 7. A type 1 etching pattern is present on the surface of this APF-treated lesion that was etched with unbuffered phosphoric acid for 1 min. Spherical reaction products (arrow) may be seen adhering to the peripheries of the etched enamel prisms. SEM photomicrograph.



Figure 8. Following acid-etching with unbuffered phosphoric acid for 2 min, the APF-treated lesion possessed a type 1 etching pattern partially obscured by spherical deposits (arrow) suggestive of calcium fluoride. SEM photomicrograph.

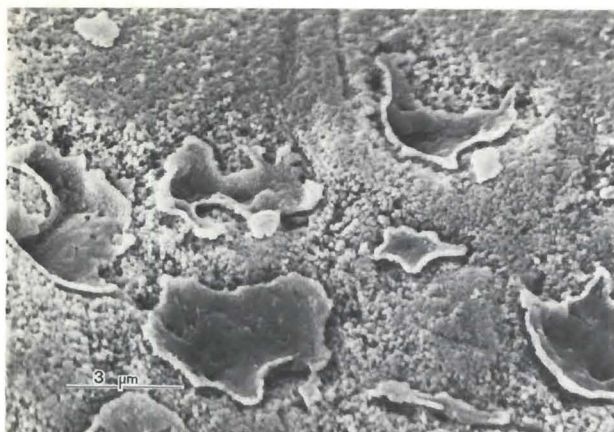


Figure 9. A fine granular coating overlies the surface of a lesion that was treated with APF and subsequently etched for 30 s with buffered phosphoric acid. SEM photomicrograph.



Figure 10. The outlines of occasional enamel prisms (arrow) interspersed with a fine spherical surface coating were observed with this APF-treated lesion acid-etched for 1 min with buffered phosphoric acid. SEM photomicrograph.

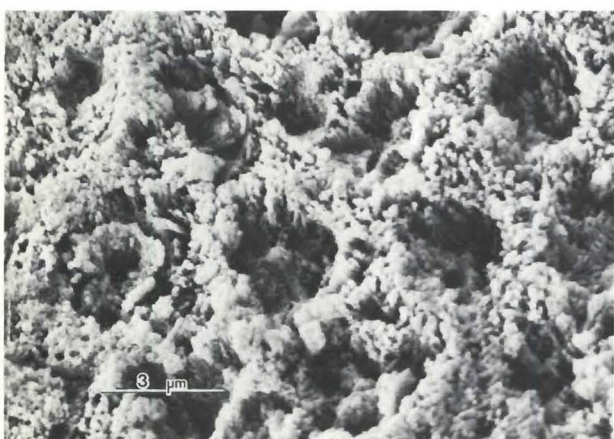


Figure 11. Acid-etching of this APF-treated lesion for 2 min with unbuffered phosphoric acid resulted in an increased degree of porosity as evidenced by the presence of etched enamel prism. A significant number of precipitation products, however, were observed. SEM photomicrograph.

## DISCUSSION

Acidulated phosphate fluoride was introduced as a means to incorporate a higher level of fluoride into sound enamel and reduce enamel solubility that occurs during a cariogenic challenge.<sup>18</sup> Indeed, fluoride uptake has been shown to be increased significantly for enamel treated with an APF solution when compared to enamel treated with NaF.<sup>19</sup> With APF treatment, two separate reaction processes occur. A rapid, initial process of enamel dissolution with reprecipitation of fluoride-rich reaction products onto the enamel surface occurs. This initial uptake of fluoride is followed by a slower diffusion-controlled process of fluoride incorporation into enamel from the surface coatings. Two distinct surface features are apparent when enamel is treated with an APF solution: the treated surface appears more porous due to the acidity of APF and a surface coating composed of numerous small globules of usually less than 1 µm in diameter is present. These small globules have been shown to represent calcium fluoride spheres.<sup>18-22</sup> In the present study, caries-like lesions that were exposed only to APF were found to be similar in appearance. Globular surface coatings were found and in areas where the lesion surface was exposed, a slightly porous surface enamel was observed.

With acid-etching of the fluoride-treated lesions, the morphology of the surfaces was dependent on whether the buffered or unbuffered phosphoric acid was used and on the length of the etching period. Lesions that were etched with the buffered solution appeared to possess surfaces with dense globular coatings. The surface coatings did not appear to be affected to a large extent until an etching time of 2 min was used. With this etching period, the outline of etched enamel prisms with adherent reaction products could be observed readily. When APF-treated lesions were exposed to the unbuffered etching solution for 1 min, characteristic etching patterns similar to those reported previously for sound enamel were present.<sup>13-16</sup> Spherical precipitation products suggestive of calcium fluoride were found partially obscuring the etched enamel prisms on lesion surfaces etched for 30 s and 2 min. These types of surface coatings may provide a protective function by allowing for incorporation of fluoride into the lesions, acting as diffusion barriers, reducing enamel solubility and acting as reservoirs for fluoride-rich reaction products.<sup>23</sup> In this way the progress of a lesion is inhibited and its remineralization by oral fluids may be enhanced. Remineralization may also be facilitated by the surface coating created when the lesion was etched with phos-

phoric acid, buffered with zinc oxide. Zinc has been shown to promote rapid remineralization of artificial caries with synthetic calcifying fluids.<sup>24-26</sup>

This study also determined that although acid-etching of the lesion surface resulted in loss of surface enamel, the etched lesion possessed an intact surface zone that appeared similar to that for the control lesion. In fact, despite the loss of surface enamel, the mean depths for control and etched surface zones were quite similar. The typical surface zone for a control lesion possessed an inner front that was 27  $\mu\text{m}$  from the enamel surface, whereas the inner front of the typical surface zone from an APF-treated lesion that had been acid-etched for 1 min with unbuffered phosphoric acid was 26  $\mu\text{m}$  from the etched enamel surface and 38  $\mu\text{m}$  from the original enamel surface. This implies that the etched surface zone had increased its depth at the expense of the underlying body of the lesion. Acid-etching of sound enamel creates microporosities that extend into the enamel to a depth of at least 50  $\mu\text{m}$ .<sup>12,13</sup> Because surface zones from caries-like lesions and naturally occurring lesions are usually 25  $\mu\text{m}$  to 30  $\mu\text{m}$  in depth, it could be assumed that acid-etching of enamel lesions would result in microporosities extending from the enamel surface through the surface zone to the superficial portion of the body of the lesion.<sup>1,2</sup> Recently, an ultrastructural study showed that the internal morphology of the surface zone is altered, following acid-etching, resulting in the creation of funnel-shaped structures that extend from the lesion surface into the surface zone for a considerable distance, with small porosities of less than 300 nm present at the inner aspect of the surface zone near the uppermost border of the body of the lesion. In the present study, it would appear that remineralization limited to the superficial aspect of the body of the lesion and surface zone occurred, due to incorporation of reaction products available from the surface coating with these areas via the microporosities created by the acid-etching procedure. Apparently, the etching solution acted as a carrier for calcium, phosphate, and fluoride obtained from the surface coating and the etched surface zone. Precipitation of these mineral phases along with fluoride into the superficial aspect of the body of the lesion most likely occurred, resulting in expansion of the surface zone at the expense of the body of the lesion.

Acid-etching of an APF-treated lesion may allow for a more rapid rate and increased degree of remineralization, due to the presence of microporosities and increased fluoride levels in the lesion. The microporosities may increase the surface area available for

interaction with oral fluids or synthetic calcifying fluids, in addition to providing pathways to the body of the lesion, the area of greatest demineralization in the enamel lesion. The presence of fluoride is known to enhance both the degree and rate of remineralization, as well as promoting the formation of fluoridated mineral phases that are more resistant to acid dissolution.<sup>8-10</sup> The acid-etch technique used in combination with fluoride pretreatment may create a lesion that is more resistant to progression. Alternatively, it may be possible to arrest the progression of a lesion by placing an acid-resistant resin over the surface of the lesion, following acid-etching with unbuffered phosphoric acid for 1 min. Sound enamel that has been sealed has been shown to be more resistant to both acid dissolution and artificial lesion formation than sound enamel alone.<sup>27,28</sup> Isolation of the lesion from cariogenic challenges by placement of a resin could result in formation of more stable mineral phases, due to the prolonged interaction of fluoride, phosphate, and calcium.

#### REFERENCES

1. Silverstone, L.M.: The surface zone in caries and caries-like lesions produced *in vitro*. *Br Dent J*, 125:145-157, August, 1968.
2. Silverstone, L.M.: The structure of carious enamel, including the early lesion. *Oral Sci Rev*, 3:100-160, 1973.
3. Hicks, M.J. and Silverstone, L.M.: Acid-etching of caries-like lesions of enamel: a scanning electron microscopic study. *Caries Res*, 18:326-335, July-August, 1984.
4. Hicks, M.J. and Silverstone, L.M.: Internal morphology of surface zones from acid-etched caries-like lesions: a scanning electron microscopic study. *J Dent Res*, 64:1296-1301, November, 1985.
5. ten Cate, J.M. and Arends, J.: Remineralization of artificial enamel lesions *in vitro*. *Caries Res*, 11:277-286, September-October, 1977.
6. Gelhard, T.B.F.M.; ten Cate, J.M.; and Arends, J.: Rehardening of artificial enamel lesions *in vivo*. *Caries Res*, 13:80-83, March-April, 1979.
7. ten Cate, J.M.; Jongbloed, W.L.; and Arends, J.: Remineralization of artificial enamel lesions *in vitro* IV: influence of fluorides and diphosphonates on short- and long-term remineralization. *Caries Res*, 15:60-69, January-February, 1981.
8. Silverstone, L.M.: Remineralization phenomena. *Caries Res*, 11:59-84, Supplement 1, 1977.
9. Silverstone, L.M.: The effect of fluoride in the remineralization of enamel caries and caries-like lesions *in vitro*. *J Pub Hlth Dent*, 42:42-53, Winter, 1982.
10. Silverstone, L.M.: Remineralization and enamel caries: new concepts. *Dent Update*, 10:261-273, May, 1983.
11. Hicks, M.J. and Silverstone, L.M.: Acid-etching of caries-like lesions of enamel: a polarized light microscopic study. *Caries Res*, 18:315-326, July-August, 1984.
12. Silverstone, L.M.: Fissure sealants: laboratory studies. *Caries Res*, 8:2-26, January-February, 1974.
13. Silverstone, L.M.; Saxton, C.A.; Dogon, I.L. *et al*: Variation in the pattern of acid etching on human dental enamel examined by scanning electron microscopy. *Caries Res*, 9:373-387, September-October, 1975.
14. Retief, D.H.: Effect of conditioning the enamel surface with phosphoric acid. *J Dent Res*, 52:333-341, March-April, 1973.

15. Retief, D.H.: A comparative study of three etching solutions. *J Oral Rehab*, 1:381-390, October, 1974.
16. Retief, D.H.: A comparative study of three etching solutions: effects on enamel surface and adhesive-enamel interface. *J Oral Rehab*, 2:75-96, January, 1975.
17. Silverstone, L.M.: The histopathology of enamel lesions produced *in vitro* and their relation with enamel caries. PhD thesis, University of Bristol, 1967.
18. Brudevold, F.; Savory, A.; Gardner, D.E. *et al*: Study of acidulated phosphate fluoride solutions I: *in vitro* effects on enamel. *Arch Oral Biol*, 8:167-177, March-April, 1963.
19. Joyston-Bechal, S.; Duckworth, R.; and Braden, M.: The mechanism of uptake of F<sup>18</sup> by enamel from NaF and APF solutions labelled with F<sup>18</sup>. *Arch Oral Biol*, 18:1077-1089, September, 1973.
20. Gwinnett, A.J.; Buonocore, M.G.; and Sheykholeslam, Z.: Effect of fluoride on etched human and bovine tooth enamel surfaces as demonstrated by scanning electron microscopy. *Arch Oral Biol*, 17:271-278, February, 1972.
21. Frazier, P.D. and Engen, D.W.: X-ray diffraction study of the reaction of acidulated phosphate fluoride with powdered enamel. *J Dent Res*, 45:1114-1148, July- August, 1966.
22. Baud, C.A. and Bang, S.: Electron probe and X-ray diffraction microanalyses of human enamel treated *in vitro* by fluoride solutions. *Caries Res*, 4:1-13, January- February, 1970.
23. Nancollas, G.H.: Physicochemistry of demineralization and remineralization. *J Dent Res*, 53:297-302, March- April, 1974.
24. Featherstone, J.D.B.; Rodgers, B.E.; and Smith, N.W.: Physicochemical requirements for rapid remineralization of early carious lesions. *Caries Res*, 15:221-235, May-June, 1981.
25. Nelson, D.F.G.; Featherstone, J.D.B.; Duncan, J.F. *et al*: Paracrystalline disorder of biological and synthetic carbonate-containing apatites. *J Dent Res*, 61:1274-1281, November, 1982.
26. Featherstone, J.D.B. and Shariati, M.: Dependence of remineralization on concentration of calcium, strontium and zinc. *J Dent Res*, 62:163, March, 1983.
27. Hicks, M.J. and Silverstone, L.M.: The effect of sealant application and sealant loss on caries-like lesion formation *in vitro*. *Pediatr Dent*, 4:111-114, June, 1982.
28. Silverstone, L.M.: Fissure sealants: the susceptibility to dissolution of acid-etched and subsequently abraded enamel *in vitro*. *Caries Res*, 11:46-51, January-February, 1977.

---

#### EARLY NATURAL SUBSURFACE CARIES

The result of this study, the first SEM study to show remineralization *in vivo* of natural enamel subsurface lesions, clearly demonstrates differences in surface characteristics before and after remineralization. Since surfaces of initial caries lesions contain areas of varying appearance (*Thylstrup and Fredebo*, 1982; *Haikel et al.*, 1983), it was considered necessary to study the same area before as well as after remineralization to verify the results from the first part of the investigation. The same observations were made in all nine cases before and after remineralization. It could be concluded that the clinical treatment resulted in more homogeneous surfaces with densely packed crystallites. The surfaces contained fewer openings and the crystallites had increased in size. These findings were in accordance with studies regarding remineralization *in vitro* of artificial caries (*ten Cate et al*, 1981). Under clinical conditions, however, it might be debated whether this is a result of remineralization alone or a combination of remineralization and mechanical wear through brushing. The appearance of the surface after treatment supports the last-mentioned assumption.

According to *Thylstrup and Fejerskov* (1981) interdental wear might change the appearance of proximal carious surfaces through abrasion. Intense toothbrushing on demineralized enamel might also be abrasive. The observed surface changes might, therefore, be considered to be a result of remineralization and abrasion.

Variations in the depth of the carious enamel at the start might explain the difference in clinical appearance between peripheral and central parts of the remineralized carious surface.

Another reason for the lack of healing in depth of the central parts of the lesions could be that remineralization in saliva, using highly concentrated fluoride solutions, led to rapid remineralization of the surface and thereby prevented the possibility of remineralization of deeper enamel layers (*Silverstone et al*, 1981; *ten Cate et al*, 1981).

Möller, H. and Schröder, U.:  
Early natural subsurface caries.  
*Caries Res*, 20: 97-102, 1986.

---

# The effect of fluoridated water on DMF scores of first permanent molars in mixed dentitions

Eeva Linkosalo, LDS

In most reports on the effects of fluoridated tap water on dental health, caries registrations are made only clinically.<sup>1-15</sup> The effect of fluoridation is shown to be weakest on occlusal surfaces, although some protective effects are also found on occlusal surfaces.<sup>4,16,17</sup> Personal caries activity, furthermore, may vary widely. The method, therefore, to divide the teeth in groups according to one, two or more surface lesions provides a more accurate indication of the state of the dental health of a given population than percentages of the DMFT or DMFS indices.<sup>1</sup>

Registration of the caries status of all teeth in young persons during their eruption periods, as well as differences in the criteria of diagnosis, may result in differences in the findings between studies. Also, the distribution of caries and the effectiveness of fluoride on cariogenicity will vary with the type of tooth.<sup>18</sup>

First permanent molars, particularly in their fissures, begin to decay very rapidly after eruption.<sup>19-21</sup> It could be expected, therefore, that the effect of fluoridation would be quite clearly shown in these teeth.

In this paper, the health status of first permanent molars is studied in two groups of Finnish children, born and living in towns with or without a fluoride supplement in the drinking water. A number of new aspects of the problem of estimating the differences in caries activity between them is considered.

## MATERIALS AND METHODS

The sample used in this study consisted of 146 children born in 1963 and living in the town of Kuopio, where the communal water supply was fluoridated since 1959 (1 mg/L F) and where no topical fluoride applications were made in dental health centers during the study period. The amount of dentifrice sold in Finland increased two-fold during the study period and 95 percent of it contained fluorides.<sup>22</sup> The control group consisted of 110 children, at the same age, living in the neighboring town of Pieksämäki, where the fluoride concentration of the communal water supply, as well as in other sources of drinking water, was 0.0 - 0.1 mg/L F.<sup>23</sup> In connection with dental health services, the teeth of all children in this town were rinsed with 0.2 percent fluoride solution, according to the recommendations issued for low-fluoride areas.<sup>24</sup>

Dental caries in first permanent molars was recorded at the ages of seven, eleven and fifteen years. At the ages of eleven and fifteen years, the clinical data were complemented with bitewing radiographs. The first permanent molars were assigned to groups with 0 - 5 DMF surfaces per tooth. Percentage distribution of children with four to no intact first permanent molars and the mean numbers of DMFS scores were calculated.

Intraexaminer reproducibility of dental findings was studied twice in twenty children, with an interval of four weeks. Reproducibility of primary and secondary caries and fillings on the five tooth surfaces was expressed in kappa values.<sup>25</sup> Kappa values with their 99 percent con-

Dr. Linkosalo is with the Institute of Dentistry, University of Kuopio, Kuopio, Finland.

Table 1 □ Estimation of intraexaminer reproducibility through calculation of the kappa values and their 99.0 percent confidence intervals, in terms of primary and secondary caries or filled surfaces of the first permanent molars.

	Caries		Fillings		Secondary caries	
	Kappa	Confidence interval	Kappa	Confidence interval	Kappa	Confidence interval
Occlusal surface	0.84	0.57-1.12	1.00	1.00-1.00	0.89	0.63-1.00
Mesial surface	1.00	1.00-1.00	0.71	0.30-1.12	1.00	1.00-1.00
Buccal surface	0.76	0.50-1.02	0.55	-0.04-1.14	no findings	
Distal surface	no findings		1.00	1.00-1.00	no findings	
Oral surface	0.90	0.73-1.08	0.92	0.76-1.06	no findings	

Table 2 □ Health status of first permanent molars at ages of seven, eleven and fifteen years in children born and living in towns with and without supplemental fluoride in drinking water.

Dental health status of first permanent molars	Fluoridated water			Low-fluoride water		
	7 yr	11 yr Percent	15 yr	7 yr	11 yr Percent	15 yr
Intact teeth	60.1	24.8	10.3	36.4***	4.8***	1.6***
Primary caries	35.3	1.9	0.5	54.5***	3.6	1.8*
Secondary caries	0.5	2.7	7.2	0.7	27.3***	30.3***
Root remaining	—	—	—	3.8	0.7	0.9
Filling	4.0	70.4	81.8	4.5	54.8**	55.2***
Extracted	—	0.2	0.2	0.2	8.9***	10.2***
Total percent	100.0	100.0	100.0	100.0	100.0	100.0
No. of erupted teeth	(547)1	(584)	(584)	(426)1	(449)	(440)

Differences between age-groups:

- \*p < 0.05
- \*\*p < 0.01
- \*\*\*p < 0.001

Table 3 □ Percentage distribution of first permanent molars with 0 to 5 DMF surfaces per tooth at ages seven, eleven and fifteen years in children born and living in towns with and without supplemental fluoride in drinking water.

Number of DMF surfaces per tooth <sup>1</sup>	Fluoridated water			Low-fluoride water		
	7 yr	11 yr Percent	15 yr	7 yr	11 yr Percent	15 yr
0	60.2	24.8	10.3	36.4***	4.8***	1.6***
1	37.7	54.1	53.3	47.7	26.4***	14.8***
2	1.6	17.8	27.2	10.3***	29.1	28.4***
3	—	2.6	6.9	1.4	21.0***	25.2***
4	—	0.3	1.5	0.2	15.5***	21.4***
5	—	—	0.5	3.8	3.2	8.9***
Total percent	100.0	100.0	100.0	100.0	100.0	100.0
(Number of erupted teeth)	(332)1	(584)	(584)	(426)	(440)	(440)

<sup>1</sup>Extracted first permanent molars are counted in groups DMFS = 4

Differences between age-groups:  
\*\*\*p < 0.001

confidence intervals in first permanent molars are shown in Table 1.

The differences between the groups with and without added fluoride in drinking water were tested by the chi-square test.

## RESULTS

Kappa statistics are useful descriptors of intraexaminer consistency.<sup>26</sup> The reliability found in this study was substantial.<sup>27</sup>

Percentage distribution of DMF-contributing factors as well as findings of secondary caries seen in Table 2 shows the difference (p < 0.001) in dental health status, in favor of children born and living in the area with

fluoride added to the drinking water. The most salient finding, however, is the ten-fold and five-fold differences in findings of secondary caries at the ages of eleven and fifteen years, respectively. The percentage of extracted first permanent molars increased with age in the area with low-fluoride water, while in the fluoridated area only one first permanent molar was extracted due to caries (Table 2).

At the age of seven years, 60.1 percent of first permanent molars in the area with the fluoridated water and 36.4 percent in the area with low-fluoridated water were intact. At age seven, the majority of the teeth, from both areas together, that were decayed, missing or filled had only one surface involved (Table 3). At the ages of eleven and fifteen years, in the fluoridated area, the groups



Table 4 □ Percentages of children with 4-0 intact first permanent molars per child and mean values of DMF-surfaces  $\pm$  SD for each group in children born and living in towns with and without supplemental fluoride in drinking water.

Number of intact first permanent molars	Fluoridated water									Low-fluoride water								
	7 yr <sup>1</sup>			11 yr			15 yr			7 yr <sup>1</sup>			11 yr			15 yr		
	Percent	DMFS	SD	Percent	DMFS	SD	Percent	DMFS	SD	Percent	DMFS	SD	Percent	DMFS	SD	Percent	DMFS	SD
4	44.0	0.0	0.0	5.5	0.0	0.0	2.1	0.0	0.0	17.8***	0.0	0.0	3.6	0.0	0.0	0.0	0.0	0.0
3	14.4	1.0	0.0	9.6	1.0	0.0	3.4	1.1	0.0	11.9	1.0	0.0	0.0	0.0	0.0	1.8	1.0	0.0
2	17.6	2.0	0.2	17.1	2.2	0.4	6.2	2.0	0.0	14.9	2.2	0.5	0.9***	3.0	0.0	0.0	0.0	0.0
1	8.8	3.0	0.1	14.4	3.8	0.8	10.3	4.1	1.4	16.8	3.7	0.8	2.7***	4.8	1.8	0.9	5.7	0.6
0	15.2	4.2	0.6	53.4	5.0	0.4	78.0	6.1	2.5	38.6***	6.1	0.9	92.8***	9.5	0.9	97.3*	11.2	4.0
Total (n)	100.0 (125)			100.0 (146)			100.0 (146)			100.0 (101)			100.0 (110)			100.0 (110)		

<sup>1</sup> Only children with all first permanent molars erupted

Differences at each age-group:

\*p < 0.05

\*\*\*p < 0.001

with only one DMF surface per tooth were still the largest, 54.1 percent and 53.3 percent, respectively. In the low-fluoride area, at the age of fifteen years, three or more DMF surfaces were found in 55.4 percent of first permanent molars.

At the age of seven years, in the fluoride area, 44.0 percent of children had all their first permanent molars intact (Table 4) and in the low-fluoride area, 17.8 percent ( $p < 0.001$ ). At the ages of eleven years and fifteen years, in the fluoride area, 5.5 percent and 2.1 percent of children had all their first permanent molars intact. The corresponding percentages in the low-fluoride area were 3.6 percent and 0.0 percent, respectively. At the age of fifteen years in the fluoride area 78.0 percent of children had all their first permanent molars decayed, missing or filled and the mean DMFS per four molars was 6.1. In the low-fluoride area, almost all children (97.3 percent) had DMF lesions on their first permanent molars and the mean DMFS value for these four molars was 11.2, indicating more complicated defects on these teeth (Table 4).

## DISCUSSION

Conditions in the oral cavity, in the age period ranging from seven years to fifteen years, is very complex because of exfoliation of the primary teeth and eruption of the permanent ones. Also, the maturation stages of the various tooth groups differ markedly at these ages. According to Nordblad and Larmas (who collected their data later), caries was limited, for the most part, to the first permanent molars, in children between the ages of seven and ten; and in children between the ages of ten and thirteen years, the first and second molars showed evidence of caries.<sup>21</sup> It seems acceptable, therefore, to use first permanent molars as indicators of the prevalence and incidence of caries in child populations.

Thus, in this paper the first permanent molars were the only teeth used for the study. Additional data of neighboring tooth groups will be reported in later papers. In order to compare the results with other studies,

the health status of first permanent molars was expressed also in DMFT and DMFS values. These indices, especially if presented as mean values, roughly represent the differences between the health status of first permanent molars in two groups of children, one group with fluoride in the drinking water and the other group without fluoride in the drinking water.

A more appropriate way to measure the dental health of a population might be to determine the percentage of individuals with completely intact dentitions or, in children, the number of individuals with all their first permanent molars intact. Soon after eruption, at the age of seven years, the number of children with all first permanent molars intact seems to be very high in fluoridated areas (80 percent to 86 percent) and somewhat lower in areas with no fluoridation (50 percent to 63 percent).<sup>2,8,12</sup>

In the present study, however, these percentages were very low, even in the fluoridated area, the number of children with all their first permanent molars intact was smaller than the corresponding value in low-fluoride areas in other studies.<sup>2,8,12</sup> Since 1972, communal oral care has been an integrated part of the public primary health care system in Finland. When this study began (1970), however, children under school age received only private dental care. Almost total lack of preventive care, negligible care for the primary teeth and delayed treatment for first permanent molars may be reflected in the poor health status found in this study.<sup>9</sup>

In most industrialized countries, the dental health status of children has improved during the last ten years.<sup>28-33</sup> This is also true in Finland.<sup>21,34</sup>

The change in dental health may, in part, reflect the increasing use of fluoride toothpastes and, in part, changes in the consumption of sugar and other sweets.<sup>31,32,35,36</sup> Also in fluoride areas, the need of treatment has markedly decreased for preventive reasons other than the use of fluoride and the decreased use of sugar.<sup>31,37</sup> In Northern countries, there is great use of sweets that are advertised as "good for your throat". Månsson found the same conditions in Swedish eight-

year-old children.<sup>19</sup> Only 25 percent of the children in her study had all their first permanent molars intact.

The rapid decrease in the proportion of children with all first permanent molars intact has been reported for children between seven and eleven years of age. Rock *et al* and Künzel reported about 40 percent of children in this age-group in fluoridated areas and 10 percent of those in low-fluoride areas to have all first permanent molars intact.<sup>2,12</sup> This was found by Videroni *et al* among ten year-old children in a fluoride area to be 21 percent and among twelve year-old children to be 8.6 percent, and in a low-fluoride area the corresponding percentages were 5.1 and 1.2, respectively.<sup>8</sup> With advancing age the percentages of these children become smaller, although Rock *et al* reported them to be 19 percent at the age of thirteen and Künzel, 10 percent at the age of fifteen in fluoride areas.<sup>2,12</sup> The same tendency was seen in our study, so that at the age of fifteen in the fluoride area, only a few children and in the low-fluoride area none of the children had all their first permanent molars intact.

In some other papers, the differences in dental health between fluoride and low-fluoride areas are presented in percentages of intact first permanent molars, using a tooth as a unit. Although the difference in the present numbers of intact first permanent molars at the age of seven (Table 2) clearly showed some positive effect of fluoride, the reduction of caries did not reach the level reported in other studies.<sup>1,4,38</sup> At the age of fifteen, the number of intact first permanent molars, even in the fluoride area, was hardly that reported without fluoride by King *et al*.<sup>20</sup> Especially in the low fluoride area, in our study, the number of intact first permanent molars was negligible.

At eleven and fifteen years of age, high percentages of secondary caries were found in the low-fluoride area. These were higher than reported by Künzel, without radiographs, but about as high as reported by studies made with radiographs.<sup>39-41</sup> In the fluoride area, however, percentages of secondary caries were, at the ages of eleven and fifteen years, lower than reported by Künzel.<sup>39</sup> The differences in our study were statistically highly significant ( $p < 0.001$ ).

The percentage distribution of DMF surfaces per tooth shows the protective effect of fluorides on proximal and free smooth surfaces of first permanent molars (Table 3). Even at the age of fifteen years, more than half of the children in the fluoride area has only one surface of their first permanent molars decayed or filled.

In the low-fluoride area, the clear tendency for caries to attack more than one surface was seen at the age of

eleven years; and at the age of fifteen years, over 80 percent of the children had two or more DMF lesions on their first permanent molars. Prophylactic means other than fluoridation of drinking water were not used in the fluoride community, nor was it recommended to use fluoride-containing dentifrices (pers. comm.). Intensification of other prophylactic uses of fluoride resulted in further reductions of caries and this has been found to be especially marked on newly-erupted teeth.<sup>42-45</sup> The effects of controlled oral hygiene supplemented with topical fluoride applications have also augmented the effect of fluoridated water, not only in children who are highly susceptible to caries, but even in children in a low-risk group.<sup>46-49</sup> Even in high fluoride areas, the fluoride content of the enamel surface can be increased by repeated topical applications.<sup>29,50</sup> In addition, caries prevention with fluoride varnishes, also in fluoride areas, has been reported.<sup>51,52</sup>

In the fluoride area, topical prophylaxis was negligible at the time of the present study. This means that the most important protective effect in children was the influence of fluoride in the drinking water. The results of our study, however, show that fluoride obtained from the drinking water is not sufficient for an effective preventive regimen.

## REFERENCES

1. Künzel, W.: Auswirkungen kariesvorbeugender Massnahmen (Trinkwasser-fluoridierung) auf Inhalt und Struktur der kinderstomatologischen Betreuung. Dtsch Stomatol, 21:777-791 and 841-853, November, 1971.
2. Künzel, W.: Trinkwasser-fluoridierung Karl-Marx- Stadt XIII. Karies-rückgang und Sanierung. Dtsch Stomatol, 26:458-465, July, 1976.
3. Künzel, W.: Dosierungskonstanz fluoridangereicherten Trinkwassers und Kariesverbreitung bei Kindern und Jugendlichen. Zahn-, Mund- und Kieferheilkd, 68:312-321, July-August, 1980.
4. Backer Dirks, O.; Houwink, B.; and Kwant, G.W.: Water fluoridation. R Soc Health J, 91:92-96, March-April, 1971.
5. Backer Dirks, O.; Künzel, W.; and Carlos, J.P.: Caries preventive water fluoridation. Caries Res, 12:Suppl. 1, 7-14, 1978.
6. Medcalf, G.W.: First permanent molars of six-year-old children after two and half years of fluoridation in Western Australia. Aust Dent J, 16:252-254, August, 1971.
7. Medcalf, G.W. and O'Grady, M.J.: The dental health of children eight and fifteen years of age living in Burnbury, Western Australia. Aust Dent J, 28:162-165, June, 1983.
8. Videroni, W.; Sternberg, G.S.; and Davies, G.N.: Effect of caries experience of lifetime residents after 10 years fluoridation in Townsville, Australia. Community Dent Oral Epidemiol, 4:248-253, November, 1976.
9. Van der Merwe, E.H.M.; Bischoff, J.I.; Fatti, L.P. *et al*: Relationships between fluoride in enamel, DMFT index and fluorosis in high and low-fluoride areas in South Africa. Community Dent Oral Epidemiol, 5:61-64, January, 1977.
10. Burt, B.: The relative efficiency of methods of caries prevention in dental public health. Proc Workshop. Ann Arbor: University of Michigan, 1978.

11. Rocca, R.A.; Vertuan, V.; and Mendes, A.J.D.: Efeito da ingestão de água fluoretada na prevalência de carie e perda de primeiros molares permanentes. *Rev Assoc Paul Cir Dent*, 33:50-59, January-February, 1979.
12. Rock, W.P.; Cordon, P.H.; and Bradnock, G.: Caries experience in West Midland school children following fluoridation of Birmingham water in 1964. *Br Dent J*, 150:269-273, May, 1981.
13. Thylstrup, A.; Bille, J.; and Bruun, C.: Caries prevalence in Danish children living in areas with low and optimal levels of natural water fluoride. *Caries Res*, 16:413-420, September-October, 1982.
14. Rahmatulla, M. and Rajasekar, A.: Prevalence of dental caries in high and low fluoride areas of salem district, Tamilnadu in South India. *J Indian Dent Assoc*, 55:451-454, November, 1983.
15. Johnsen, D.C.; Schultz, D.W.; and Schubot, D.B.: Caries patterns in head start children in a fluoridated community. *J Public Health Dent*, 44:61-66, Spring, 1984.
16. Backer Dirks, O.: The effectiveness of fluoridation in Europe. In: International Symposium on Fluoridation and Preventive Dentistry, October, 1969, pp 35-47.
17. Englander, H.R.: Fluoridation protects occlusal areas. *J Am Dent Assoc*, 98:11, January, 1979.
18. Bukovics, E.; Überhuber, C.W.; Husinsky, I. *et al*: Distribution of caries among tooth types in fluoride and non-fluoride areas. *Acta Med Acad Sci Hung*, 33:81-87, January, 1976.
19. Månsson, B.: Caries progression in the first permanent molars. A longitudinal study. *Swed Dent J*, 69:1:185-191, January, 1977.
20. King, N.M.; Spaw, L.; and Murray, J.J.: Caries susceptibility of permanent first and second molars in children aged 5 to 15 years. *Community Dent Oral Epidemiol*, 8:151-158, June, 1980.
21. Nordblad, A. and Larmas, M.: A cross-sectional study of caries prevalence in Finnish children 6-17 years of age. *Proc Finn Dent Soc*, 76:245-252, January, 1980.
22. Tala, H. and Ainamo, J.: Changes in general behaviour and environmental factors related to dental health, in: Dental Health Care in Scandinavia. January, 1981, pp 173-155.
23. Nordling, H. and Tala, H.: The results of analyses of the fluoride content of piped drinking waters and other water supply points in Finland 1958 and 1970-1971. Helsinki: Valtion painatuskeskus, 20 pp.
24. National Board of Health of Finland. Yleiskirje nro 1458, Dnro 5331, 1969, Helsinki: Valtion painatuskeskus.
25. Fleiss, J. L.; Cohen, J.; and Everitt, B.S.: Large sample standard errors of kappa and weighted kappa. *Psychol Bull*, 72:323-327, 1969.
26. Fleiss, J.L.; Fischman, S.L.; Chilton, N.W. *et al*: Reliability of discrete measurements in caries trials. *Caries Res*, 13:23-31, January-February, 1979.
27. Landis, J.R. and Koch, G.G.: The measurement of observer agreement for categorical data. *Biometrics*, 33:159-174, March, 1977.
28. Büttner, M.: Eindämmung der Karies in Basel. *Schweiz Mschr Zahnheilkd*, 87:298-303, April, 1977.
29. Künzel, W. and Georgi, C.: Additive Karieshemmung durch lokale Fluoridapplikation bei Kindern eines Wohngebietes mit fluoridangereichertem Trinkwasser. *Dtsch Stomatol*, 28:465-469, July, 1978.
30. Månsson, B.; Holm, A-K; Ollinen, P. *et al*: Dental health in 13-year-old children in the north of Sweden—changes during a 10-year-period. *Swed Dent J*, 3:193-203, November-December, 1979.
31. Anderson, R.J.: The changes in dental health of 12-year-old school children resident in a naturally fluoridated area of Cloucestershire. *Br Dent J*, 150:354-355, June, 1981.
32. Andlaw, R.J.; Burchell, C.K.; and Tucker, G.J.: Comparison of dental health of 11-year-old children in 1970 and 1979, and of 14-year-old children in 1973 and 1979: Studies in Bristol, England. *Caries Res*, 16:257-264, June-July, 1982.
33. Hargreaves, J.A.; Thompson, G.W.; and Wagg, B.J.: Changes in caries prevalence of Isle of Lewis children between 1971 and 1981. *Caries Res*, 17:554-559, November-December, 1983.
34. Rytömaa, I.; Järvinen, V.; and Calonius, P-E. B.: 44-year dental health survey of Helsinki schoolchildren. *Community Dent Oral Epidemiol*, 8:66-67, February, 1980.
35. Allen, C.D.; Ashley, F.P.; and Naylor, M.N.: Caries experience in 11-year-old school girls between 1962 and 1981. *Br Dent J*, 154:167-170, March, 1983.
36. Hope, T.: Results of 10 years of supervised fluoride toothbrushing in Rygge, Norway. *Community Dent Oral Epidemiol*, 7:330-334, December, 1979.
37. Künzel, W.: Annual sugar consumption and caries prevalence in optimum fluoride areas. *J Int Assoc Dent Child*, 14:15-19, June, 1983.
38. Murray, J.: Fluoridation studies and dental caries (A review). *Br Dent J*, 129:467-470, November, 1970.
39. Künzel, W.: Trinkwasserfluoridierung Karl-Marx-Stadt. Zuwachshemmung der Sekundarkaries. *Dtsch Stomatol*, 23:912-917, December, 1973.
40. Axelsson, P.; Hugoson, A.; Koch, G. *et al*: Tandhälsotillståndet hos 1000 personer i åldarna 3 till 70 år inom Jönköpings kommun, III Röntgenologisk undersökning av tänder och käkar. Tandlakartidningen, *Swed Dent J*, 69:1006-1017, September, 1977.
41. Gröndahl, H-G.; Hollender, L.; Malmcrona, E. *et al*: Dental caries and restorations in teenagers. *Swed Dent J*, 1:51-57, January-February, 1977.
42. Horowitz, H.S. and Heifetz, S.B.: Evaluation of topical applications of stannous fluoride to teeth of children born and reared in a fluoridated community: Final report. *J Dent Child*, 36:355-361, September-October, 1969.
43. Georgi, J. and Künzel, W.: Auswirkungen täglich angeleiteter Zahn- und Mundpflege auf den oralen Gesundheitszustand von Kindern in einer Stadt mit Trinkwasserfluoridierung (Karl-Marx-Stadt). *Dtsch Stomatol*, 26:201-206, March, 1976.
44. Heifetz, S.B.; Franchi, G.J.; Mosley, G.W. *et al*: Combined anticariogenic effect of fluoride gel-trays and fluoride mouthrinsing in an optimally fluoridated community. *Clin Prev Dent*, 6:21-23 and 28, January - February, 1979.
45. Horowitz, H.S. and Doyle, J.: The effect on dental caries of topically applied acidulated phosphate fluoride, results after three years. *J Am Dent Assoc*. 82:359-365, February, 1971.
46. Lindhe, J.; Axelsson, P.; and Tollskog, G.: Effect of proper oral hygiene on gingivitis and dental caries in Swedish schoolchildren. *Community Dent Oral Epidemiol*, 3:150-155, August, 1975.
47. Lindhe, J. and Axelsson, P.: The effect of controlled oral hygiene and topical fluoride application on caries and gingivitis in Swedish schoolchildren. *Community Dent Oral Epidemiol*, 1:9-16, January, 1973.
48. Axelsson, P. and Lindhe, J.: The effect of a preventive programme on dental plaque, gingivitis and caries in schoolchildren. Results after one and two years. *J Clin Periodontol*, 1:126-138, April, 1974.
49. Klock, B. and Krasse, B.: Effect of caries-preventive measures on children with high numbers of *S. mutans* and lactobacilli. *Scand J Dent Res*, 86:221-230, July, 1978.
50. Mellberg, J.R.; Nicholson, C.R.; Miller, B.G. *et al*: Acquisition of fluoride *in vivo* by enamel from repeated topical sodium fluoride application in a fluoridated area: Final Report. *J Dent Res*, 49:1473-1477, November-December, 1970.
51. Seppä, L.; Hausen, H.; and Luoma, H.: Relationship between caries and fluoride uptake by enamel from two fluoride varnishes in a community with fluoridated water. *Caries Res*, 16:404-412, September-October, 1982.
52. Seppä, L.: Effect of dental plaque on fluoride uptake by enamel from a sodium fluoride varnish *in vivo*. *Caries Res*, 17:71-75, January-February, 1983.

# Management of dental caries as an infectious disease

## Clinic

Norman Tinanoff, DDS, MS  
Roland Cantin, DMD

**D**ental caries is an infectious disease that demineralizes tooth structure as a consequence of bacterial metabolism. The anaerobic, glycolytic pathway of tooth-adherent bacteria converts simple sugars to acid. With unlimited supplies of glucose or sucrose, the end product of plaque bacterial metabolism is lactic acid.<sup>1</sup> Demineralization of enamel and dentin is the result of both the concentration of acid present at the tooth surface and the amount of time in which the mineral structures are exposed to low pH conditions.

### ROLE OF BACTERIA IN CARIES

The production of acid by bacteria is not the distinguishing feature of caries-producing bacteria, since acid synthesis is common to both cariogenic and noncariogenic organisms. *S. mutans* has metabolic pathways that also permit production of large quantities of a water-insoluble glucan from sucrose. Glucan is critical to the development of smooth surface caries, probably due to its role in bacterial attachment, or to its action as a barrier to diffusion of acid away from the tooth or of salivary buffers into plaque.<sup>2</sup> Other traits considered necessary for an organism to produce caries are the ability of an organism to survive in a low pH environment and to accumulate in a critical mass.

---

The authors are with the Department of Pediatric Dentistry, School of Dental Medicine, University of Connecticut Health Center. The authors are grateful to R. Zameck for her assistance with the microbiologic methods.

Dietary factors appear to have an important interaction with dental plaque in the caries process. Sucrose is known to be the most caries conducive carbohydrate, even though bacteria can metabolize other simple sugars. Perhaps the fact that sucrose is the only substrate that *S. mutans* can use to form glucan is the key factor. Clinical studies have clearly shown that:

- The ability of *S. mutans* to implant and colonize smooth surface enamel is increased with frequent ingestion of sucrose.<sup>3</sup>
- The percentage of *S. mutans* in dental plaque increases with frequent ingestion of sucrose.<sup>4</sup>

### ANTIMICROBIAL TREATMENT OF CARIES

Even though dental caries is the result of a chronic infection by specific bacteria, conventional therapy is still the mechanical removal of carious tooth structure and subsequent restoration with one of various dental materials. The primary antimicrobial approach used by dental professionals for the prevention of caries is the removal of plaque by oral hygiene techniques. This approach has not been successful, because mechanical methods of bacterial removal are too difficult for the average person, and the bacterial niches where the caries process begins are often impossible to reach with a toothbrush and dental floss.

Chemical suppression of bacteria is gaining popularity because of its practicality and clinical efficacy. Topical treatment with the nonspecific, antimicrobial chlorhexidine, has been shown to reduce the number of *S. mutans* in the saliva of subjects highly infected.<sup>5,6</sup> Furthermore, the spread of *S. mutans* to infants is suppressed, if mothers who are highly infected with *S. mutans* receive topical chlorhexidine treatments.<sup>7</sup> Chlorhexidine, however, has several disadvantages:

- It reduces the nonpathogenic as well as pathogenic flora.
- It severely stains teeth.
- It has a disagreeable taste.

Topical treatments with stannous fluoride have also been found to affect *S. mutans* levels in saliva and in plaque (for review, see reference 8). The antimicrobial effects of stannous fluoride may be additive to the well-documented anticaries effect of a fluoride agent. In a study of rampant caries subjects, it was found that the caries rate was less in the subjects rinsing with stannous fluoride than in those rinsing with sodium fluoride of equal fluoride ion concentration.<sup>9</sup>

Several factors have been found to be important for the optimal effect of stannous fluoride on the cariogenic

flora. Patients who initially have high numbers of *S. mutans* appear to have the greatest reduction. Stannous fluoride gel, at a concentration of 0.4 percent, has been found to have the greatest antimicrobial effect when used twice a day.<sup>10</sup> Furthermore, stannous fluoride products with an appropriate pH and stability have more antibacterial effects than those products which have pH values above 4, or have less than full strength fluoride and stannous ions. Although more research is needed to determine the exact mechanisms and benefits of the antimicrobial effects of stannous fluoride, it has been successfully used for years in caries-prone individuals. Side effects such as mild staining of the teeth in areas which the patient routinely misses while toothbrushing and a metallic aftertaste can hamper patient compliance.

### CASE REPORT

In November, 1984, a five-year-old, white male presented to the University of Connecticut dental screening clinic with a chief complaint of "medicine taken as baby has rotted teeth". The patient, two older brothers, mother, and father had immigrated a few months earlier to the United States from Scotland. Although the patient had numerous caries lesions in the primary teeth, some so extensive that only root tips remained, there was no complaint of pain at this time.

### History

The patients' birth history, developmental milestones, and medical history were unremarkable, except for a history of colic between one and thirty months of age. The patient was given Merbentyl twice a day to relieve the gastrointestinal pain. Merbentyl (dicyclomine hydrochloride) is an anticholinergic/antispasmodic that is prescribed in the United Kingdom for the relief of smooth muscle spasm of the gastrointestinal tract. As with all anticholinergics, it has the side effect of xerostomia.

The medical and dental history of the members of the family revealed that the mother and father were reportedly in good health and their teeth in good repair. The seven-year-old sibling's health history was significant for nasal airway obstruction and an "allergy" to Benadryl. Dental examination of this child revealed no new caries lesions, but two occlusal restorations were evident on the mandibular second primary molars. The twelve-year-old sibling's health history was remarkable only for an allergy to penicillin. He, however, was not

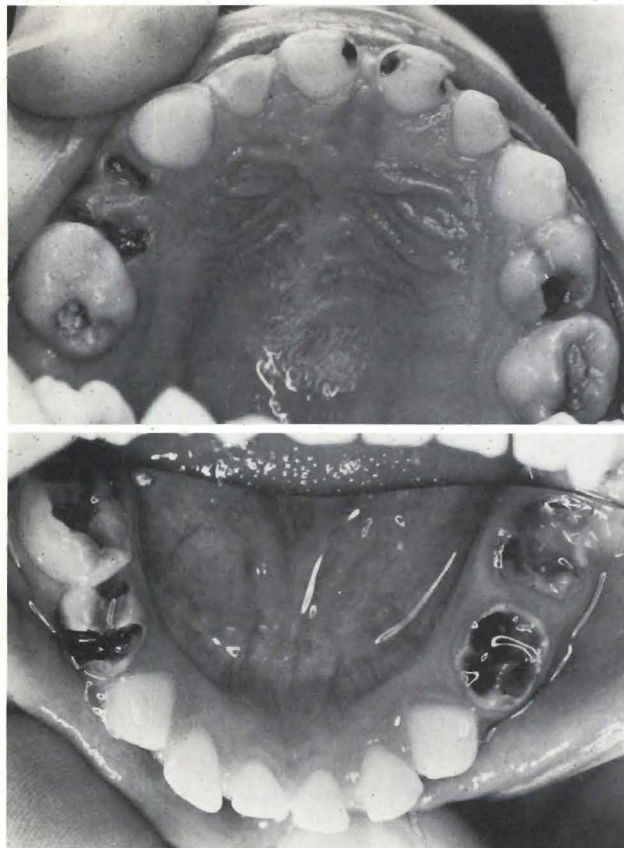


Figure 1. Initial intraoral photograph of a five-year-old child whose high caries rate may have been the result of drug induced xerostomia and high levels of cariogenic flora. Note extensive caries on all teeth, except for primary canines and mandibular primary incisors.

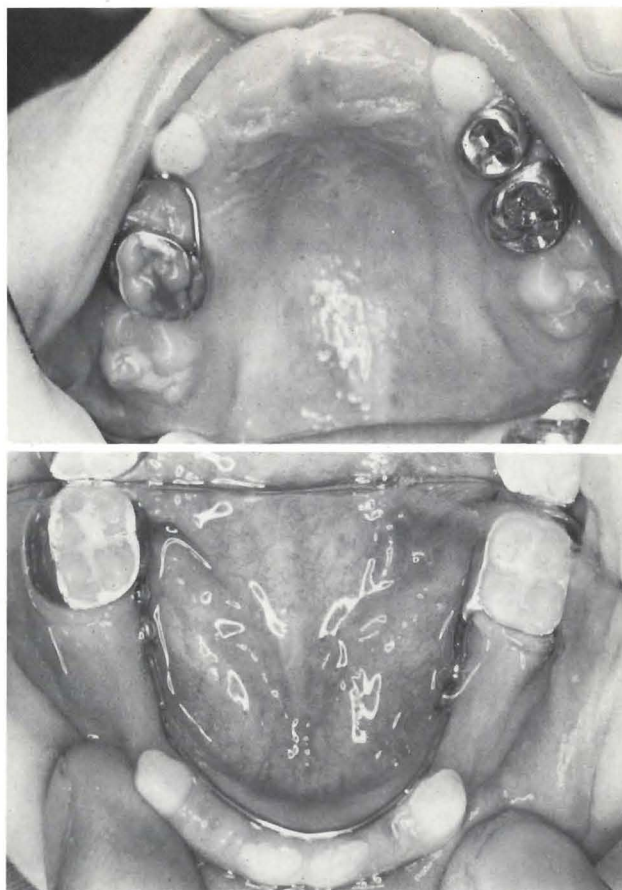


Figure 2. Intraoral photographs of the same child one year after restorative care and antimicrobial therapy. No new caries lesions developed during this period, and the first permanent molars and mandibular permanent incisors erupted.

available for examination, but the mother reported that he had had few problems with his primary teeth.

### Oral findings and treatment

The initial oral findings of the five-year-old patient revealed a primary dentition with caries on all teeth, except for the mandibular incisors. The mandibular primary molars were either so extensively carious or abscessed that they were not restorable. The maxillary second primary molars had recurrent caries adjoining amalgam restorations, and the maxillary first primary molars were either extensively carious or only root tips remained. No soft tissue swellings or fistulas were evident (Figure 1).

Because of uncooperative behavior, the patient had to be treated in a hospital operating room. Nine teeth were extracted because they could not be restored or were near exfoliation. Four teeth were treated with either amalgam restorations or stainless steel crowns. After the restorative care, the patient was instructed to brush once a day, in the evening, with 0.4 percent SnF<sub>2</sub> gel (Gel Kam, Scherer Labs, Dallas, TX).

Approximately one year after initial treatment, the first permanent molars and the mandibular incisor had erupted. No new caries was detected during this period. The next phase of treatment included sealants on the first permanent molars and space maintenance (Figure 2).

### Microbiologic methods

Stimulated saliva, produced by chewing on a piece of paraffin wax, was collected before treatment and at intervals after restorative care and fluoride therapy. Each saliva sample was immediately taken to the laboratory, where it was treated sonically for one minute (Bransonic 12, Bransonic Cleaning Equipment Co., Shelton, CT), subjected to vortical motion for 30 seconds, and serially diluted from 10<sup>1</sup> to 10<sup>6</sup> in 0.05 M phosphate buffer (pH 7.0). Twenty-five µl from each dilution were spotted on to one-third the surfaces of 10 percent sheep blood agar plates, for estimates of the total salivary colony forming units (Total CFU). For determination of the number of *S. mutans*, appropriately diluted samples were spotted on a selective me-

dium consisting of mitis salivarius agar, supplemented with 0.2 units/ml bacitracin.<sup>11</sup> After being spotted, the blood agar and mitis salivarius plates were incubated in a candle jar environment at 37°C for one and four days, respectively. Areas on the agar plates, with from 20 to 100 CFU, were counted with the aid of 20X magnification. Only those colonies with morphologic characteristics of *S. mutans* were counted on the mitis salivarius agar plates. After the bacteria were counted, the number of CFU was multiplied by the appropriate dilution factor. The total salivary CFU was used only to calculate the percentage *S. mutans*/total CFU. The results of the initial and subsequent salivary samples are presented in the Table.

## DISCUSSION

In the modern treatment of dental caries, knowledge of the microbiological aspects of the disease is as important as knowledge of restorative procedures. Several aspects of this case report may be useful in the treatment of caries-active patients.

Currently, determining the infection level of cariogenic microorganisms is not a routine diagnostic test for dental patients. The described micropipette dilution method is extensively used in research trials and for selected patients. It is not practical, however, in a private practice, because the diluting and plating procedures are time consuming, and the agar media are not stable for long periods of time. A spatula technique, in which a wooden spatula is moistened by saliva and pressed against selective growth medium, is simpler and perhaps adaptable to private practice; the precision of the technique, however, is not as good as the micropipette method.<sup>12,13</sup> The higher variance in the spatula technique may be acceptable, if a dentist needs only to rank patients according to high, moderate, or low levels of *S. mutans* infection. Since microbial monitoring techniques for *S. mutans* are not yet readily available, it may be feasible only to test those patients who present with rampant caries or caries activity of unknown etiology.

Regarding the child in this case report, we cannot say with confidence that the long-term use of an anticholinergic medication caused the high caries rate. There is evidence, however, that xerostomic conditions foster increases in both cariogenic organisms and caries activity. Reduction in salivary flow, due to head and neck radiation, has been shown to be associated with a pronounced increase in *S. mutans* and lactobacilli.<sup>14,15</sup> Such microbial shifts are believed to be an important

Table □ Initial and subsequent *S. mutans* levels in a five-year-old child who presented with high caries activity.

	<i>S. mutans</i> / ml saliva	% <i>S. mutans</i> / total CFU
1/28/85	3.4 X 10 <sup>6</sup>	14.6
Beginning of dental treatment and application of topical SnF <sub>2</sub>		
2/11/85	0	0.0
4/23/85	5.0 X 10 <sup>4</sup>	0.07
8/22/85	2.6 X 10 <sup>6</sup>	1.4
10/24/85	3.3 X 10 <sup>5</sup>	0.16
12/12/85	1.6 X 10 <sup>4</sup>	0.05

factor in rampant dental caries in patients who have their salivary glands irradiated for cancer treatment.

The dramatic reduction of *S. mutans* that the child had after beginning SnF<sub>2</sub> treatment is comparable to several clinical trials using SnF<sub>2</sub> either at mouthrinse or brush-on concentrations. *S. mutans* was consistently reduced in subjects compliant with daily use of SnF<sub>2</sub>.<sup>16,17</sup> It could be argued that the reduction of salivary *S. mutans* in this child was associated with the removal of the caries lesions as a result of the restorative care and extractions. Previous studies we performed did not show any effect of dental care on salivary levels of *S. mutans*.<sup>17</sup>

Unlike other home care procedures, the use of SnF<sub>2</sub> as a selective antimicrobial agent against *S. mutans* is practical and can be adapted to daily routines, since the SnF<sub>2</sub> topical treatment can be a substitute for a normal toothbrushing. Microbial monitoring of *S. mutans* levels can also be of use in determining patient compliance. Discontinuation of SnF<sub>2</sub> results in return of *S. mutans* infection to the original levels.<sup>10,16</sup> In our experience, patients for whom SnF<sub>2</sub> is prescribed, but who do not have a reduction in *S. mutans*, have not complied with the procedure. In such patients, the restorative treatment plan may need to be altered to reflect a less favorable prognosis.

## REFERENCES

1. Fitzgerald, R.J.: The microbial ecology of plaque in relation to dental caries. In Proc "Microbial aspects of dental caries", eds. Stiles, Loesche, and O'Brien, Spec. Supp. Microbial Abstracts, 111:849-858, 1976.
2. Hojo, S.; Higuchi, M.; and Araya, S.: Glucan inhibition of diffusion in plaque. J Dent Res, 55:169, January, 1976.
3. Krasse, B.; Edwardsson, S.; Svensson, I. *et al*: Implantation of caries-inducing streptococci in the human oral cavity. Arch Oral Biol, 12:231-236, February, 1967.
4. Statt, R.H.; Gawronski, T.H.; Cressey, D.E. *et al*: Effects of dietary sucrose levels on the quantity and microbial composition of human dental plaque. J Dent Res, 54:872-880, April, 1975.
5. Maltz, M.; Zickert, I.; and Krasse, B.: Effect of intensive treatment with chlorhexidine on number of *Streptococcus mutans* in saliva. Scand J Dent Res, 89:445-449, November-December, 1981.

6. Emilson, C.C.: Effect of chlorhexidine gel treatment on *Streptococcus mutans* population in human saliva and dental plaque. *Scand J Dent Res*, 89:239-246, May-June, 1981.
7. Kohler, B.; Bratthall, D.; and Krasse, B.: Preventive measures in mothers influence the establishment of the bacterium *Streptococcus mutans* in their infants. *Arch Oral Biol*, 28:225-231, March, 1983.
8. Tinanoff, N.: Stannous fluoride in clinical dentistry. In, *Clinical Uses of Fluorides*, ed., Wei, S.H.Y. Philadelphia: Lea & Febiger, 1985.
9. Klock, B.; Serling, J.; Kinder, S. *et al*: Comparison of effect of SnF<sub>2</sub> and NaF mouthrinses on caries incidence, salivary *S. mutans* and gingivitis in high caries prevalent adults. *Scand J Dent Res*, 93:213-217, May-June, 1985.
10. Tinanoff, N. and Zameck, R.: Alteration in salivary and plaque *S. mutans* in adults brushing with 0.4% SnF<sub>2</sub> gel once or twice a day. *Pediatric Dent*, 7:180-184, September-October, 1985.
11. Westergren G. and Krasse, B.: Evaluation of a micromethod for determination of *Streptococcus mutans* and *Lactobacillus* infection. *J Clin Microbiol*, 7:82-83, January, 1978.
12. Kohler, B. and Bratthall, D.: Practical method to facilitate estimation of *Streptococcus mutans* levels in saliva. *J Clin Microbiol*, 9:584-588, May, 1979.
13. Matee, M.I.; Mikx, F.H.M.; Frenchen, J.E.F.N. *et al*: Selection of a micromethod and its use in the estimation of salivary *Streptococcus mutans* and lactobacillus counts in relation to dental caries in Tanzanian children. *Caries Res*, 19:497-506, November-December, 1985.
14. Brown, L.R.; Dreizen, S.; Handler, S. *et al*: Effect of radiation-induced xerostomia on human oral microflora. *J Dent Res*, 54:740-750, April, 1975.
15. Llory, H.; Drammron, A.; Gioanni, M. *et al*: Some population changes in oral anaerobic microorganisms, *Streptococcus mutans* and yeasts following irradiation of the salivary glands. *Caries Res*, 6:298-311, October-December, 1972.
16. Vierrou, A.; Manwell, M.A.; Zameck, R. *et al*: Control of *S. mutans* in orthodontic patients with topical fluorides. *JADA* (in press).
17. Tinanoff, N.; Klock, B.; Camosci, D.A. *et al*: Microbiologic effects of SnF<sub>2</sub> and NaF mouthrinses in subjects with high caries activity: Results after one year. *J Dent Res*, 62:907-911, August, 1983.

---

#### PATHOGENESIS OF DENTAL DEFECTS IN THE PREMATURE INFANT

The aetiology of calcium disturbances is complex and probably results from several interacting factors. Two-thirds of the newborn's stores of calcium and phosphorus are accumulated during the third trimester of pregnancy, and a premature infant born prior to about 28 or 30 weeks gestation would have missed much of this mineral accretion. Further, when the umbilical cord is clamped at birth there is an abrupt cessation of the maternal supply of calcium and phosphate leaving the infant to draw from its own stores or to derive these minerals from exogenous sources in order to maintain adequate serum levels. Even in a normal full-term infant, in the first few hours after the umbilical cord is clamped, hypocalcaemia is frequently encountered as the newborn attempts to adjust to the cessation of the maternal supply of calcium. Homeostasis is frequently achieved by increased activity of the parathyroid glands and increased absorption of vitamin D and calcium from the gastrointestinal tract.

In the premature infant, compensation for the cessation of maternal supply of mineral may not be adequately achieved due to immaturity of the parathyroid glands. In addition, liver and kidney immaturity may result in defective vitamin D metabolism. Failure to supply adequate calcium and phosphate as well as from intestinal absorption are also important factors.

Seow, W. Kim: Oral complications of premature birth. *Australian Dent J*, 31: 23-29, February, 1986.

---



# Consequences of endodontic treatment in primary teeth

## Part I: A clinical and radiographic study of the influence of formocresol pulpotomy on the life-span of primary molars

W.E. van Amerongen, DDS, PhD  
 G. R. Mulder, DDS  
 P. A. Vingerling, PhD

**T**here is as yet no consensus on the proper treatment of the pulp of primary teeth. Possibilities range from direct capping to total extirpation; but the most widely used treatment is pulpotomy, a procedure that includes removal of the coronal pulp, while the coronal end of the root pulp is covered with a preparation that contains either calcium hydroxide or formaldehyde. Although the procedures with the two preparations are virtually the same, the objectives are essentially different. Calcium hydroxide is used in an attempt to maintain the vitality of the pulp tissue in the root canal, whereas partial devitalization and fixation are intended when formaldehyde preparations like formocresol are applied. Studies of the results obtained with both methods give the impression that formocresol pulpotomy as a rule is more successful. The success rate of calcium hydroxide pulpotomy is usually less than 60 percent, whereas that of formocresol pulpotomy often exceeds 80 percent.<sup>1-10</sup> In part, because of these findings, we decided to use a formocresol-pulpotomy technique in the treatment of pulp lesions of the primary teeth.

The questions arise whether we made the correct choice and how we should determine the success of the treatment. With these questions in mind, we evaluated treatment results and analyzed the factors underlying

the failures. The next question considered in this study is whether formocresol pulpotomy influences the life-span of teeth. Because primary teeth often have to function longer than three years after pulpotomy, the study focuses especially on the life-span of primary teeth, following formocresol pulpotomy.

Since all primary teeth function only temporarily and similar teeth function roughly the same length of time under normal conditions, we made paired comparisons of primary molars with and without formocresol pulpotomy.

Table 1 □ Age (in years) at which a formocresol pulpotomy was performed.

AGE	BOYS	GIRLS	TOTAL
4	11	6	17
5	9	9	18
6	15	11	26
7	21	14	35
8	19	12	31
9	11	7	18
10	5	2	7
<b>TOTAL</b>	<b>91</b>	<b>61</b>	<b>152</b>

Table 2 □ Distribution of the pulpotomies among the maxillary and mandibular first and second primary molars.

	54+64	74+84	55+65	75+85	TOTAL
BOYS	18	19	28	26	91
GIRLS	23	11	7	20	61
<b>TOTAL</b>	<b>41</b>	<b>30</b>	<b>35</b>	<b>46</b>	<b>152</b>

Dr. W. E. van Amerongen is head of the Division of Pediatric Dentistry; Mrs. G. R. Mulder is on the staff of the same division; Dr. P. A. Vingerling is on the staff of the Biomaterials Department, Free University, Amsterdam, The Netherlands.

In principle, formocresol is a toxic substance, harmful to healthy tissue. Moreover, properties ascribed to formaldehyde make its use less attractive.<sup>11,12</sup> Another objective of this study, therefore, is to establish whether this particular therapy influences the development and growth of permanent teeth after exfoliation. This will be discussed in Part II.

## MATERIAL AND METHOD

This study covers all pulpotomies performed by fifth-year undergraduate dental students during the period 1968-1975, in patients born in the period, 1964-1971. It encompasses a total of 152 formocresol pulpotomies performed on 141 patients, aged four to ten years (see Table 1). The distribution of the pulpotomies among the various teeth is shown in Table 2.

### Indications for treatment

Pulpotomy was considered to be indicated, if the pulp was exposed by caries or instrumental manipulation, if the pulp was not gangrenous, if radiographs showed no pathological changes, if no abscess formation or fistulization had occurred, and resorption involved no more than one-third of the root.

### Treatment

When the decision was made to treat, a local anesthetic was administered, if the pulp was vital.

To ensure optimal aseptic conditions, a rubber dam was applied and the entire field of operation was disinfected with tincture of iodine. During treatment all instruments were sterilized repeatedly in a ball sterilizer.<sup>13-15</sup>

After removal of the roof of the pulp chamber with a Batt bur, the coronal pulp was amputated as far as the canal entries, using a sharp excavator. Bleeding was as a rule controlled with sterile cotton pellets. Next, a pellet moistened with formocresol was applied to the radicular pulp for five minutes. Closure was effected by first applying a mixture of zinc oxide-eugenol cement and formocresol (equal amounts of eugenol oil and formocresol) to the pulp stump and the floor of the pulp chamber. After the cement set, it was covered with a layer of phosphate cement, whereupon a permanent restoration was placed.

When the pulp was nonvital, however, a sterile cotton pellet with a small amount of formocresol was first enclosed after removal of the coronal pulp and left in situ

for a week. The tooth was restored then in the same way as described for the tooth with a vital pulp. A pulpotomy on vital pulp was thus performed in one session; and on nonvital pulp, in two sessions. After completion of each pulpotomy, a control radiograph of the treated tooth was obtained, and this procedure was repeated every six months, until the tooth was replaced by its permanent successor.

### Method of investigation

The study is based on clinical data recorded at the biannual check-ups, and on interpretation of the radiographs.

### CLINICAL DATA

The clinical data consisted of data collected in the treatment session, and of follow-up data. The data from the treatment session consisted of the following items:

- The patient:* Age and sex were recorded.
- The test tooth:* The number (FDI specification) of the tooth submitted to endodontic treatment and whether the pulp was vital or nonvital at the time of its exposure.
- The control tooth:* The number of the contralateral tooth was likewise recorded. Data on the condition of this tooth were recorded for the benefit of the study of influences on permanent successors. The criteria were: intact, carious or restored. This is discussed in detail in Part II.

### FOLLOW-UP DATA

- Complaints of pain:* At each biannual follow-up the patient was asked to state whether the test and/or the control tooth caused pain.
- Abscesses and fistulae:* The oral mucosa was inspected at each biannual follow-up. Local swellings with or without discharge of pus were recorded.
- The test tooth:* The patient's age at the time of exfoliation or extraction was recorded. After normal exfoliation the patient was asked to report the time of exfoliation as precisely as possible. In the case of extraction, the reason for extraction was recorded. This might be:
  - Caries: The tooth had become so carious that restoration seemed impossible or useless.
  - Abscess or fistula.
  - Radiographic pathology (see interpretation of radiographs).

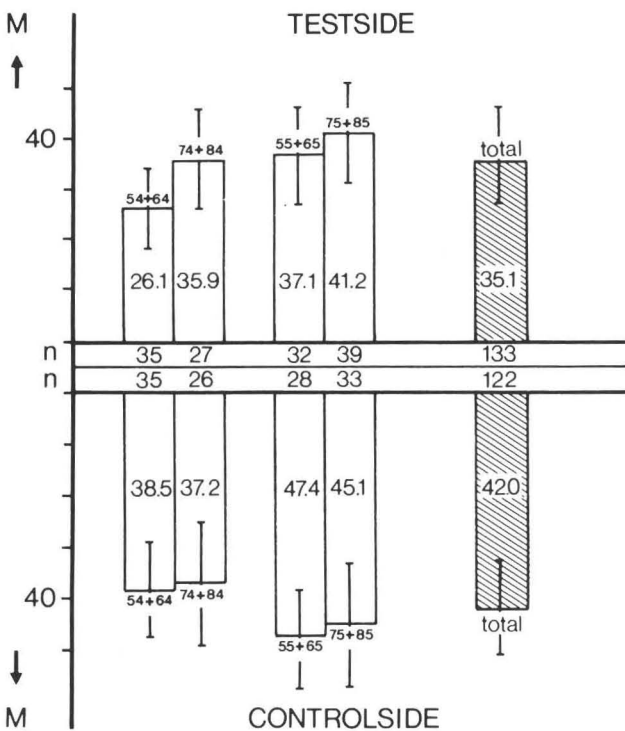
- *The control tooth:* Data analogous to those on the test tooth were recorded.

### Interpretation of the radiographs

The biannual radiographs were used to assess three criteria:

- *Performance of the pulpotomy:* The quality of performance could only be determined by assessing the degree of removal of the pulp roof. When the radiograph showed that this removal had not been complete, the pulpotomy was qualified as poorly done.
- *Bone resorption:* On the basis of interradicular or sometimes periapical radiolucencies it was established whether bone resorption had occurred. When bone resorption occurred, the tooth involved was extracted.
- *Root resorption:* The contours of root and root pulp were examined to determine whether root resorption from causes other than the exfoliation process had taken place. Since only internal root resorption was observed, external root resorption will be left undiscussed. Root resorption likewise invariably led to extraction.

Figure 1. Mean life-span of all primary molars with pulpotomy (test side) and without pulpotomy (control side). M = mean number of months; n = number of teeth.



Based on a comparison of test teeth with control teeth, the life-span of either can be determined and information obtained on factors that may be of influence.

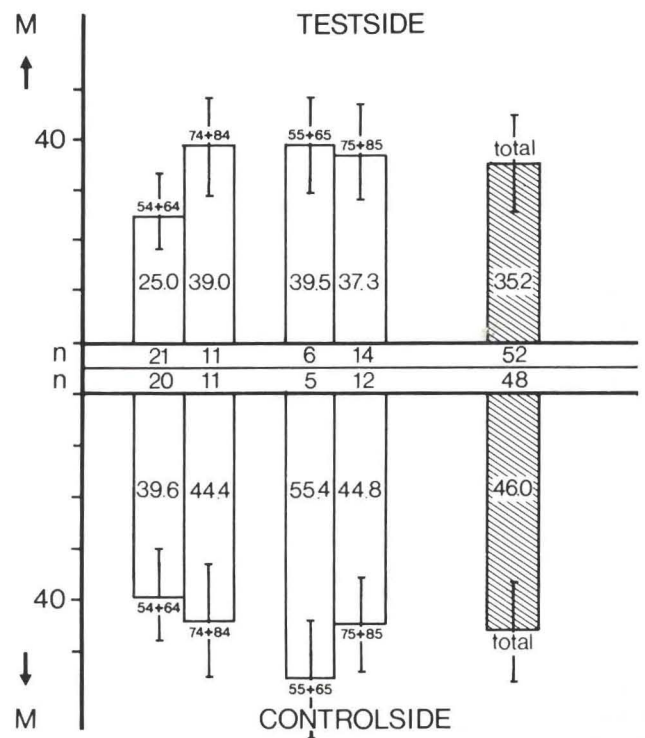
### Statistical analysis

Since presentation and interpretation of the results were the sole objectives, statistical methods were not used in analyzing the data obtained in this study. Only in the comparison of related results was the X<sup>2</sup> test occasionally applied, proceeding from the postulate that the tail probability should not exceed 5 percent.

### RESULTS

During the collection of data, it was found that in a study done in the context of undergraduate teaching, one cannot expect all data to be recorded with great accuracy. Consequently, nineteen of the 152 pulpotomies were not included in the longitudinal study, and thirty of the 152 control teeth were likewise excluded. The mean life-span of all teeth in the test group from the time of pulpotomy was approximately thirty-five

Figure 2. Mean life-span of primary molars with pulpotomy (test side) and without pulpotomy (control side) in girls.



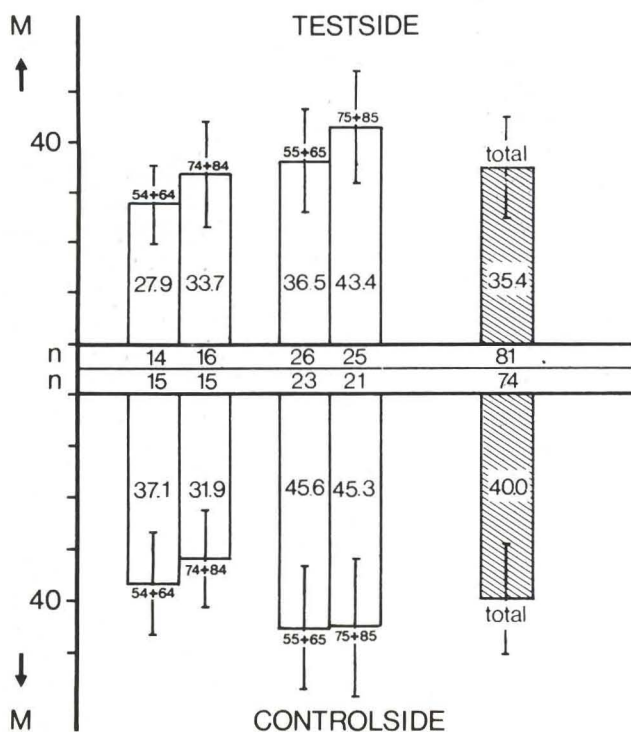
months, whereas that of all control teeth was forty-two months, counting from the time of pulpotomy on the contralateral tooth. Figure 1 shows the mean life-span from the time of endodontic treatment on, both on the test side and on the control side. There was no significant difference in life-span between the primary molars on the test side and those on the control side ( $X^2_3 = 1.32, p = 0.28$ ). When first and second primary molars were considered separately, the difference was still not significant (for  $m_1: X^2_1 = 1.05, p = 0.69$  and for  $m_2: X^2_1 = 0.25, p = 0.38$ ). The same applies to the difference between maxilla and mandible: both on the test side ( $X^2_1 = 0.39, p = 0.47$ ) and on the control side ( $X^2_1 = 0.002, p = 0.04$ ), the difference was not significant. The question is, however, whether the difference is as small as indicated above, under all conditions. This is why we will also discuss the influence on life-span of:

- Sex.
- Premature loss of primary molars as a result of extraction.
- The condition of the pulp at the time of pulpotomy.

**The influence of the patient's sex**

Figures 2 and 3 present the results for girls and boys,

Figure 3. Mean life-span of primary molars with pulpotomy (test side) and without pulpotomy (control side) in boys.



respectively. The mean life-span of the test teeth was thirty-five months in the girls as well as in the boys. On the control side, however, girls and boys differed slightly in mean primary molar life-span (forty-six and forty months, respectively).

The two figures indicate that there were no significant differences: between test and control teeth in boys ( $X^2_3 = 1.28, p = 0.27$ ), between test and control teeth in girls ( $X^2_3 = 1.22, p = 0.25$ ), between test teeth in boys and those in girls ( $X^2_3 = 1.12, p = 0.23$ ) or between control teeth in boys and those in girls ( $X^2_3 = 1.37, p = 0.29$ ).

On the basis of the control teeth, it was thus established that the study did concern comparable groups, with no differences in the mean life-spans of primary molars between girls and boys.

**Premature loss of primary molars as a result of extraction**

Before discussing the influence of extractions on mean life-span, the number of teeth extracted and the indications for extraction should be considered. Table 3 presents a survey of extractions of teeth on the test side as well as on the control side. The Table shows that eleven

Figure 4. Mean life-span of primary molars with pulpotomy (test side) and without pulpotomy (control side) that were not extracted. M = mean number of months; n = number of teeth.

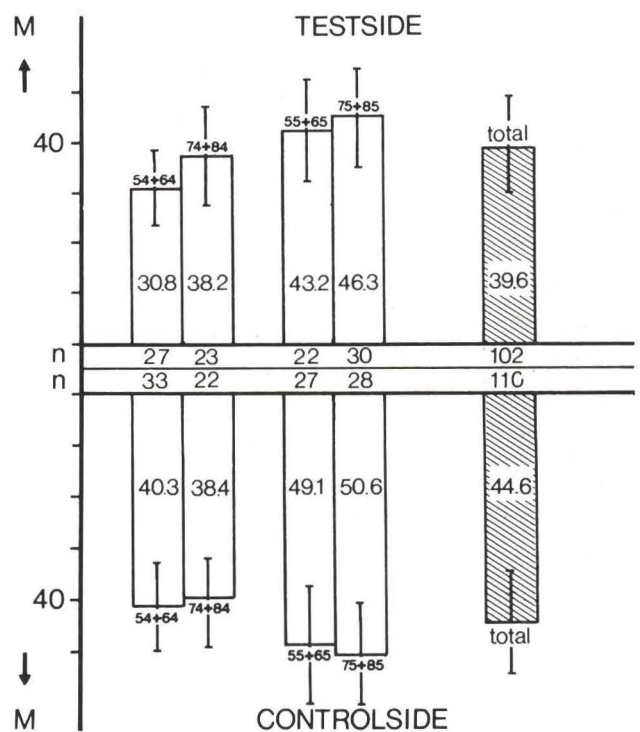


Table 3 □ Number of extracted teeth on the test side and on the control side.\*  
 Footnote: \*0 = caries; 1 = interradiolar or periapical radiolucency; 2 =  
 internal resorption; 3 = clinical evidence of abscess or fistula; 4 = combination  
 of radiolucency and internal resorption; 9 = unknown.

	TESTSIDE						CONTROLSIDE							
	0	1	2	3	4	9	TOTAL	0	1	2	3	4	9	TOTAL
54+64	1	3		2		2	8			1			2	3
74+84	2	1	1			4	4		3	1			2	6
55+65	4		2				10							1
75+85	3	1	1		1	3	9		3	1		1	5	10
<b>TOTAL</b>	<b>10</b>	<b>5</b>	<b>4</b>	<b>2</b>	<b>1</b>	<b>9</b>	<b>31</b>	<b>6</b>	<b>3</b>	<b></b>	<b>1</b>	<b>10</b>	<b>20</b>	

teeth more were extracted on the test side than on the control side, the difference being not significant ( $X^2_5 = 10.4, p = 0.93$ ). Apart from indications that could not be traced, caries proved to be the main indication for extraction of teeth on the test side. Leaving these teeth aside, nearly as many extractions were performed on the test side as on the control side. Returning to the question of the possible influence of premature loss of teeth on the mean life-span of primary teeth with and without formocresol pulpotomy, Figure 4 shows the life-span of all unextracted primary molars on the test side from the time of pulpotomy. The mean life-span of these unextracted primary molars was nearly forty months on the test side and some forty-four months on the control side. The difference in the life-spans of all primary molars (see Figure 1) was four months and two months, respectively, the difference being not significant ( $X^2_3 = 0.11, p = 0.01$  for primary molars on the test side;  $X^2_3 = 0.11, p = 0.01$  for those on the control side).

The findings warrant the conclusion that premature loss of primary molars did not influence the mean life-span of primary molars, regardless of whether or not a pulpotomy had been performed.

**Influence on life-span of the condition of the pulp before endodontic treatment**

As already mentioned, formocresol pulpotomies were performed not only on primary teeth with a vital pulp, but also on those whose pulp was found nonvital when exposed. Figure 5 shows the mean life-span of these teeth after the pulpotomy. The figure indicates that the mean life-span of the ninety-five vital teeth was 35.5 months after the pulpotomy, while that of the thirty-eight nonvital teeth was 30.5 months. This difference, which was not significant ( $X^2_3 = 5.30, p = 0.85$ ), was caused in particular by the two nonvital primary molars in the mandible, one of which was extracted for unknown reasons after only three months. This reduced considerably the mean life-span of this group.

On the whole, ten nonvital teeth were extracted on

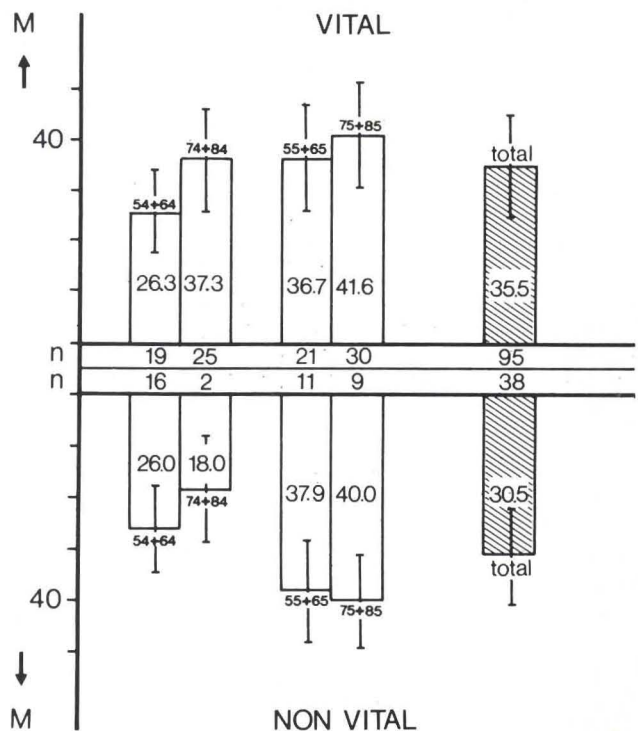
Table 4 □ Number of extracted teeth on the test side.\* Footnote: \*0 = caries; 1 = radiolucency; 2 = internal resorption; 3 = abscess or fistula; 4 = combination of radiolucency and internal resorption; 9 unknown.

	0	1	2	3	4	9	TOTAL
VITAL PULP	7	1	4	2	1	6	21
NON VITAL PULP	3	4				3	10
<b>TOTAL</b>	<b>10</b>	<b>5</b>	<b>4</b>	<b>2</b>	<b>1</b>	<b>9</b>	<b>31</b>

the test side (Table 4); this is one-third of the total number of extractions performed in this test group. In order to establish the possible influence of the condition of the pulp at the time of pulpotomy on subsequent extraction, Table 4 relates the indications for extraction to the condition of the pulp at pulpotomy. In this Table the indications for extraction can be roughly divided into three categories: caries (code 0), inflammation (code 1 through 4), unknown (code 9).

On the basis of this classification, the condition of the pulp at the time of pulpotomy as such proves to have exerted no influence on possible extraction, and therefore on the life-span. After all, the chance that an extracted tooth was nonvital before the pulpotomy turns out to be 33 percent, if the indication for extraction was non-specific; it was likewise 33 percent for each of the categories just named.

Figure 5. Mean life-span of primary molars with pulpotomy performed on vital and nonvital pulp. M = mean number of months; n = number of teeth.



**DISCUSSION**

Although any prolongation of the life-span of teeth through endodontic treatment can be interpreted in a positive sense, endodontic treatment can be described as really successful only if it leads to a lasting condition of dental health.

That this lasting condition is not the same for primary teeth as for permanent teeth is obvious. Lasting dental health for primary teeth is not readily defined. The question is whether the clinical or the histopathological features are taken as determinants. Moreover, assessment of health can be confined to the region treated or extended to encompass the entire organism. Since we proceeded from the postulate that dental treatment of children by undergraduates should approximate the actual practice situation, if possible, this study was confined to registration and evaluation of clinical aspects (including the available bite-wing radiographs). The extraction was one of the principal criteria of evaluation, because it indicated that the life-span of the primary teeth examined has been shortened. Although pain reported by the patient seemed an obvious criterion for a decision to extract, complaints of pain were not recorded in this collection of data. In a number of cases the indication for extraction may have been unknown, because pain was not recorded in writing at the time. This occurred because a patient with acute pain was not treated in the context of teaching in the division of pediatric dentistry, but at the out-patient clinic of the department of dentistry. Another imperfection of this study lies in the interpretation of the bite-wing radiographs. A finding of periapical or interradicular radiolucency always led to extraction of the primary tooth involved; the question, however, is whether bone resorption as a result of an inflammatory process was always discerned. A study by Van der Stelt showed that bone resorption is not radiographically evident until it has advanced into the cortical bone.<sup>16</sup> Although the bone structure in children differs essentially from that in adults, it may be presumed that in children, too, a radiolucency is observed only in a relatively advanced stage of bone resorption. This means that an apparently healthy situation at the time the area is radiographed may in reality be questionable.

If it had been possible to diagnose periapical or interradicular bone resorption in an early stage, this might have exerted some influence on the mean life-span of all primary teeth involved in this study, because not the indication for extraction but the time of extraction would have been adjusted to this.

Table 5 □ Number of imperfectly performed pulpomoties.

54 + 64	6
74 + 84	2
55 + 65	1
75 + 85	4
TOTAL	13

Table 6 □ Indication for extraction of teeth subjected to imperfectly performed pulpotomy.

caries	1
radiolucency	4
int. resorption	0
abscess or fistula	2
radiolucency + int. res.	0
reason unknown	2
TOTAL	9

In part on the basis of those conditions, and in part because abscess formation or fistulization is not always associated with radiographically demonstrable pathological changes, only the clinical observation was recorded in these cases.

It proved difficult to trace the cause of the changes that finally led to a decision to extract. It is a reasonable assumption that the accuracy with which the pulpotomy was performed influenced the ultimate success and, therefore, the life-span of the teeth on the test side. Interpretation of radiographs may give some information on the quality of the pulpotomy, and in particular whether the roof of the pulp chamber was properly removed. Table 5 indicates that thirteen of the 152 pulpomoties were performed imperfectly. This applied in particular to first primary molars in the maxilla. Nine (70 percent) of the thirteen imperfectly pulpomotized teeth were extracted before the time of natural exfoliation. The indications for these extractions are indicated in Table 6. In these cases a causal relationship seems evident. Other causes necessitating extraction have not been defined. Even for the teeth extracted because of caries, the cause cannot be sought in a too-limited prevention program, for in that case extraction of carious primary teeth would have been recorded both on the test side and on the control side (see Table 3). Since such extractions were performed only on the test side, however, the cause cannot be found in poor caries-prevention regimens. Perhaps restorations of test teeth were less durable, facilitating the occurrence of secondary caries. In a number of these cases, restoration may have been either impossible or more or less useless.

The fact that no significant differences in life-spans were found between test teeth and control teeth would seem to warrant the conclusion that formocresol pulpotomy is a successful method of treating primary teeth with exposed pulp.

In this publication, however, the success is limited to primary teeth. As already mentioned, Part II will discuss the question of whether application of formocresol may exert a detrimental influence on the permanent successors.

### SUMMARY AND CONCLUSIONS

In the context of a study of the life-spans of primary teeth subjected to formocresol pulpotomy, 152 such teeth were compared with the corresponding teeth on the contralateral sides. The life-span of each tooth was determined by registration of the time of exfoliation or extraction. In addition, data were collected concerning factors which may influence the life-spans of teeth.

The principal conclusions are:

- There was no significant difference in life-spans between primary teeth with or without pulpotomy.
- Premature loss due to extraction exerted virtually no influence on the mean life-span of primary teeth, regardless of whether a pulpotomy had been performed.
- There was no significant difference in the number of extractions of primary teeth with or without a formocresol pulpotomy.
- There was no significant difference in the mean life-span between primary teeth with vital and those with nonvital pulp at the time of formocresol pulpotomy.

- Imperfectly performed pulpotomies were followed by extraction in 70 percent of the cases.

### REFERENCES

1. Via, W.F.: Evaluation of deciduous molars treated by pulpotomy and calcium hydroxide. *J Am Dent Assoc*, 50:34-43, January, 1955.
2. Magnusson, B.: Therapeutic pulpotomy in primary molars—clinical and histological follow-up. I. Calcium hydroxide paste as wound dressing. *Odontol Revy*, 2:415-431, December, 1970.
3. Schroder, U.: Chronic coronal pulpitis. Agreement between clinical and histologic findings in primary teeth. *Scand J Dent Res*, 85:583-587, November, 1977.
4. Heilig, J.; Yates, J.; Siskin, M. *et al*: Calcium hydroxide pulpotomy for primary teeth: a clinical study. *J Am Dent Assoc*, 108:775-778, May, 1984.
5. Doyle, W. A.; McDonald, R.E.; Mitchell, D.F.: Formocresol versus calcium hydroxide in pulpotomy. *J Dent Child*, 29:86-97, second quarter, 1962.
6. Berger, J.E.: Pulp tissue reaction to formocresol and zinc oxide eugenol. *J Dent Child*, 32:13-28, first quarter, 1965.
7. Redig, D.F.: A comparison and evaluation of two formocresol pulpotomy techniques utilizing "Buckley's" formocresol. *J Dent Child*, 35:22-30, January, 1968.
8. Loos, P.J.; Straffon, L.H.; Han, S.S.: Biological effects of formocresol. *J Dent Child*, 40:193-197, May-June, 1973.
9. Wijnbergen-Buyen van Weelderen, M.G.J. and Burgersdijk, R.C.W.: Een evaluatie van 50 formocresol pulpotomieën, na 3 jaar. *Ned Tijdschr Tandheelkd*, 83:434-436, November, 1976.
10. Boeve, Ch. and Dermaut, L.: Formocresol pulpotomy in primary molars: a long term radiographic evaluation. *J Dent Child*, 49:191-196, May, 1982.
11. Lewis, B.B. and Chestner, S.B.: Formaldehyde in dentistry: a review of mutagenic and carcinogenic potential. *J Am Dent Assoc*, 103:429-434, September, 1981.
12. Zimmerman, R.K.: Formaldehyde use. Letter to the editor. *J Am Dent Assoc*, 103:844, December, 1981.
13. Berghuis, L.P.J.; Schotman, M.D.; Graaf, J. de *et al*: De betrouwbaarheid van de kogelsterilisator. *Ned Tijdschr Tandheelkd*, 91:199-204, May, 1984.
14. Dayoub, M.B. and Devine, M.J.: Endodontic dry heat sterilizer effectiveness. *J Endod*, 2:343-344, June, 1976.
15. Windeler, A.S.; and Walter, R.G.: The sporadic activity of glass bead sterilizers. *J Endod*, 1-8:273-276, September, 1975.
16. Stelt, P.F. van der: Periapical bone lesions. Thesis, August, 1979.

---

### FLUORIDE DISTRIBUTION IN THE MOUTH AFTER RINSING

The observation that fluoride was removed more rapidly from the lower than from the upper vestibule, presumably reflecting the greater influence of secretion and swallowing in this region, illustrates the need to consider dental phenomena such as caries susceptibility not only from the point of view of local factors on the teeth themselves, but with regard to specific local features that clearly exist in the adjacent oral environment.

Weatherell, J.A. *et al*: Fluoride distribution in the mouth after fluoride rinsing. *Caries Res*, 20: 111-119, 1986.

---

# The psychosocial aspects of adolescent pregnancy: a dental perspective

Melanie S. Thwaites, DDS  
Georgeta Manning Cox, DDS, MPH

Adolescence, pregnancy, and a visit to the dentist are perceived by many to be difficult and stressful periods in one's life. The pregnant adolescent who must receive dental care often experiences a situation that is overwhelming, and, therefore, does not seek care unless an emergency arises, or dental treatment is offered as a part of her prenatal care. How a dentist should manage a patient who is still growing physiologically, who is in the process of maturing, and who is also pregnant is an unanswered question. This paper will present some of the psychological and social aspects of the pregnant adolescent, and how the interrelationship of adolescence and pregnancy make an impact on the dental management of these patients.

## REVIEW OF THE LITERATURE

### Adolescence

It is difficult to understand fully the pregnant adolescent, unless an understanding of the adolescent period is obtained. Only second to the much maligned "terrible twos," the period of adolescence has suffered much neglect and misunderstanding by health professionals. Recently, the period of adolescence gained national and

international attention, due primarily to the rise in drug abuse, suicides, and pregnancies.

What is adolescence? It has been thought to be an age of extreme contradictions, self-centeredness, hostility, allusiveness, emotional instability, and self expression. Adolescence is, however, a natural progression toward and a necessary part of the psychosocial maturation of an individual. It extends from age ten to nineteen years. Adolescence is also characterized by patterns or stages of development that are expressed by alterations in behavior and attitude. The behavioral and attitudinal changes are merely signs of the adolescent period. And when properly understood, its demystification can lend itself to the structuring of solutions and approaches that will enable the practitioner to develop an interpersonal relationship with the adolescent.

The psychosocial signs and symptoms of adolescence can be divided into four behavioral and thought processes: pseudostupidity, imaginary audience, personal fable, and apparent hypocrisy.<sup>2,3</sup> The progression through these patterns of development lead to maturation of cognitive tools and the expression of a more adult behavior.<sup>3</sup> As adolescence begins, the ability to think abstractly and to produce possibilities for action from these thought patterns becomes apparent. It is evident, however, that many adolescents cannot effectively utilize this new ability. Consequently, their thoughts and actions are incompatible or inconsistent and the resultant behavior is termed pseudostupidity.

As cognitive thinking further develops, the adoles-

Dr. Thwaites is Assistant Professor in the Department of Pediatric Dentistry and Dr. Cox is Assistant Professor in the Department of Community Dentistry, Howard University College of Dentistry.



cent is able to reflect upon the thoughts of others. The adolescent, however, is unable to control this ability, and this results in inability to discriminate between her thoughts and the thoughts generated by others. Thus the adolescent "creates a world of people who are believed to be thinking what he or she is thinking."<sup>2</sup> This imaginary audience supports, in effect, the concepts they have of themselves. This behavioral trait gives credibility to the thought that adolescents are self-centered.

Parents, teachers, and health professionals consider the adolescent years a most difficult time to handle, in part, because of the manifested behavior called personal fable. During this stage of development, the adolescent fails to understand that he is not unique. The inability to realize this fact often leads to conflict with those in authority. The adolescent has a sense of invulnerability—what can happen to others cannot happen to him. Consequently, the potential to get low grades, to become a drug addict, or to get pregnant can be taken very lightly by the adolescent.

The fourth behavioral pattern that can be seen during this period is the 'apparent hypocrisy'. Often an adolescent will criticize another for behavior that he exhibits. The discrepancies in their thoughts and actions only enhance the belief by parents, teachers and other authority figures that this period of development is plagued with inconsistent and often unstable behavior.

The progression through adolescence occurs with little control by the individual.<sup>4</sup> Early adolescence is a period characterized by the shedding of childhood ways and experimentation with new roles. Middle adolescence is exemplified by socialization and marked peer group identification. During late adolescence the individual exhibits a behavior that strives for control through increased independence.

An understanding of the psychological and behavioral changes of this developmental period called adolescence can have a significant impact on the interpersonal relationship between the individual and health professional, which in turn would have a positive effect on the delivery of health care. Moreover, as understanding and trust are established between doctor and patient, it may be less difficult to get the adolescent to recognize the need for health care and thus actively seek care.

The dentist has a unique role with respect to the adolescent; because this authority figure does not threaten the need for independence, a trusting interpersonal relationship can be easily encouraged and the dentist can become an effective role model.<sup>5</sup> Also the relationship between doctor and patient will aid the

adolescent to put health care in its proper perspective, so that the management of these individuals is positive and not adversarial. Motivation for improved health care can be obtained by seeking cooperation through open communication; thereby, the adolescent assumes more responsibility for exhibiting increased adult behavior. The involvement of the patient in every aspect of the dental health treatment, from appointment scheduling to the practice of plaque disclosure and removal, will significantly enhance the adolescent's ability to function in the real world and provide an environment that will ultimately lead to behavioral modification.

### Dental adolescent

During adolescence there are specific dental health care needs that are reflective of this transitional stage of development. Several U.S. Public Health studies have observed the DMF rate of the adolescent to increase and then level off at the onset of adulthood.<sup>6,7</sup> This value, however, reflects the increase in proximal surfaces as the eruption of the molar teeth and changes in dietary habits take place. Also inconsistently poor oral hygiene practices are major factors for the increase in periodontal disease seen during adolescence. Other dental concerns include malocclusions, esthetic appearance, athletic and other traumatic injuries, and the effect of hormones on oral tissues. Moreover, the dentist must consider other health issues, in order to treat the patient effectively: drug abuse, smoking habits, psychological problems, infections, phobias, and improper diet will influence the management of a patient.

Between ages ten to twenty years, over a third of facial growth occurs, making this developmental period critical for proper diagnosis and treatment of any resultant malocclusion.<sup>8</sup> Hormonal influences on the oral tissues can lead to several gingival abnormalities. Puberty gingivitis is a condition that arises primarily in children eleven to seventeen years of age, and is possibly due to a modified hormonal influence on gingival tissues that respond to poor oral hygiene.<sup>9</sup> Gingivitis associated with pregnancy and oral contraceptives use also afflicts the pregnant adolescent and sexually active adolescent. Viral and infectious diseases can affect the gingival and other oral tissues. Acute necrotizing ulcerative gingivitis, juvenile periodontitis, recurrent aphthous stomatitis, and infectious mononucleosis are but a few of the entities seen in the mouth. Moreover, sexual diseases can be transmitted orally and are associated with palatal erythema or petechiae, gonococcal lesions and genital warts.<sup>1</sup>

Drug abuse, which also afflicts this age-group, results in neglect of hygiene and patient management problems. Smoking and chewing tobacco irritate oral tissues, causing significant mucosal and gingival changes, such as generalized erythema and hyperkeratosis.<sup>10</sup>

### Pregnant adolescent

The psychosocial profile of the pregnant adolescent depicts one who strives to be independent, and has a strong desire to be cared for and cuddled, with an unconscious wish to create and nurture a child.<sup>11</sup> The etiological factors contributing to adolescent pregnancy are little parental supervision, parental loss, history of drug use, minimal education, early menses (12.6 years mean age), and antisocial tendencies (unreliability, social deviancy and conflict, egocentricity and impulsiveness).<sup>12</sup> "Unstable parental and family relationships which produce traumatic effects among children" also contribute to adolescent pregnancy.<sup>13</sup> The pregnant adolescent is at a great risk, because of the increased incidence of excessive weight, toxemia, fetal-pelvic mortality and maternal mortality.<sup>11</sup> Special concerns for treating the pregnant adolescent as a dental patient include: diagnostic radiation, drugs (anesthetics, sedatives, analgesics, tranquilizers and antibiotics), nutritional deficiencies, and physiological and psychological stresses which are potentiated by the pregnancy.

Very few dental surveys of pregnant patients are documented in the literature. Chapman *et al* found that while 30 percent of the patients surveyed were experiencing dental pain and 61 percent needed some form of dental care, only 8 percent were advised to seek dental treatment by their physicians, although all patients were currently receiving medical care.<sup>14</sup> This study points out the importance of dental care before and during pregnancy. The adolescent population is particularly vulnerable, because of the overall increase in the incidence of decay, during the developmental period.

### DENTAL MANAGEMENT OF THE PREGNANT ADOLESCENT

During pregnancy the health of the fetus is as important as the health of the mother. Treatment of the pregnant patient, therefore, must be planned, and collaboration between physician and dentist must be continuous. Elective procedures should be completed after the delivery of the child. The most appropriate time for non-elective procedures is during the second trimester.<sup>15</sup>

Emergencies, however, must be handled at any time during the pregnancy with the utmost caution.

The most significant objective of dentistry is to complete routine procedures with the least amount of discomfort. The pregnant patient is at great risk. During the first trimester, organogenesis is occurring and the fetus is very sensitive to external and internal stimuli. Radiographs of the pregnant patient can be taken at any time, but the dentist must protect the patient and fetus by the use of a lead apron.<sup>16</sup>

Many dental visits during pregnancy are emergency visits, and management of the patient requires the cooperative efforts of obstetrician and dentist. Local anesthetics and analgesics have been found to cross the placenta.<sup>17,18</sup> Local anesthetics can be used in the pregnant patient, but the addition of a vasoconstrictor will help slow absorption of the anesthetic solution.<sup>19</sup> A mild sedative or narcotic may be appropriately used to reduce anxiety in the pregnant patient.<sup>20,21</sup>

Stress, which can be in the form of frustration, conflict or pressure, causes alterations in behavior to alleviate the stress.<sup>22</sup> The treatment of the pregnant adolescent is challenging for the dentist, because the emotional support of the family and society at large is often lacking.

Consequently, events such as emergency or nonelective dental procedures present overwhelming situations for the adolescent. The behavioral patterns of pseudostupidity, imaginary audience, personal fable and apparent hypocrisy may be exacerbated. It is often more important for the dentist to listen and seek out the underlying reason for the behavior manifested in the dental office. Persistence and openness will aid the dental professional in establishing a positive interpersonal relationship between doctor and patient.

Moreover, the dentist must be concerned with the position of the chair. Supine hypotension syndrome can occur in a pregnant patient, particularly during the third trimester (the weight of the uterus compresses the vena cava causing hypotension in the semireclining position).<sup>16</sup>

In summary, the successful management and treatment of a pregnant adolescent requires that the dentist:

- Understand adolescence.
- Remember the special dental concerns of the adolescent: esthetics, malocclusions, management of injuries.
- Maintain easy communication between doctor and patient.
- Involve the adolescent in the treatment process.
- Do nonelective procedures during the second trimester.

- Do emergency procedures with caution when they occur, and only after consultation with the patient's physician.
- Take the least number of radiographs needed to give the best diagnostic view of the involved area.
- Always protect the patient and the fetus with a lead apron.
- Use the minimal amount of local anesthetic with a vasoconstrictor needed to assure comfort for the patient.
- Use general anesthesia only if necessary.
- Take special note of how the patient is positioned in the dental chair, particularly during the late second trimester and third trimester periods.

## CONCLUSIONS

The prevalence of adolescent pregnancy is rising. The dental professional should understand adolescence, to keep communications open between doctor and patient. Moreover, the adolescent period is a time of increased dental concerns: caries rate, esthetics, presence or absence of malocclusions, and incidence of traumatic injuries. It is the combination of accepted dental practices and the knowledge and understanding of adolescence and pregnancy that will aid the professional to treat the pregnant adolescent successfully.

## REFERENCES

1. Casamassimo, P.S.; Pinkham, J.R.; Steinkle, D.: Dental health needs of the adolescent. *Pediatr Dent*, 1:129-137, 1979.
2. Albino, J.E.; Tedesco, L.A.; Phipps, G.T.: Social and psychological problems of adolescence and their relevance to dental care. *Int Dent J*, 32:184-193, 1982.
3. Elkind, D.: Understanding the young adolescent. *Adolescence*, 13:127-134, 1978.
4. Enright, R.D.; Lapsley, D.K.; Shukla, D.G.: Adolescent egocentrism in early and late adolescence. *Adolescence*, 14:687-695, 1979.
5. Hollon, T.H.: The psychology of adolescence. *Dent Clin North Am*, 13:289-301, 1969.
6. National Institute of Dental Research: The prevalence of dental caries in United States Children, 1979-1980, National Dental Caries Prevalence Survey, NIH Pub. No 82-2245. Washington, D.C.: U.S. Department of Health and Human Services, December, 1981.
7. Kelly, J.E. and Harvey, C.R.: Decayed, missing and filled teeth among youths 12-17 years, vital and health statistics: Data from the national Health Survey, Series II, No. 14 DHEW Publication No. (HRA) 75-1626, 1974.
8. Graber, T.M.: *Orthodontics*, 2nd ed. Philadelphia: W. B. Saunders Company, 1969.
9. Sutchiffe, P.: A longitudinal study of gingivitis and puberty. *J Periodont Res*, 7:52-58, 1972.
10. Baer, P.N. and Benjamin, S.D.: Periodontal disease in children and adolescents. Philadelphia: J. B. Lippincott Co., 1974.
11. Osofsky, J.D. and Osofsky, H.J.: Teenage pregnancy: psychosocial considerations. *Clin Ob Gyn*, 21:1161-1173, 1978.
12. Kane, F.; Moan, D.; Bolling, B.: Motivational factors in pregnant adolescents. *Dis Nero Syst*, 35:131-134, 1974.
13. Kruk, S.: Pregnancy and the single woman. In *Pregnancy: a psychological and social study*, Wolkind, S., Zajickl. London: Academic Press Inc., 1981.
14. Chapman, P.J.; Mackay, E.V.; McDonald, A.M. *et al*: A dental survey of an antedental population. *Aust Dent J*, 261-263, 1974.
15. Lloyd, P.F.: Pregnancy and dentistry. *J Dent Assoc S Africa*, 34:763-765, 1979.
16. Lyon, L.Z. and Wishan, M.S.: Management of pregnant dental patients. *Dent Clin North Am*, 623-634, November, 1965.
17. Sweet, J.B.: Pregnancy—associated dental problems. *Contemp OB/GYN*, 16:33-38, August, 1980.
18. Rood, J.P.: Local analgesics during pregnancy. *Dental Update*, 8:483-485, 1981.
19. Beck-Coon, R.J. and Beck-Coon, K.A.: Dental treatment in the pregnant or nursing patient. *Gen Dent*, 30:237-240, 1982.
20. Pedersen, H. and Finster, M.: Anesthetic risk in the pregnant surgical patient. *Anesth*, 51:439-452, 1979.
21. Gier, R.E. and Jones, D.R.: Dental management of the pregnant patient. *Dent Clin North Am*, 27:419-428, 1983.
22. Cinotti, W.R.; Grieder, A.; Springob, H.K.: Human adjustment and mental health. In *applied psychology in dentistry*, 2nd ed. St. Louis: C.V. Mosby Co., 1972.

---

## FORECLOSED OPTIONS

Most well-off American teenagers look forward to summer as a time of increased options: to travel, have fun, pursue hobbies, or make a little money.

But for many young people who are growing up poor, these options largely are foreclosed. They must compete for scant work opportunities and crowd into inadequate recreational facilities. Many end up with few positive things to do, spending the summer adrift and without a productive connection with their communities. For them, summer can be merely a gap between semesters of school.

CDF Reports, July, 1986.

---

# Supernumerary mandibular premolar: the importance of radiographic interpretation

Clara Turner, DMD  
Clem J. Hill, DMD

**S**upernumerary teeth are frequently found in both the primary and permanent dentitions. Routine dental examinations reveal most supernumerary primary teeth are asymptomatic and erupt into good arch alignment.<sup>1</sup> It is likely many such teeth exfoliate without being recognized as supernumerary. In the permanent dentition, the presence of a supernumerary tooth often results in a variety of irregularities in the occlusion, and disruptions in the pathway and sequence of eruption. Supernumerary teeth are seen most frequently in the maxillary anterior region, and more commonly in the permanent dentition.<sup>2</sup> The incidence of supernumerary teeth is approximately one for every 110 children, and the ratio of prevalence in the maxilla to mandible is 8 to 1.<sup>3,4</sup> The incidence of supernumerary premolars is reported to be 1 in 10,000 individuals.<sup>5</sup> They occur more frequently in the mandible than in the maxilla and tend to resemble normal teeth in shape and size.<sup>6</sup> In most cases, supernumerary mandibular premolars are located lingually and apically to the normal premolar.

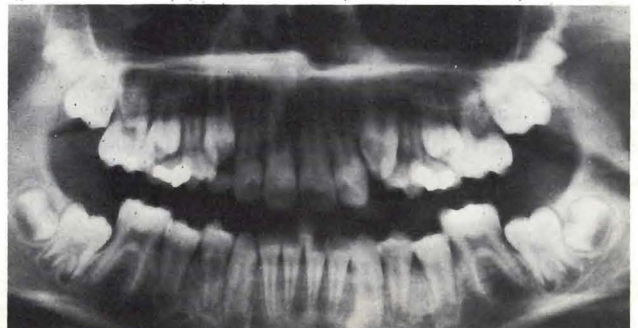
The most effective method of diagnosing supernumerary teeth is by interpretation of a radiographic survey. Many dentists have decreased the number and frequency of dental radiographs, because of an increased public and professional concern over radiation. Consequently, the possibility of missing supernumerary teeth is greatly increased. The purpose of this paper

is to describe a patient in whom a mandibular supernumerary premolar developed late and was not diagnosed, due to the lack of a thorough radiographic examination.

## CASE REPORT

W.B., a ten-year, nine-month-old white male, presented to the University of Florida, College of Dentistry, Pediatric Dental Clinic for a routine dental examination. Review of the medical history revealed W.B. to be in good health; the only positive findings were the history of a broken arm and a tonsillectomy. The dental examination found all oral and facial soft tissues to be within normal limits. The late mixed dentition revealed several caries lesions. The maxillary second primary molars, maxillary right and mandibular left first permanent molars had amalgam restorations. The

*Figure 1. Panorex film taken on initial dental examination.*



Dr. Turner and Dr. Hill are with the University of Florida, College of Dentistry, Department of Pediatric Dentistry.

molars were in a Class I occlusion with minimal crowding. Panoramic and bitewing radiographs (Figures 1 and 2) showed no morbidity other than that noted in the clinical examination. W.B. was scheduled for several dental appointments, in which he had a dental prophylaxis, topical fluoride treatment, and restoration of all caries lesions. He was then placed on recall and was observed approximately every six months thereafter. Recall visits routinely included dental examination, bitewings, dental prophylaxis and topical fluoride. Bitewing radiographs were taken at the time of recall over the next six years. Sample films (Figures 3-5) were selected at approximately 1.5-year intervals. All bitewings taken on recall examinations during this period were interpreted as negative, in regard to pathological findings. No panorex or periapical films were taken, due to the lack of positive indications. Bitewings (Figure 6) taken on a recall visit almost seven years from the initial examination and at the age of seventeen years revealed evidence of a supernumerary mandibular right premolar. Panorex and periapical films (Figures 7 and 8) were taken and verified this finding. They showed also that the four third molars were developed and impacted. W.B. was referred to an oral surgeon for evaluation and, subsequently, removal of the supernumerary right mandibular premolar and the third molars. Extraction is the recommended course of treatment for supernumerary teeth, unless removal is hazardous to adjacent dental structure, contraindicated by a compromised medical status, or if the supernumerary teeth can be used for orthodontic purposes.

On W.B.'s next recall visit, a panorex and periapical radiographic (Figures 9 and 10) examination showed normal healing and no postoperative complications from removal of the supernumerary premolar and the third molars.

## DISCUSSION

Supernumerary teeth are uncommon in the mandible, even though premolars are the most common supernumerary teeth found in the mandibular arch.<sup>5,6</sup> The development of a supernumerary tooth is usually delayed compared to similar teeth of the normal dentition: a delay that may be as long as ten years. In cases, such as the one reported here, where the supernumerary tooth is asymptomatic and positioned in the apical area of the premolars, below the range of a mounted bitewing film, a more accurate diagnosis can be made from a full-mouth radiographic survey, panorex or full-mouth series. A panorex or full-mouth radiographic examination should be completed for all new patients and repeated at

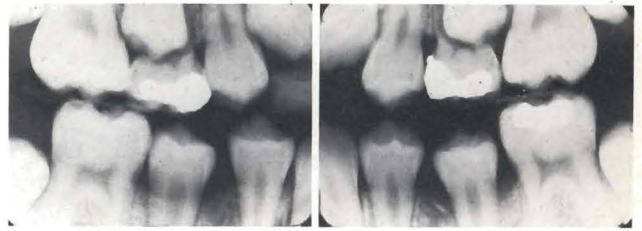


Figure 2. Bitewing films taken on initial dental examination.

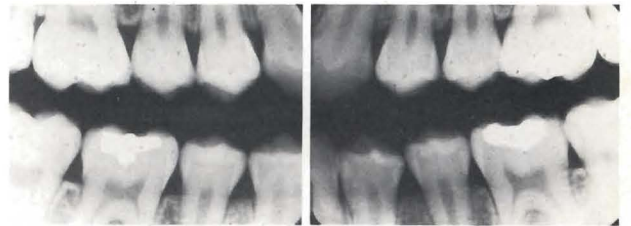


Figure 3. Bitewing films taken on recall approximately 1.5 years after initial examination.

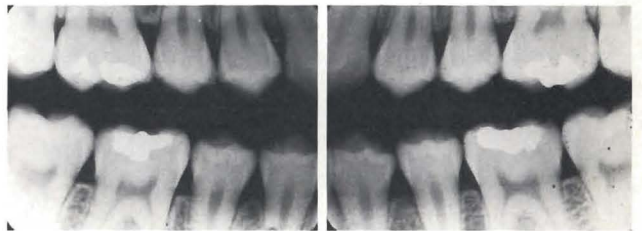

Figure 4. Bitewing films taken on recall approximately three years after initial examination.

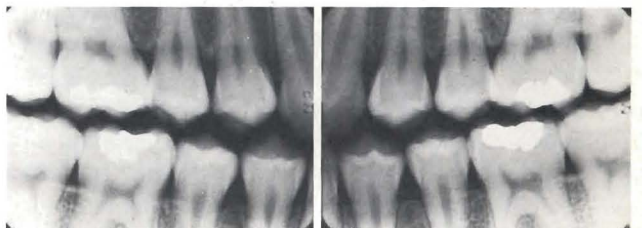

Figure 5. Bitewing films taken on recall approximately five years after initial examination.

about five-year intervals. In addition, a complete interpretation of each film is necessary, to avoid diagnostic errors. For example, in this case, the crypt of the supernumerary premolar was present long before the tooth was detected. Evidence of a developing crypt can be located in the area of the mandibular right first premolar on the initial panorex (Figure 1).

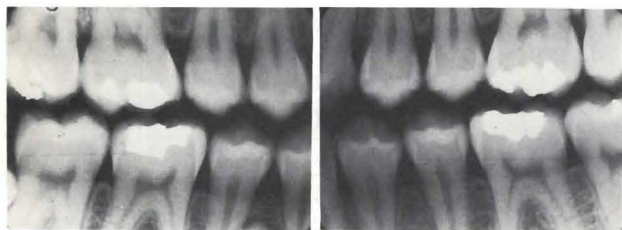

Figure 6. Bitewing films taken on recall approximately seven years after initial examination. Patient was seventeen years old at the time these bitewings were taken.

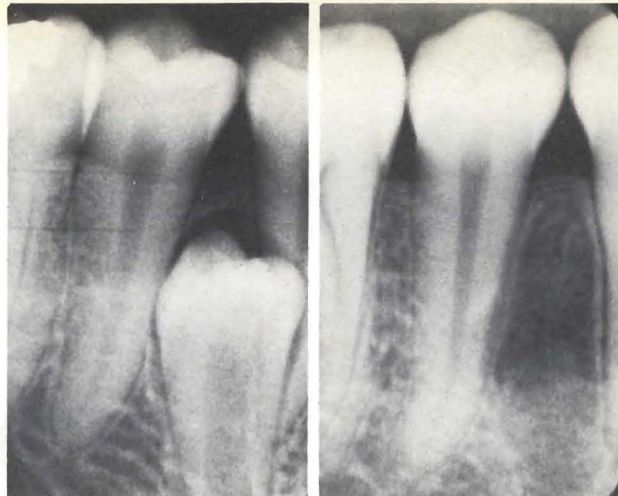

Figure 8 (above, left). Periapical film showing supernumerary mandibular right premolar.

Figure 9 (above, right). Postsurgical periapical film of the area of the supernumerary premolar.

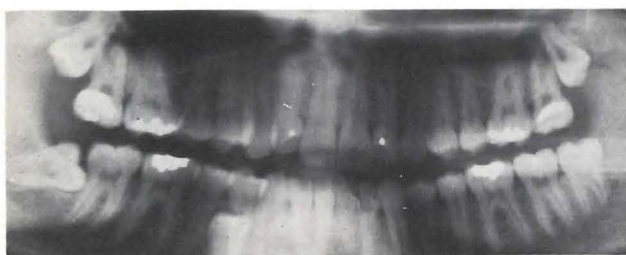

Figure 7. Panorex film taken at same appointment as the bitewings shown in Figure 6.

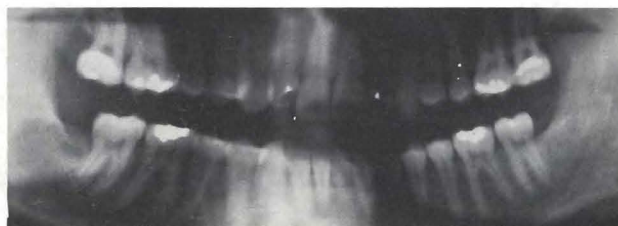


Figure 10. Panorex postsurgical removal of the third molars and the supernumerary premolar.

#### REFERENCES

1. Tremouth, M.J. and Bedi, R.: Supernumerary primary first molar and first premolar: Clinical report. *Ped Dent*, 5:214-216, Third quarter, 1983.
2. Shapira, Y. and Denlivanis, H.: Bilateral premolar-like maxillary supernumerary molars. *Va Dent J*, 58:16-17, December, 1981.
3. Stafne, E.: Supernumerary teeth. *Dent Cosmos*, 74:653-659, 1932.
4. Schulze, C.: Incidence of supernumerary teeth. *Dent Abstr*, 6:23, 1961.
5. Poyton, G.H.; Morgan, G.A.; Crouch, S.A.: Recurring supernumerary mandibular premolars. *Oral Surg*, 13:964-966, 1960.
6. Winkler, S.; June, E.; Lesser, G.V.: Supernumerary mandibular bicuspid. Report of a case. *NY State Dent J*, 38:556-557, November, 1972.

---

#### SUPERNUMERARY TEETH

There is a definite tendency for each tooth to duplicate itself, and this tendency in most instances is a familial one. Osborn (1912) stated, "The paleontological record of the evolution of teeth, which is fairly complete in all mammalian orders, lends no support to the theory of atavism as applied to supernumeraries." Supernumerary teeth are not limited to the permanent dentition. The incidence of occurrence is approximately 1 in 100 persons, and the ratio of occurrence in the maxilla to occurrence in the mandible is about 8 to 1 (Stafne, 1932). The ratio of unerupted supernumerary teeth to those that erupt is about 5 to 1; therefore, the majority of them can be demonstrated by means of the radiograph only.

Gibilisco, J.S.: Stafne's Oral Radiographic Diagnosis, 5th ed. Philadelphia: W.B. Saunders Company, 1985, pp 19-21.

---

# Eating disorders: anorexia and bulimia nervosas

**Karen B. W. Gross, RDH, MS**  
**Kathleen M. Brough, RDH, MS**  
**Patricia M. Randolph, PhD**

**E**ating disorders have become a serious concern and challenge to health professionals. Anorexia and bulimia nervosas were first documented in early medical literature.<sup>1</sup> Recently they have emerged as potentially life threatening illnesses with distinct physical and oral manifestations. Preoccupation with slimness in our society has resulted in an increase in both conditions. It has been reported that 8 percent to 20 percent of college age women are afflicted with bulimia and 1 percent of white women suffer from anorexia.<sup>1</sup> In general, these eating disorders are most commonly seen in white females belonging to upper socioeconomic groups. The illnesses are not restricted, however, to these groups, since approximately 5 percent of the patients diagnosed as anorectics are male.<sup>2</sup> Prevalence among other racial and ethnic groups has not been documented in the literature.

The dental practitioner sees patients at frequent intervals and may be the professional person to whom the patient feels most comfortable in confiding. From an ethical and legal standpoint, knowledge of the symptoms is imperative, since early diagnosis and treatment are directly related to successful therapy. The purpose of this article is to provide the dentist with current information, to aid in the recognition, diagnosis, treat-

ment, referral, and dental support of patients with eating disorders.

## **BULIMIA**

Both anorectics and bulimics are abnormally concerned with their body size and have an excessive fear of becoming overweight. The difference between the two illnesses is in the manifestations of the conditions. Bulimia (meaning literally "ox hunger") is an abnormal craving for food.<sup>1</sup> Bulimics will gorge themselves with large quantities of food and then eliminate it by vomiting or use of laxatives.<sup>2</sup> Diagnostic criteria for bulimia are listed in the Table. If several of these criteria are observed and the behavior is not caused by anorexia or other physical disorders, bulimia is suspected.<sup>1-4</sup>

Bulimia can exist concomitantly with anorexia nervosa or may follow an episode of anorexia.<sup>5</sup> The latter group of people may initially have had symptoms of anorexia, but were unable to lose weight through restriction. In order to lose, or maintain their present weight, they resort to the binge/purge syndrome.<sup>6</sup> Food consumed during a binge cycle is often high in calories and in extreme cases 50,000 kilocalories may be consumed in a day.<sup>2,3</sup> The frequency of overeating will differ among bulimics. Some will succeed in controlling binge eating for several days, but will eventually succumb to overeating weekly or biweekly. Others will overeat daily, especially during the late evening hours

The authors are with the School of Dentistry, University of Missouri-Kansas City, 650 E. 25th St., Kansas City, MO 64108.

or at night. Russell reported that 66 percent of bulimic patients admitted to binge eating at least once a week and 10 percent admitted to binge eating daily.<sup>7</sup>

Binges are most often followed by vomiting, sometimes as often as fifteen times per day. Sixty to 80 percent of bulimics vomit repeatedly as the primary method of ridding themselves of the engorged food.<sup>8</sup> The gag reflex may be stimulated with a finger or toothbrush handle to produce vomiting, although some bulimics are able to vomit automatically.<sup>7</sup> Purging, the evacuation of the bowels with laxatives or enemas, is another way in which bulimics rid themselves of food. Large amounts of laxatives may be consumed at one time. According to the program manager of an in-patient eating disorders unit, one patient admitted to daily consumption of ninety laxative producing products in order to purge ingested food.

The psychological aspects of bulimia are complex. Attempts to hide the binge/purge behavior from others may lead to feelings of guilt, anxiety, anger, or sadness. Overeating has been interpreted as a way for bulimics to meet an unfulfilled emotional need with the binge/purge syndrome acting as a positive emotional reinforcer.<sup>7</sup> Achievement and maintenance of low weight are perceived as bringing increased attractiveness and more friends.<sup>1</sup>

Systemically, bulimia can cause dangerous complications. Fasting, vomiting, and purging may result in protein malnutrition in addition to weight loss.<sup>2</sup> Excessive vomiting and use of laxatives and enemas lead to dehydration and electrolyte disturbance. Hypokalemia, or loss of potassium, may result in cardiovascular and renal failure.<sup>2</sup> Six to 10 percent of the people afflicted with bulimia for more than ten years

have had cardiac arrests.<sup>9</sup> Vomiting can also cause trauma to the esophagus and lining of the stomach and/or chemical erosion of the teeth.

When bulimic behavior has occurred over long periods of time, it is difficult to disrupt and control. Persistent bulimia can become a lifetime problem.

## ANOREXIA

Anorexia nervosa is less common than bulimia, but psychological symptoms are more complex and, therefore, more difficult to treat. The term anorexia is a misnomer and may lead to confusion. Anorexia means "loss of appetite", whereas the anorectic patient suppresses and denies sensation of hunger. Specific physical and psychological characteristics, listed in the Table, are used in the detection and diagnosis of the disorder. Anorexia is suspected when no physical illness is present to account for these characteristics.<sup>2-4</sup> Commonly, the onset of the illness begins in early adolescence (ages eleven to fourteen), goes through a period of remission and reemerges in early adulthood, typically college age. Fifty-three percent of anorectics are consistent fasters and the other 47 percent periodically experience bouts of gorging, followed by guilt-induced vomiting or purging.<sup>10</sup> The older anorectic may resort to vomiting and purging because of the difficulty in maintaining starvation behavior. Once bulimic behavior begins in the anorectic, the prognosis for successful therapy decreases.<sup>9</sup> Self-induced starvation and binge/purge behavior leads to loss of body fat, decreased metabolic rate and an electrolyte imbalance. These conditions may result in amenorrhea, bradycardia, hypotension or hypothermia. Unlike the bulimic patient, anorectics rarely seek professional assistance and may resist recommendations and offers for help from family members.

Treatment modalities for anorexia and bulimia have included a variety of techniques. Physical stabilization of the seriously compromised patient is of primary importance. Once this has been accomplished, psychological support and reorganization of the pathological behavior are attempted.

## DENTAL MANIFESTATIONS

Dental manifestations in the anorectic and bulimic may include one or more of the following: perimyololysis, an increase in cervical caries, impairment of mucous membranes and periodontal tissue, xerostomia, or chronic swelling of the parotid glands. Perimyololysis is the ero-

Table □ Characteristics of patients with eating disorders.

Anorexia	Bulimia
Abnormal fear of weight gain, distorted body image, and loss of normal body weight (25 percent or more.)	Excessive fear of overweight. Usually within normal weight range.
Self induced starvation.	Compulsive binge eating; inconspicuously eating, vomiting or purging.
Dry skin, brittle fingernails, fine downy hair over entire body (lanugo), loss of hair.	Dry lips; blotched, dry skin from dehydration.
Amenorrhea, hypothermia.	Socially extroverted and gregarious.
Often shy and introverted.	Alternates between self-control and impulsiveness.
High achiever, rigid compliance.	Low self-esteem, depression, guilt feelings following purging.
Feelings of inadequacy and unworthiness.	Often seeks assistance in gaining control of behavior.
Referred for treatment by concerned individual.	



sion of enamel on the lingual, occlusal and incisal surfaces of the teeth. Chemical erosion occurs after the enamel is softened by gastric acids and mechanical erosion results from the tongue or toothbrush moving against the teeth. Perimyolysis, the most commonly identified oral manifestation, is not usually detected until vomiting has persisted for two years.<sup>11</sup> It may be recognized by loss of enamel with rounded margins, a notched appearance on the incisal surfaces of the anterior teeth, amalgam restorations appearing as raised islands, or loss of occlusal contours on unrestored teeth.<sup>12,13</sup> Any chemical erosion identified by the practitioner should be carefully examined, to determine the possible etiology before an eating disorder is suspected. Enamel erosion has been attributed to vomiting as a result of gastric disturbances, high citric acid fruit juice intake, habitual eating or sucking on chewable vitamin C tablets, antabuse therapy for alcoholism, medication containing hydrochloric acid, and exposure to industrial acids.

Reports in the dental literature indicate that increased cervical caries activity among bulimics and anorexics is due to an excess carbohydrate intake during binge episodes; a decrease of the pH, quality, quantity, and buffering capacity of the saliva; and poor oral hygiene.<sup>10,13</sup> Mucous membranes and periodontal tissues may be impaired by xerostomia resulting from dehydration and various vitamin deficiencies. Parotid enlargement (also termed nutritional mumps) which is hypothetically due to malnutrition and work hypertrophy of the glands has recently been reported.<sup>7,14</sup>

When the dental practitioner suspects anorexia or bulimia, care must be taken to determine tactfully whether the observed symptoms are the result of an eating disorder or an unrelated physical problem. The dentist or dental hygienist may express concern about observed oral/physical conditions, question eating habits, query the patient concerning stress or ask if the patient vomits. Patients experiencing vomiting as a result of gastric or physical disturbances will readily admit to the problem, whereas the patient with an eating disorder may deny or underestimate the occurrence of vomiting. Clarification of frequency and reasons for vomiting, in addition to asking whether the patient has heard of anorexia or bulimia may provide an opportunity for the patient to discuss the problem. Identification of in-patient and out-patient treatment facilities, physicians, and therapists who treat eating disorders is necessary so the dental team can refer patients when needed. Once referral has been accomplished, management of

the oral conditions can be coordinated with the therapist.

## DENTAL TREATMENT

The first step in definitive dental treatment is education of the patient regarding the causes of erosion and the effects that dehydration and diet can have on the teeth.<sup>11</sup> Discouraging consumption of cariogenic and erosive foods, while offering recommendations for substitutions, is part of the patient education process. One such substitution is cheese. It is noncariogenic and increases the calcium concentration in saliva, salivary flow, and pH of both saliva and plaque.<sup>15</sup> Sugar-free mints or chewing gum may be useful in stimulating salivary flow, when xerostomia is present. Additionally, artificial saliva can be recommended.

Anorectic and bulimic patients need to be educated in the maintenance of good oral hygiene. Patients should not brush their teeth, however, immediately following a vomiting episode. The acids from the vomitus demineralizes the teeth and toothbrushing may aid in abrading the weakened outer tooth surfaces. Rinsing with sodium bicarbonate or magnesium hydroxide solution immediately after vomiting will neutralize gastric acids in the oral cavity. Neutral pH sodium fluoride rinses (0.5 percent to 2.0 percent) and stannous fluoride gels (0.4 percent) used daily are also recommended to make the teeth more resistant to acid dissolution.<sup>15-17</sup>

These treatments will only stabilize the oral environment. Extensive dental care can commence when the patient has control over the eating disorder. Dental management of these conditions may include acid-etched composite resins for minor areas of erosion, wear and dentin hypersensitivity. In cases of extreme damage, full-crown coverage will protect the teeth from further dissolution and will improve esthetics.<sup>16</sup> A majority of the anorexics and bulimics are self-conscious about their smile, and improving their esthetic appearance will enhance their self-esteem.

When working with these patients, it is important that the dentist's approach be positive and nonjudgmental. The rationale for all the procedures that will be performed should be explained. The dental personnel must be gentle and supportive, while assuring the patient that their problem is not unique and that help is available.<sup>15</sup>

The issue of professional liability has recently arisen concerning the dentist's role in recognition and referral of eating disorder patients. The standard of care that

dental professionals provide is a dynamic, changing process. Since anorexia and bulimia nervosas may initially be detected in the dental office, there is a need to revise the current standard of care to include proper recognition, referral, and dental support of these patients.

#### REFERENCES

1. French, R.N. and Baker, E.L.: Anorexia nervosa and bulimia. *Indiana Med*, 241-245, April, 1984.
2. Lucas, A.R.: Bulimia and vomiting syndrome. *Contemporary Nutrition*, 6:1-2, April, 1981.
3. Lowenkopk, E.L.: Bulimia: Concept and therapy. *Comp Psych*, 24:546-553, November-December, 1983.
4. Herzog, D.B. and Copeland, P.M.: Eating disorders. *N Engl J Med*, 313:295-303, August, 1985.
5. Smith, M.S.: Anorexia nervosa and bulimia. *J Fam Prac*, 18:757-766, May, 1984.
6. Beumont, P.J.; George, G.C.; and Smart, D.E.: Dieters, vomiters and purgers in anorexia nervosa. *Psych Med*, 6:617-622, June, 1976.
7. Russell, G.: Bulimia nervosa: An ominous variant of anorexia nervosa. *Psych Med*, 9:429-448, September, 1979.
8. Wolcott, R.B.; Yager, G.; and Gordon, G.: Dental sequelae to the binge-purge syndrome (Bulimia). Report of Cases. *J Am Dent Assoc*, 100:723-724, November, 1984.
9. Casper, R.; Echert, E.; Halmi, K. *et al*: Bulimia. *Arch Gen Psych*, 37:1030-1035, September, 1981.
10. Stege, P.; Vesco-Dangler, L.; and Rye, L.: Anorexia nervosa: Review including oral and dental manifestations. *J Am Dent Assoc*, 104:648-652, May, 1982.
11. Kleir, D.J.; Aragon, S.B.; and Aurbach, R.E.: Dental management of the chronic vomiting patient. *J Am Dent Assoc*, 108:618-621, April, 1984.
12. Andrews, F.H.: Dental erosion due to anorexia nervosa with bulimia. *Br Dent J*, 152:89-90, February, 1982.
13. Hurst, P.S.; Lacey, J.H.; and Crisp, A.H.: Teeth, vomiting and diet: A study of dental characteristics of seventeen anorexia nervosa patients. *Post Grad Med J*, 53:298-305, June, 1977.
14. Hasler, J.H.: Parotid enlargement: A presenting sign in anorexia nervosa. *Oral Surg*, 53:567-572, June, 1982.
15. Dalin, J.: Oral manifestations of eating disorders. *Bulimia and Anorexia Self Help Newsletter*. 4:3-6, February, 1985.
16. Harrison, J.L.; George, L.A.; Cheatham, J.L. *et al*: Dental effects and management of bulimia nervosa. *Gen Dent*, 33:65-68, January-February, 1985.
17. Helstrom, I.: Oral complications in anorexia nervosa. *Scand J Dent Res*, 85:71-86, 1977.

---

#### PREGNANCY IN ADOLESCENCE

Pregnancy during this time of rapid personal growth and development can impose physiologic as well as psychologic stress on the young mother. Along with her own nutritional requirements, she must also meet the needs of a growing fetus. Fetal nutritional needs are often met at the expense and added risk of the mother. Indeed, increased maternal morbidity and mortality rates occur in this age group. For girls 15 years old or younger, maternal mortality is 46.7 per 100,000 live births compared with 9.2 deaths per 100,000 live births for women between 20 and 24 years of age.

There is also an increased chance of premature deliveries of offspring of mothers 15 years old and younger. This means that the infants of these mothers as well as the mothers are at greater risk. Of children born to these young mothers, 6 percent of the first born and nearly 10 percent of the second born die within the first year of life. Those children who survive are likely to have a 30 percent lower birth weight and are two to four times more likely to have neurologic defects than children who are born to mothers 20-24 years old.

Pollack, R.L. and Kravitz, E.:  
Nutrition in oral health and  
disease. Philadelphia: Lea &  
Febiger, 1985, p 26.

---

# Case reports

## A dental protocol for the pediatric cardiac transplant patient

Robert A. Boraz, DDS

The technique for cardiac transplantation was developed by Lower and Shumway at Stanford University. Current results reveal success rates of 81 percent at one year, 74 percent at two years, and 50 percent at five years.<sup>2-4</sup> Cardiac transplantation surgery is becoming more common everyday and even insurance companies have elevated this mode of treatment out of the experimental status. The indications for heart transplantation are presently ischemic heart disease with severe myocardial involvement that cannot be improved by mere traditional surgery and cardiomyopathy that does not respond to conservative measures.<sup>4-7</sup> The two major problems with cardiac transplantation are the body's rejection of foreign tissue and organ procurement.<sup>1-8</sup>

### REJECTION

Cyclosporine A (CyA) was first described as an immunosuppressive drug by Borel *et al* in 1976.<sup>7</sup> CyA is an extract of the fungi *Cylindrocarpum lucidum* and *Trichoderma polysporum*. CyA acts by suppressing cellular and hormonal immunity without bone marrow depression or prohibitive organ toxicity.<sup>1,9-14</sup> It also does not cause T-cell depletion or decrease *in vitro* immune reactivity. Evidence indicates CyA provides a reversible circulatory inhibitor factor that blocks the ability of an intact immune apparatus from responding to stimulation by the donor antigen.<sup>9,14</sup> Transplantation antigens

are clustered mainly on one chromosome, which in man is the 6th. HLA (human leukocyte antigens) can be detected by serological typing. Typing of these HLA, A, and B antigens permits the choice of more compatible donors.

## PROCUREMENT

The second major problem in cardiac transplantation is suitable organ procurement.<sup>1,8</sup> This problem is closely related to prolonged organ preservation. Since there is not yet a reliable artificial means to increase the survival rate for patients awaiting heart transplantation, human organ procurement is essential.<sup>4,15,16</sup> There are over 100,000 fatal accidents each year in the United States, but few donors are found in the group. A significant advance will occur, if organ freezing can become a reality.<sup>1,9</sup> In 1949, Smith, Polge, and associates discovered that antifreeze (glycerol) would protect spermatozoa for several days at  $-80^{\circ}\text{C}$ . Since then, glycerol and dimethylsulfoxide have been used as cryoprotective agents for freezing RBC, WBC, bone marrow, and skin. The solution would involve the possibility of using liquid nitrogen at  $-196^{\circ}\text{C}$  for freezing organs for months or years. This would allow cardiac transplantation to become an elective, well-matched procedure.

## CAUSES OF DEATH

The two primary causes of death after cardiac transplantation are organ rejection and infection.<sup>17</sup> The advent of CyA improved the delicate balance between preventing organ rejection and encouraging infection. Bacterial infections, viral infections, and fungal infections, however, still remain a life-threatening problem.<sup>1,17-21</sup> Because numerous bacterial infections, viral infections such as cytomegalovirus, and fungal infections such as candidiasis occur in the oral cavity, it is essential that a qualified dentist be a member of any cardiac transplantation team. It is also imperative that an appropriate dental protocol be established to insure proper care for the cardiac transplant patient. With the large increase in cardiac transplant patients, including children, the following protocol for patient management is offered.<sup>22</sup>

## PEDIATRIC CARDIAC TRANSPLANT DENTAL PROTOCOL

- Dental Management prior to transplant
  - Perform a complete examination including a full mouth radiographic survey.
- Eliminate infection.
- Institute periodontal disease control including plaque control, calculus removal, and a complete prophylaxis.
- Provide oral hygiene instruction to patient and parents.
- Remove orthodontic bands and/or appliances.
- Provide custom fluoride trays and 0.4 percent stannous fluoride therapy.
- Utilize American Heart Association regimen for maximum prophylactic antibiotic protection during bacteremia inducing procedures.
- Dental management after transplant
  - Recall the patient every three months for two years for prophylaxis and evaluation.
  - Continue daily fluoride applications for two years.
  - Perform restorative care as needed after consultation with physician.
  - Orthodontic care resumed after one year and after consultation with physician.
  - Utilize American Heart Association regimen for maximum prophylactic antibiotic protection during bacteremia inducing procedures.

## CASE REPORT

G.R. was a three-year-old white male from Topeka, Kansas. He was found to have hepatomegaly on a pre-operative evaluation for a herniorrhaphy. Liver biopsy at that time revealed passive congestion and fibrosis. The patient was referred to the University of Kansas Medical Center where a cardiac catheterization revealed restrictive cardiomyopathy with an increased right ventricular end diastolic pressure and an increased left ventricular end diastolic pressure. Oxygen saturation of the right heart was decreased, indicating a low cardiac output. Pericardial biopsies revealed mild inflammation and fibrosis. The patient was judged a candidate for cardiac transplantation.

G.R. was a full term baby born by spontaneous vaginal delivery. The patient had a herniorrhaphy and two episodes of otitis media. His physical examination revealed a well-developed, acyanotic child in no apparent distress. His lungs were clear to auscultation. Cardiovascular examination revealed his heart had a regular rate and rhythm without a murmur. All pulses were full and equal bilaterally. Evaluation of the extremities failed to reveal any cyanosis, clubbing, or edema.

The patient underwent a cardiac transplant in February, 1985. Postoperative complications included renal

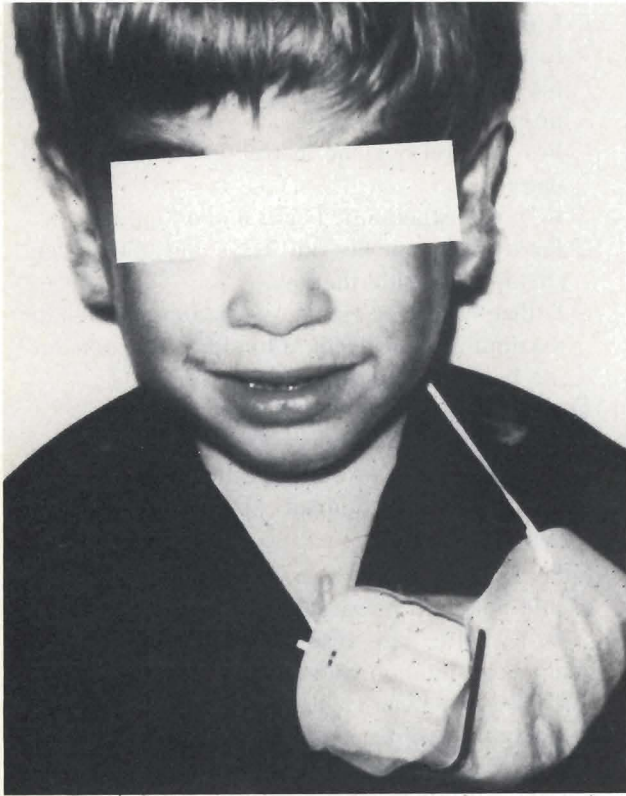

Figure 1. Frontal view of patient, three months after surgery.

insufficiency shortly after surgery secondary to CyA. This was resolved with ethacrynic acid, metolazone, and fluid therapy. The patient also showed signs of pulmonary hypertension, which was successfully treated with nifedipine. The patient suffered a mild rejection reaction at one week that was successfully treated with prednisone. Postoperatively, the patient has had an interval decrease in his liver size and abdominal girth.

Since no dental protocol for cardiac transplant patients was in place at the time of G.R.'s surgery, no preoperative evaluation or other currently recommended treatment was provided. The patient was originally seen in the Dental Clinic at the University of Kansas Medical Center on May 14, 1985 (Figure 1). At that time, the visual and radiographic examination revealed a normal primary dentition. No caries was noted. A moderate gingival hyperplasia and facial hirsutism secondary to CyA therapy were noted (Figures 2 and 3).<sup>23</sup> A dental prophylaxis and topical fluoride application were performed using prophylactic antibiotic coverage of ampicillin 50 mg/kg intramuscularly and gentamicin 2 mg/kg intramuscularly, a half hour before the procedure. This was followed by 500 mg of penicillin V orally, six hours later. Alginate impressions were

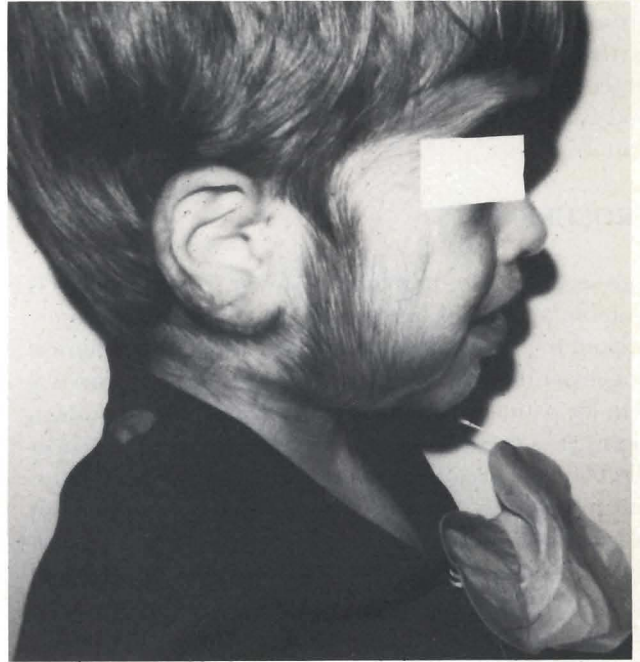
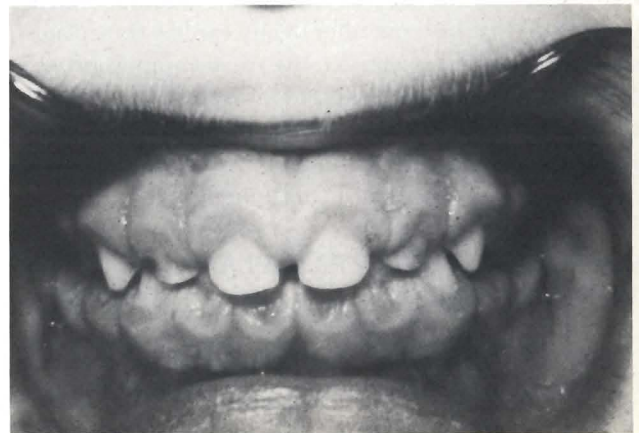

Figure 2. Profile of patient, three months after surgery, showing hirsutism.

taken and custom fluoride trays were fabricated and inserted. The patient was placed on a 0.4 percent stannous fluoride rinse program for five minutes at bedtime. Thorough oral hygiene instructions were provided for the patient and his parents. The patient has been seen in three-month recall visits since and is doing well (Figure 4). He has resumed near normal activities. No new dental problems have been noted. The gingival hyperplasia is slightly improved and the hirsutism is markedly improved (Figure 5).

Figure 3. Intraoral view of patient, demonstrating gingival hyperplasia.



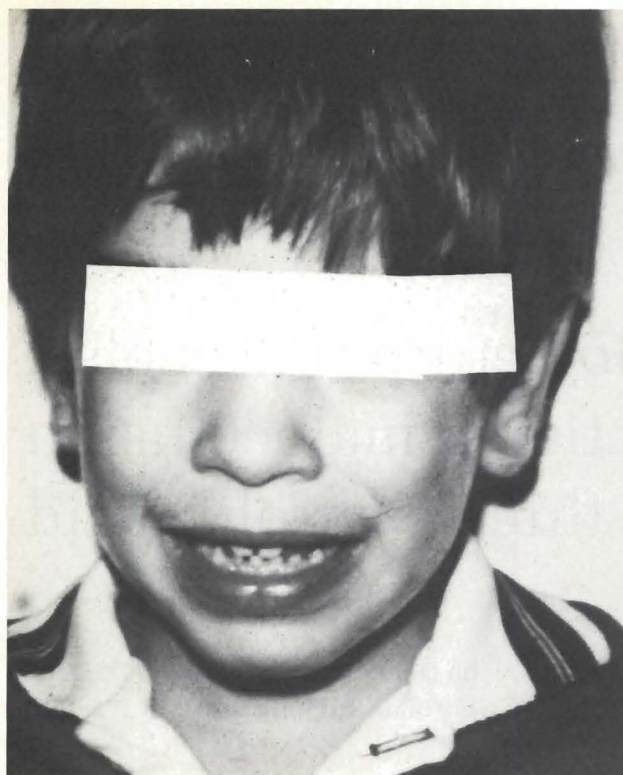

Figure 4. Frontal view of patient nine months after surgery.

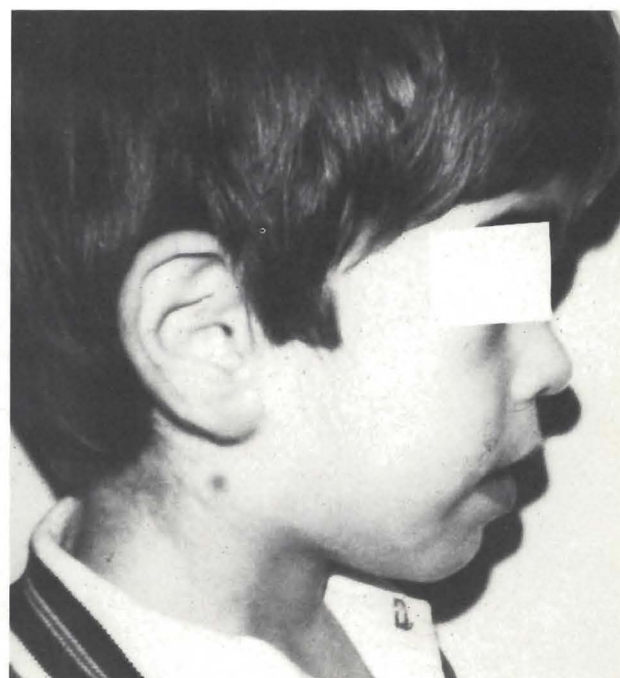


Figure 5. Profile of patient nine months after surgery, demonstrating elimination of hirsutism.

## CONCLUSION

With recent advances in immunosuppressive therapy, improved surgical techniques, and insurance recognition, cardiac transplantation procedures have markedly increased, including those in the pediatric population. Since postoperative infection with organisms frequently found in the orofacial region is one of the two most common causes of death in these patients, it is essential that proper dental management of these patients preoperatively and postoperatively be provided. Since donor procurement is difficult and many patients come to transplant centers from great distances, a definitive dental protocol agreed to by the cardiac transplant team for management of these patients is essential. Failure to provide such services may needlessly increase the morbidity and mortality of cardiac transplantation patients.

## REFERENCES

- Guttmann, F.M.: Organ transplantation in children. *Pediatr Ann*, 11:910-912, 914-915, November, 1982.
- Barnard, C.N. and Cooper, D.K.: Heterotopic versus orthotopic heart transplantation. *Transplant Proc*, 16:886-892, June, 1984.
- Schroer, K. *et al*: Cardiac transplants: the Stanford experience. *AORN J*, 40:220-229, August, 1984.
- Barnard, C.N.; Barnard, M.S. *et al*: The present status of heterotopic cardiac transplantation. *J Thorac Cardiovasc Surg*, 81:433-439, September, 1981.
- Annas, G.J.: Regulating the introduction of heart and liver transplantation. *Am J Public Health*, 75:93-95, January, 1985.
- Jamieson, S.W.: Current controversies in transplantation. *Transplant Proc*, 17:199-203, February, 1985.
- Calne, R.Y.: Transplant surgery: current status. *Br J Surg*, 67:765-771, December, 1980.
- Lehr, J.B.: Progress in long-term organ freezing. *Transpl Proc*, 3:1565, September, 1971.
- Ferguson, R.M.; Fiedelus-Gort, R. *et al*: The immunosuppressive action of Cyclosporin A (CyA) in man. Presented to the American Society of Transplant Surgeons, Chicago, June, 1982.
- Tutschka, P.J.: Cyclosporin A as a tool for experimental and clinical transplantation. *Biomed Pharmacother*, 36:341-344, April, 1982.
- Macek, C.: Cyclosporine's acceptance heralds new era in immunopharmacology. *JAMA*, 250:449-451, 455, July, 1983.
- Mathias, J.M.: Immunosuppression. Post operative management of heart transplant recipients. *AORN J*, 41:748-753, April, 1985.
- Modry, D.L. *et al*: Cyclosporin in heart and heart-lung transplantation. *Can J Surg*, 28:274-280, 282, May, 1985.
- Cohen, D.J. *et al*: Cyclosporine: a new immunosuppressive agent for organ transplantation. *Ann Intern Med*, 101:667-682, November, 1984.
- Hastings, W.L.; Aaron, J.L. *et al*: A retrospective study of nine calves surviving five months on the pneumatic total artificial heart. *Trans Am Soc Artif Intern Organs*, 27:71-75, January, 1981.
- Guttmann, F.M.; Lizin, J. *et al*: Survival of canine kidneys after treatment with dimethylsulfoxide, freezing at  $-50^{\circ}\text{C}$  and thawing by microwave illumination. *Cyrobiology*, 14:559, June, 1977.
- McGiffin, D.C. *et al*: Cardiac transplantation. A review of the experience of the University of Alabama in Birmingham. *Ala J Med*, 20:425-430, October, 1983.
- Clift, R.A.: Candidiasis in the transplant patient. *Am J Med*, 77:34-38, October, 1984.
- Dummer, J.S. *et al*: The effect of cytomegalovirus and Epstein-Barr virus infection on T-lymphocyte subsets in cardiac transplant patients on cyclosporine. *Transplantation*, 39:433-435, October, 1984.
- Copeland, J.F. *et al*: Human heart transplantation. *Curr Probl Cardiol*, 4:1-5, November, 1979.
- Reitz, B.A.: Cardiac transplantation. *JAMA*, 248:1225-1227, September, 1982.
- English, T.A.: Is cardiac transplantation suitable for children? *Pediatr Cardiol*, 4:57-58, January-March, 1985.
- Rateischack-Pluss, E.M. *et al*: Initial observation that Cyclosporine A induces gingival enlargement in man. *J Clin Periodontol*, 10:237-246, May, 1983.

# Bilateral lower lip mucocoeles: cause of functional malocclusion in a three-year-old child

John G. Meechan, BSc, BDS, FDSRCPS  
G. Stewart Blair, BDS, DDS, FDSRCPS, HDD

Oral mucocoeles are common, and the most frequently affected site is the lower lip.<sup>1-4</sup> The sex distribution is approximately equal and all age-groups are susceptible, with the peak frequency reported to be in the second or third decades.<sup>1-4</sup> Mucocoeles, however, are not rare in young children, those under ten years accounting for 12 percent of the cases reported by Standish and Shafer and 16 percent of the Robinson and Hjorting-Hansen series.<sup>1,5</sup> Cataldo and Mosadomi recorded 2.7 percent of their patients with mucocoeles to be less than one year old and their presence has been noted in the newborn.<sup>3,5</sup>

The purpose of this paper is to present a case of bilateral lower lip mucocoeles, which although in themselves symptomless, had produced a functional malocclusion in a three-year-old.

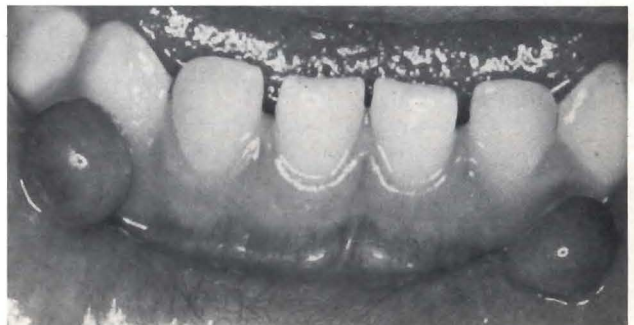## CASE REPORT

A three-year-old girl was referred to the Department of Oral Surgery at the Newcastle upon Tyne Dental School for the treatment of two lumps on the oral aspect of the lower lip (Figure 1). The patient's mother claimed that both lesions had been present without obvious change in appearance since the child was a few days old and certainly preceded the eruption of teeth. They had not

caused the child any problems. On examination, two nontender, bluish, fluctuant swellings of about 6mm in diameter were seen. The clinical diagnosis was of superficial mucocoeles. The child had a complete, caries-free primary dentition and when asked to close her mouth, consistently occluded directly into a unilateral cross-bite. The mandibular midline was shifted almost one tooth width to the left (Figure 2). The mother thought that this was the normal appearance in occlusion. Although the mucocoeles were causing no symptoms, it was felt that this occlusion was perhaps a long standing functional adaptation, produced to avoid trauma to the lesions. It was decided, therefore, to admit the child to hospital as an outpatient, and to excise them under general anesthesia.

Histological examination confirmed the clinical diagnosis; the microscopic appearance was consistent with the appearance of lesions of mucous extravasation.<sup>6</sup>

Figure 1. Location of the mucocoeles.



Dr. Meechan is lecturer in oral surgery; and Dr. Blair is senior lecturer in oral surgery, Department of Oral Surgery, The Dental School, Newcastle Upon Tyne, U.K.

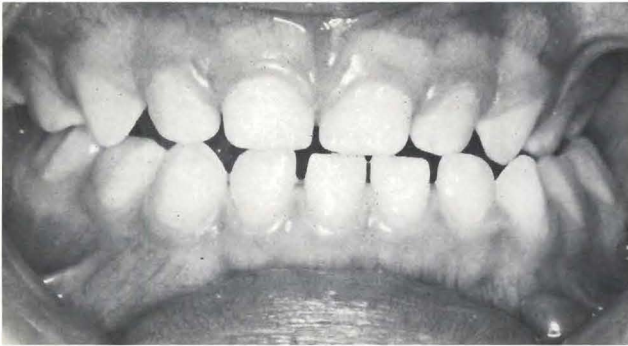


Figure 2. The habitual occlusion before removal of the mucocoeles. There is a cross-bite in the canine-molar region on the left.

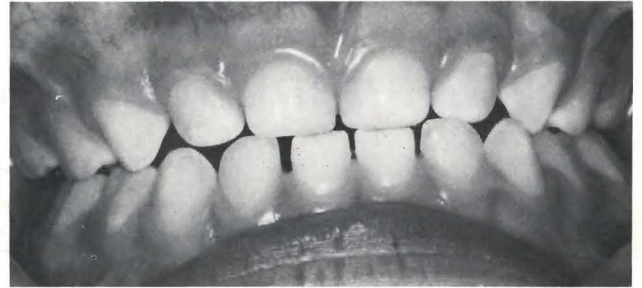


Figure 3. The occlusion three weeks after the mucocoeles were removed. The cross-bite has disappeared.

Healing proceeded uneventfully and three weeks after surgery the occlusion had changed to produce good interdigitation, the cross-bite had disappeared and the maxillary and mandibular midlines were in close approximation (Figure 3). The mother volunteered the information that the child's speech had also improved since the mucocoeles were excised. It appears, therefore, that the mucocoeles, which were present before tooth eruption, had influenced mandibular movements from a very early stage, so that a long standing functional malocclusion developed. Thus, although it is often reasonable to defer surgery in cases where such lesions are not causing obvious symptoms, the effect on mandibular closure should be carefully assessed in young patients.

In conclusion, a case has been presented of bilateral

mucocoeles in the lower lip, which produced a functional malocclusion in a three-year-old girl. The occlusion and speech of the child improved shortly after removal of these otherwise symptomless lesions.

#### REFERENCES

1. Robinson, L. and Hjorting-Hansen, E.: Pathological changes associated with mucous retention cysts of minor salivary glands. *Oral Surg*, 18:191-205, August, 1964.
2. Shear, M.: *Cysts of the oral regions*, 2nd edition. Bristol: Wright, 1983, pp 178-185.
3. Cataldo, E. and Mosadomi, A.: Mucocoeles of the oral mucous membrane. *Arch Otolaringol*, 91:360-365, April, 1970.
4. Sela, J. and Ulmanky, M.: Mucous retention cyst of salivary glands. *J Oral Surg*, 27:619-623, August, 1969.
5. Standish, S.M. and Shafer, W.G.: The mucous retention phenomenon. *J Oral Surg*, 17:15-22, July, 1959.
6. Shafer, W.G.; Hine, M.K.; Levy, B.M.: *A textbook of oral pathology*, 4th edition. Philadelphia: Saunders, 1983, p 558.

---

#### MUCOCELES OF THE ORAL MUCOSA

Mucocoeles may appear as focal reddish-blue elevations if hemorrhage has occurred. As with the conventionally appearing fluid-filled mucous retention phenomena, hemorrhagic mucocoeles follow trauma with rupture or severance of a minor salivary duct with pooling of mucus within the submucosa; they are most frequently encountered on the lips, buccal mucosa, and ventral tongue.

Eversole, L.R.: *Clinical outline of oral pathology*, 2nd ed. Philadelphia: Lea & Febiger, 1984, p 45.

---



# Differential diagnosis of enlarged dental pulp chambers: a case report of amelogenesis imperfecta with taurodontism

Richard P. Elzay, DDS  
Dana H. Chamberlain, DDS

**T**he dentist usually examines dental radiographs for the chief purpose of assessing the severity of dental caries and periodontal disease. The dentist, through this process, routinely notes the radiographic configuration and size of dental pulp chambers and canals. A deviation from the normal that might be observed is enlarged pulp chambers. Since there are several pathological conditions that can be associated with this finding, the practitioner may have difficulty in establishing a definitive diagnosis. To establish a diagnosis in such cases, the practitioner should be cognizant of the pathological conditions associated with enlargement of pulp chambers, some of which occur only rarely, and be mindful also of other salient clinical findings noted in the respective conditions.

The purpose of this paper is to review pathological conditions that are associated with enlarged pulp chambers and present a case of amelogenesis imperfecta associated with taurodontism, to exemplify one of the several conditions manifesting enlarged dental pulps.

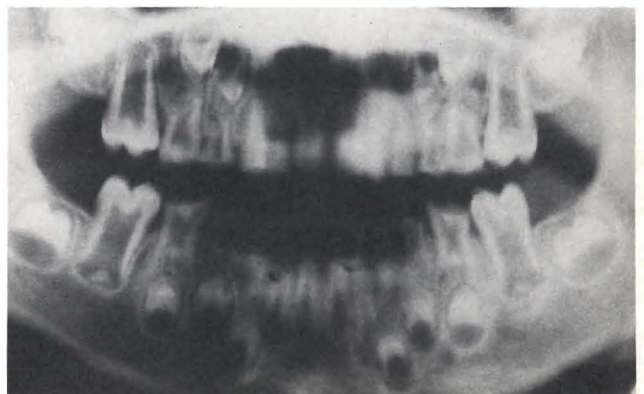
## CASE REPORT

A seven-year-old white female was seen by one of the authors (D.C.). The patient complained that her teeth occasionally hurt. Examination revealed extensive attri-

tion of the primary teeth, resulting in a pulp exposure to the mandibular right second molar. Radiographs revealed enlarged and elongated pulp chambers of all posterior primary teeth and first permanent molars (Figure 1). The enamel of the first permanent molars and central incisors appeared very thin. There was no evidence of mottling or pitting of the enamel (Figures 2 and 3).

The patient did not have siblings. The proband's parents were examined and no unusual dental findings were noted in the father; the mother's teeth, however, did manifest enamel defects as well as enlarged and elongated pulp chambers, radiographically (Figure 4). The mother reported that the proband's great-great-

*Figure 1. Panoramic radiograph of proband, demonstrating pulpal enlargement and elongation in the primary and permanent dentitions.*



Dr. Elzay is Professor of Oral Pathology in the Department of Oral Pathology and Genetics, and Dean of the Faculty, University of Minnesota, School of Dentistry.

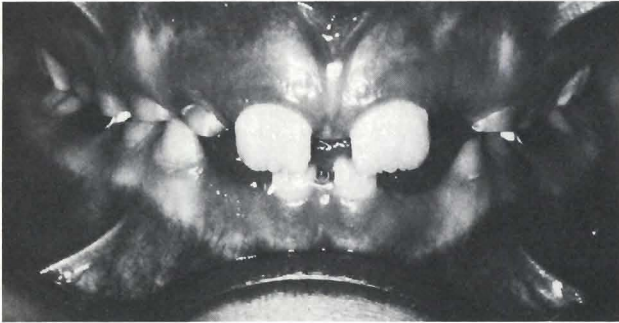


Figure 2. Clinical photograph that shows thin enamel with numerous parallel vertical grooves of anterior maxillary centrals and hypocalcified areas on tips of molar cusps.

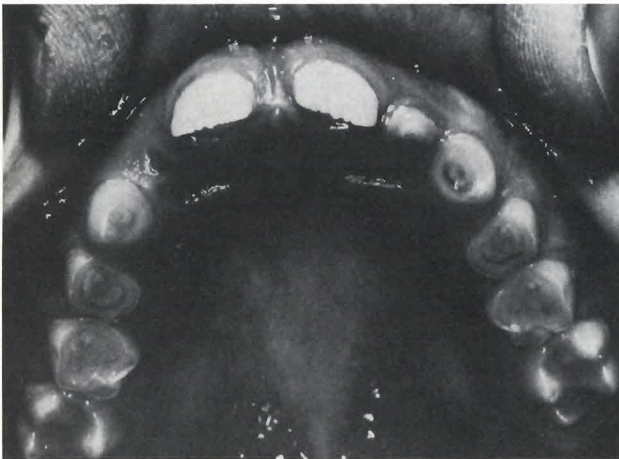


Figure 3. Clinical photograph showing severe occlusal attrition and thin enamel.

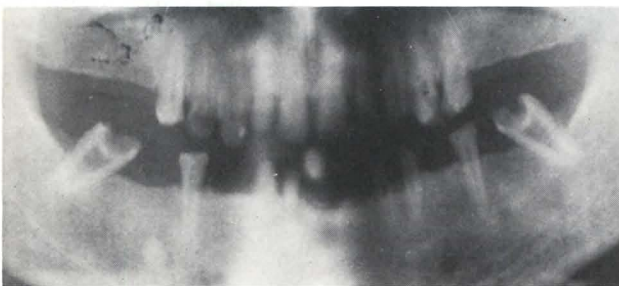

Figure 4. Panoramic radiograph of proband's mother demonstrating large and elongated pulp chambers of mandibular molars and deficiency of enamel.

grandfather, great-grandfather and his siblings, grandmother and all her siblings had "small skinny teeth and kinky hair" (Figure 5). Although the proband and her mother exhibited enlarged and elongated pulp cham-

bers and kinky hair, they did not exhibit evidence of physical growth disturbances, bossing or unusual facial form, fingernail abnormalities, hearing defects or a lack of mental development. After a thorough clinical evaluation and consideration of the possible differential diagnoses, the diagnosis of amelogenesis imperfecta with taurodontism was established.

## DISCUSSION

Either amelogenesis imperfecta or taurodontism may occur as isolated entities, together or with other conditions.<sup>5,8,9,11,12</sup> Patients who show a combination of amelogenesis imperfecta and taurodontism have been reported and several authors have recognized that abnormalities of the hair and bones may be found.<sup>5,8,9,11</sup> The authors submit the case reported herein as another example of amelogenesis imperfecta and taurodontism. The pedigree findings in this case are consistent with an autosomal dominant inheritance. This case illustrates two readily observable abnormalities, amelogenesis imperfecta (enamel hypoplasia) and enlarged, elongated pulp chambers, which may offer distinctive clues toward a definitive clinical diagnosis.

When encountering a patient who has radiographic evidence of enlarged pulp chambers, the clinician may find it helpful to recognize the plethora of conditions associated with large pulp chambers. In the Table (next page), the authors have listed fourteen conditions associated with large dental pulps. In addition to the salient radiographic features of the respective pulpal conditions, other significant dental findings, mode of inheritance and the dentitions most often affected have been given. Note that references have been supplied for each of the conditions in the event that additional information, beyond the intent and scope of this paper, is desired on either the clinical findings or management of the respective conditions.

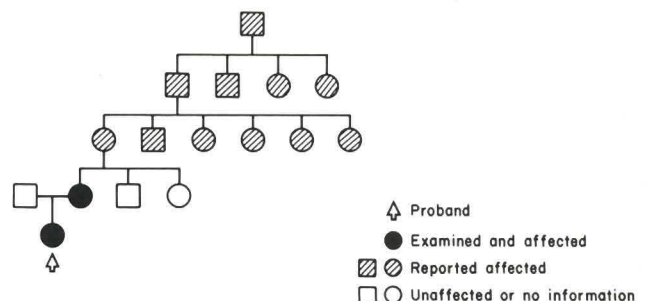


Figure 5. Pedigree of proband.

Table □ Disorders manifesting enlarged pulp chambers

Disorder	Mode of inheritance	Dentition affected	Effects on teeth
1. Isolated taurodontism <sup>5,12</sup>	Autosomal dominant	Primary/Permanent	Enlarged pulp chamber (taurodont); body of tooth is enlarged and roots reduced in size.
2. Amelogenesis imperfecta with taurodontism <sup>5,8,9,11</sup>	Autosomal dominant	Primary/Permanent	Enlarged pulp chamber (taurodont); enamel hypoplasia generally associated with hypomaturation.
3. Trichodontoosseous syndrome <sup>4,5,11</sup>	Autosomal dominant	Primary/Permanent	Enlarged pulp chamber (taurodont); hypoplastic-hypomaturation enamel; unerupted teeth; sometimes high pulp horns present that extend to the dentinoenamel junction; rapid attrition through this enamel may result in pulpal exposure and necrosis; cortical osteosclerosis.
4. Otodontal syndrome (globodontia) <sup>1,4,5</sup>	Autosomal dominant	Primary/Permanent	Large pulp chambers which may be duplicated; hypoplastic (thin) enamel; taurodontism is common finding; gigantic globeshaped posterior teeth.
5. Hypophosphatemic vitamin D-resistant rickets <sup>3,4</sup>	X-linked recessive	Primary/Permanent (rare)	Enamel hypoplasia is rare. Large pulp chambers; pulpal horns extend to dentinoenamel junction; may result in pulpitis and periapical pathosis; delayed eruption may occur; absent or poorly defined lamina dura; alveolar bone pattern is often abnormal.
6. Vitamin D-dependent rickets <sup>3,4</sup>	Autosomal recessive	Primary/Permanent (rare)	Large pulp chambers; high pulp horns and delayed closure of root apices; enamel hypoplasia is common.
7. de Toni-Debré-Fanconi syndrome (osteomalacia, renal glycosuria, amino-aciduria, and hyperphosphaturia) <sup>3,4</sup>	Sometimes acquired. Other cases are probably autosomal recessive.	Primary/Permanent (rare)	Same changes as noted in Vitamin D-resistant rickets except that hypoplastic enamel is found more frequently.
8. Hypophosphatasia <sup>2,3</sup>	Autosomal recessive	Primary/Permanent	Large pulp chambers; delayed closure of apices. Spontaneous shedding of primary teeth without root resorption.
9. Hereditary opalescent dentin (D1 type II) <sup>4,12</sup>	Autosomal dominant	Primary	Opalescent color, bell-shaped crowns; pulp chambers and canals almost totally obliterated; normal-sized pulp chambers sometimes seen; occasionally enlarged pulp chambers and canals are noted in primary teeth; primary teeth more severely affected than permanent teeth.
10. Dentinogenesis imperfecta associated with osteogenesis imperfecta (D1 type I) <sup>4,12,13</sup>	Autosomal dominant	Primary	Similar to hereditary opalescent dentin but with more variability; enlarged pulp chambers and canals have been noted.
11. Dentinogenesis imperfecta of "Brandywine type" (D1 type III) <sup>4,12</sup>	Autosomal dominant	Primary	Considerable variation from normal to severely affected teeth similar to opalescent teeth with pulpal obliteration and bellshaped crowns to large pulp chambers and canals; multiple pulp exposures observed in primary teeth.
12. "Shell teeth" <sup>14</sup>	Unknown	Permanent	Enlarged pulp chambers and canals of all teeth without evidence of obliteration.
13. Dentin dysplasia type II (Coronal dental dysplasia; pulpal dysplasia) <sup>9,10,12</sup>	Autosomal dominant	Primary/Permanent	Pulp chambers of all teeth in both dentitions are large, bulbous or flame shaped and contain numerous pulp stones; in older affected children, chambers become reduced and may become obliterated; pulpal horns often extend to dentinoenamel junction.
14. Odontodysplasia (odontogenesis imperfecta, ghost teeth) <sup>2,3</sup>	Not inherited	Primary/Permanent	Enlarged pulp chambers, severe hypoplastic enamel and thin, hypocalcified dentin; condition affects a few adjacent teeth, generally anterior teeth affected.

## REFERENCES

- Witkop, C.J., Jr.; Gundlach, K.K.H.; Streed, W.J. *et al*: Globodontia in otodontal syndrome. *Oral Surg*, 41:472-483, April, 1976.
- Witkop, C.J., Jr.: Hereditary defects of dentin. *Dent Clin North Am*, 19:25-45, January, 1975.
- Witkop, C.J., Jr.: Manifestations of genetic diseases in the human pulp. *Oral Surg*, 32:278-316, August, 1971.
- Gardner, D.G.: Genetic diseases affecting the dental pulp. In Stewart, R.E. and Prescott, G.H., editors: *Oral Facial Genetics*. St. Louis: The C.V. Mosby Co., 1976, pp 288-309.
- Jorgenson, R.J.: The conditions manifesting taurodontism. *Am J Med Genet*, 11:435-442, April, 1982.
- Gardner, D.G. and Girgis, S.S.: Taurodontism, shovel-shaped incisors and the Klinefelter syndrome. *J Canad Dent Assoc*, 44:372-373, September, 1978.
- Jaspers, M.T. and Witkop, C.J., Jr.: Taurodontism, an isolated trait associated with syndromes and X-chromosomal aneuploidy. *Am J Hum Genet*, 32:396-413, May, 1980.
- Congleton, J. and Burkes, E.J., Jr.: Amelogenesis imperfecta with taurodontism. *Oral Surg*, 48:540-543, December, 1979.
- Crawford, J.L.: Concomitant taurodontism and amelogenesis imperfecta in the American caucasian. *J Dent Child*, 37:171-175, March-April, 1970.
- Shafer, W.G.; Hine, M.K.; and Levy, B.M.: *A textbook of oral pathology*, ed. 4. Philadelphia: W.B. Saunders Company, 1983, pp 61-63.
- Witkop, C.J., Jr. and Sauk, J.J., Jr.: Heritable defects of enamel. In Stewart, R.E. and Prescott, G.H., editors: *Oral Facial Genetics*. St. Louis: The C.V. Mosby Co., 1976, pp 208-212.
- Bixler, D.: Heritable disorders affecting cementum and the periodontal structure. In Stewart, R.E. and Prescott, G.H., editors: *Oral Facial Genetics*. St. Louis: The C.V. Mosby Co., 1976, pp 267-273.
- Bergman, G.: Studies on mineralized dental tissues XIV. The incremental pattern of the dentine in a case of osteogenesis imperfecta. *Oral Surg*, 13:70-75, January, 1960.
- Rushton, M.A.: A new form of dental dysplasia: "Shell teeth". *Oral Surg*, 7:543-549, August, 1954.

# Abstracts

**Holan, Gideon; Fuks, Anna B.; Grajower, Rafael; Chosack, Aubrey: *In vitro* assessment of the effect of Scotchbond on the marginal leakage of class II composite restorations in primary molars. J Dent Child, 53:188-192, May-June, 1986.**

The authors attempted to determine, by using dye penetration, the micro-leakage at the interface of class II composite restorations placed in extracted or exfoliated primary molars, using Scotchbond as a bonding agent. In the experimental group of twenty-four conventional class II cavities, Scotchbond was used as the bonding material to dentin and enamel. In the control group (B), the remaining twenty-four cavities had Concise bonding agent used in the enamel only. In group B, 83.4 percent of the teeth showed minimal or no dye penetration in the occlusal surface, compared to only 8.3 percent of group A.

**Bonding agents, Scotchbond, Concise, Class II cavities**

**Rubel, Irving: Atypical root resorption of maxillary primary central incisors due to digital sucking: a report of 82 cases. J Dent Child, 53:201-204, May-June, 1986.**

This investigation concerns a particular pattern group in apical root resorption of maxillary primary central incisors, which is evident in those patients with a history of digital sucking. It appears to be a nearly constant symptom of the habit, confirmed by roentgenographic findings.

**Digit sucking, Apical root resorption**

**Hasiakos, Peter S.; Weine, Franklin S.; Ellenz, Daniel G.; Keene, Joseph J., Jr.: Treatment of an unusual case of fusion. J Dent Child, 53:205-208, May-June, 1986.**

The dental literature contains many reports concerning endodontic treatment of teeth with fusion, gemination, and talon cusps. This paper reports the treatment of an unusual example of an-

terior tooth fusion, in which the involved tooth had one crown, one talon cusp, two roots, and three root canals. Despite extensive consultations, treatment failed and the tooth was extracted.

**Fusion, Talon cusp, Supernumerary incisor**

**Kurol, J. and Bjerklin, K.: Ectopic eruption of maxillary first permanent molars: a review. J Dent Child, 53:209-214, May-June, 1986.**

This article reviews current views and information on the background and treatment of ectopic eruption of the maxillary first permanent molar. This local eruption disturbance causes premature resorption of the distal part of the second primary molar. A self-correcting, reversible type and an irreversible, locked-type can be distinguished. The prevalence of ectopic eruption is reported to vary from two to six percent of children. Treatment methods are reviewed here.

**Ectopic eruption, Maxillary first permanent molars**

**Fos, Peter J. and Pittman, James M.: Efficacy of fluoride on dental caries reduction by means of a community water supply. J Dent Child, 53:219-222, May-June, 1986.**

A study was made of 200 New Orleans children to determine the effect of a fluoridated water supply (the Mississippi River) on caries experience. Results show that the fluoride in drinking water is a very cost-effective method of this administration of protection to children, and that the number of caries lesions and extractions were effectively reduced.

**Fluoridated drinking water, Caries reduction**

**Herbert, Frank L.: Hereditary hypophosphatemia rickets: an important awareness for dentists. J Dent Child, 53:223-226, May-June, 1986.**

Because X-linked hypophosphatemia vitamin D-resistant rickets (VDRR) is

reported to be the most common form of rickets in the United States today, it is important for dentists to be aware of this condition. Often the first clinically detectable signs of the disease are its characteristic dental findings. The care of a six-year-old boy is reported here, including prophylactic, full-coverage restorations as the preferred conservative treatment in these cases.

**Vitamin-D resistant rickets,  
Stainless steel crowns**

**Stenvik, Arild, and Storhaug, Kari:** Malocclusion patterns in fourteen children with duchenne's muscular dystrophy. *J Dent Child*, 53:215-218, May-June, 1986.

Occlusal relationships, dental arch dimensions, and oral muscular function and morphology were recorded for a group of fourteen boys, ages 8 to 15 years, with Duchenne's muscular dystrophy. Dimensions for each individual were compared with the norms for their corresponding age group. In all children, an increased dental-arch width was observed, and for the entire group a tendency toward open bite and posterior crossbite was evident. The consistently increased arch width indicates oral functional patterns specific to patients with this type of muscular dystrophy.

**Duchenne's muscular dystrophy,  
Dental arch width**

**Goepferd, S.J.:** Infant oral health: a protocol. *J Dent Child*, 53:261-266, July-August, 1986.

The potential exists for dental health professionals to assist parents in rearing caries-free children. This protocol was developed at the University of Iowa's Infant Oral Health Program; it includes increasing public awareness; giving a preappointment questionnaire, including a complete history-taking; conducting an interview of the infant's parents; examining the infant; demonstrating tooth cleaning to the parent; and concluding the appointment, including establishing a recall schedule.

**Caries, nursing; Oral health; Infancy; Tooth cleaning.**

**Goepferd, S.J.:** Infant oral health: a rationale. *J Dent Child*, 53:257-260, July-August, 1986.

The complete prevention of dental disease in children is the ultimate dream of dentists dedicated to the care of the oral health of children. The preventive process must begin early in infancy (birth to one year of age), and many parents of infants and toddlers are requesting it.

**Caries, nursing; Oral health; Infancy**

**Waldman, H.B.:** Are the unmet needs of children overshadowed by our concern for the aged? *J Dent Child*, 53:267-270, July-August, 1986.

Discussion of health and human services is dominated nowadays by the social, medical, and economic needs of the elderly; far less attention has been directed to the need for—and use of—health and social services by children, poor and nonpoor alike. For example, persistently high infant mortality rates exist for nonwhite groups. The need is for balanced attention to the needs of all age-groups, including dental care.

**Elderly, Children, Prevention,  
Dental care**

**Ooshima, T.; Mihara, J.; Saito, T.; Sobue, S.:** Eruption of tooth-like structure following the exfoliation of natal tooth: report of case. *J Dent Child*, 53:275-278, July-August, 1986.

This paper reports on a case in which a tooth-like structure, a hard-tissue, bone-like conglomerate, developed and erupted following removal of a natal tooth. Although the possibility of the retained dental papilla continuing to grow is extremely rare, it is reasonable to infer that the tooth-like structure in this nine-month-old Japanese boy originated in the remnant of the dental pa-

pilla and Hertwig's sheath of the natal tooth, which induced dentin formation as well as root formation.

**Natal tooth, Dental papilla, Root formation**

**Symons, A.L.:** Root resorption: a complication following traumatic avulsion. *J Dent Child*, 53: 271-274, July-August, 1986.

The viability of the periodontal ligament is in inverse proportion to the length of the extraoral period of traumatically avulsed teeth. Root resorption has occurred in 95 percent of the teeth replanted after an extraoral period of more than two hours. In this case, a 10.5-year-old girl fell from her bicycle; it was four hours before the teeth could be replanted and stabilized. Three years later, root resorption continued to be a problem.

**Root resorption, Traumatic avulsion**

**Tinkler, D.R. and Steelman, R.:** Ectopic developing permanent teeth in a five-year-old: report of case. *J Dent Child*, 53:279-280, July-August, 1986.

This paper reports on a five-year-old Hispanic boy with a case of ectopic growth of the developing permanent right second premolar and first and second molars. Treatment was planned conservatively; it will consist of maintaining the lower right second primary molar and allowing normal eruption of the surrounding permanent dentition. Later, the second primary molar will be extracted and the permanent teeth guided into proper occlusion.

**Premolar, Ectopic development**

**Fiszon, E.:** Multiple agenesis in two siblings. *J Dent Child*, 53:281-282, July-August, 1986.

Four siblings were seen for dental checkups. The children were from a

## supplementation

to help you guard appropriate patients against caries risk and nutritional risk.

**INDICATIONS AND USAGE:** Prophylaxis of vitamin deficiencies and dental caries in children and adults when fluoride of water supply does not exceed 0.7 ppm.<sup>1,2,3</sup> And, in the case of TRI-VI-FLOR® 0.25 mg Drops with Iron and POLY-VI-FLOR® Drops and Chewable Tablets with Iron, prophylaxis against iron deficiencies. Note: VI-FLOR Drops do not contain folic acid because the vitamin is not stable in liquid form.

**PRECAUTIONS:** Do not exceed recommended dose or give concurrently with other medications containing significant amounts of fluoride. Prolonged excessive fluoride intake may cause dental fluorosis. All VI-FLOR® with Iron products: as with all products containing iron, parents should be warned against excessive dosage. The bottle should be kept out of reach of children. Keep all VI-FLOR with Iron products tightly closed and away from direct light.

VI-FLOR Drops should be dispensed in the original plastic container, since contact with glass leads to instability and precipitation.

**ADVERSE REACTIONS:** Allergic rash has rarely been reported.

**DOSE AND ADMINISTRATION:**

**Supplemental Fluoride Dosage Schedule (mg/day)\***

Age	Concentration of Fluoride in Drinking Water (ppm)		
	<0.3	0.3-0.7	>0.7
2 wk-2 yr**	0.25	0	0
2-3 yr	0.5	0.25	0
3-16 yr	1.0	0.5	0

\*From the American Academy of Pediatrics Committee on Nutrition statement, Fluoride Supplementation: Revised Dosage Schedule. Pediatrics 63(1):150-152, 1979.

\*\*The Committee favors initiating fluoride supplementation shortly after birth in breast-fed infants (0.25 mg F/day). In formula-fed infants, fluoride supplementation should be according to the fluoride content of the water used to prepare formula.

PRODUCT	FORM	SIZE	FLUORIDE mg/dose
POLY-VI-FLOR 0.25 mg	Drops	50 ml Bottle	0.25
POLY-VI-FLOR 0.25 mg with Iron	Drops	50 ml Bottle	0.25
POLY-VI-FLOR 0.5 mg	Drops	50 ml Bottle	0.5
POLY-VI-FLOR 0.5 mg with Iron	Drops	50 ml Bottle	0.5
POLY-VI-FLOR 0.5 mg	Tablets	Bottle of 100	0.5
POLY-VI-FLOR 0.5 mg with Iron	Tablets	Bottle of 100	0.5
POLY-VI-FLOR 1.0 mg	Tablets	Bottle of 100	1.0
POLY-VI-FLOR 1.0 mg with Iron	Tablets	Bottle of 100	1.0
TRI-VI-FLOR 0.25 mg	Drops	50 ml Bottle	0.25
TRI-VI-FLOR 0.25 mg with Iron	Drops	50 ml Bottle	0.25
TRI-VI-FLOR 0.5 mg	Drops	50 ml Bottle	0.5
TRI-VI-FLOR 0.5 mg	Tablets	Bottle of 100	1.0

**REFERENCES:**

- Hennon DK, Stookey GK and Muhler JC: The Clinical Anticariogenic Effectiveness of Supplementary Fluoride-Vitamin Preparations—Results at the End of Four Years. J Dentistry for Children 34:439-443 (Nov) 1967.
- Hennon DK, Stookey GK and Muhler JC: The Clinical Anticariogenic Effectiveness of Supplementary Fluoride-Vitamin Preparations—Results at the End of Five and a Half Years. Pharmacology and Therapeutics in Dentistry 1:1-6 (Oct) 1970.
- Hennon DK, Stookey GK and Muhler JC: Prophylaxis of Dental Caries: Relative Effectiveness of Chewable Fluoride Preparations With and Without Added Vitamins. J Pediatrics 80:1018-1021 (June) 1972.

VI-SOL®/VI-FLOR® products are the nation's most prescribed children's vitamin and fluoride-vitamin supplements.

(For complete details, please consult full prescribing information.)

**Mead Johnson**

**NUTRITIONAL DIVISION**

Mead Johnson & Company  
Evansville, Indiana 47721 U.S.A.  
© 1986 M.J. & Co.

**ABSTRACTS**

*Continued from page 327*

Caucasian French family. The examinations showed multiple agenesis in two of the siblings; moreover, there was a remarkable resemblance in the dentitions of the two children, suggesting a genetic factor in multiple agenesis. Both had eleven permanent teeth missing.

**Multiple agenesis, Siblings**

**Wilson, S.; Venzel, J.M.; Miller, R.: Angiography, gingival hyperplasia and Sturge-Weber syndrome: report of case. J Dent Child, 53:283-288, July-August, 1986.**

Encephalotrigeminal angiomas, more commonly known as Sturge-Weber syndrome, is a condition characterized by: a facial nevus, leptomeningeal angiomas, convulsions, calcifications on the side of the brain, ocular disorders, obesity, mental retardation, and oral involvement. The extent of oral involvement of the hemangiomas can vary considerably. A case involving a nine-year-old black boy with an intraoral hemangioma and a pyogenic granuloma lesion removed without complications.

**Sturge-Weber syndrome, Gingival hyperplasia**

**Malerman, A.J. and Album, M.M.: Hallermann-Streiff syndrome: report of case. J Dent Child, 53:287-292, July-August, 1986.**

Oculomandibulocephaly, known as Hallermann-Streiff syndrome, is characterized by dyscephaly, congenital cataracts, dwarfism, microphthalmia, hypotrichosis, dental anomalies, cutaneous atrophy, shortness of the head, open sutures and fontanelles, and nystagmus. The etiology is poorly understood. A ten-year-old Caucasian girl is described in this case report. Dental and facial improvement can be accomplished with a well-controlled treatment program, with dramatic results.

**Hallermann-Streiff syndrome, Orthodontic treatment**

**Nussbaum, B.L.: Dental management of a child with familial dysautonomia. J Dent Child, 53:293-295, July-August, 1986.**

Familial dysautonomia is a hereditary sensory neuropathy involving sensory, motor, and central components of the nervous system. It is also known as Riley-Day syndrome. A non-Jewish, eleven-year-old boy is described in this case report. He could feel several types of pain, however; his case was a very rare one. Behavior modification may be possible in some cases.

**Familial dysautonomia, Orofacial anomalies**

**Faine, R.C. and Dennen, T.: A survey of private dental practitioners' utilization of dental sealants in Washington state. J Dent Child, 53:337-342, September-October, 1986.**

The aims of this study were to determine how many dentists in Washington state are applying sealants; to determine dentists' attitudes to sealant use; to obtain information about fees charged for placing sealants; and to determine ways of providing continuing education concerning sealants. The majority of dentists (80.7 percent) responding to the survey are currently using sealants.

**Sealants, Dental practice**

**Fuks, A.B.; Grajover, R.; Eidelman, E.: Assessment of marginal leakage of class II amalgam-sealant restorations. J Dent Child, 53:343-345, September-October, 1986.**

Conservative proximal amalgam restorations were placed *in vivo*, in molars with occlusal sealants, and only part of the sealant was removed during cavity preparation. The microleakage at the

*Continued on page 397*

## ABSTRACTS

Continued from page 332

occlusal amalgam-sealant interface was determined in twelve control samples. Only two experimental teeth and one control tooth showed dye penetration.

### **Amalgam restorations, Sealants**

**Hicks, M.J.:** Acid-etching of caries-like lesions of enamel treated with acidulated phosphate fluoride: an *in vitro* study. *J Dent Child*, 53:346-353, September-October, 1986.

This *in vitro* study was carried out to determine the effects of acid-etching with respect to surface morphology, etching patterns, and histopathologic appearances of the lesions. The acid-etch technique used in conjunction with fluoride treatment may provide a means to enhance remineralization of enamel caries or to allow placement of acid-resistant resin, thereby preventing lesion progression.

### **Acid-etching, APF, Enamel lesions**

**Linkosalo, E.:** The effect of fluoridated water on DMF scores of first permanent molars in mixed dentitions. *J Dent Child*, 53:354-358, September-October, 1986.

The dental health status of first permanent molars was studied at the ages of 7, 11 and 15 years in 146 children born and living in a town with fluoridated drinking water, and of 110 children living in a fluoride-deficient area of Finland. The fluoride in the drinking water was sufficient for caries reduction but insufficient as a sole regimen for prevention.

### **Fluoride, Community water supplies, Bitewing radiographs**

**Tinanoff, N. and Cantin, R.:** Management of dental caries as an infectious disease. *J Dent Child*, 53:359-363, September-October, 1986.

The relationship of microbiology to the understanding and treatment of dental caries is discussed in this paper. Bacterial traits, necessary for cariogenicity; antimicrobial treatment of patients; microbial monitoring of cariogenic flora; and the effect of xerostomic conditions on caries activity are topics covered in this report, as well as the case presented of a 5-year-old with rampant caries treated successfully with daily use of 0.4% SnF<sub>2</sub>.

### **Cariogenicity, Antimicrobial treatment**

**van Amerongen, W.E.; Mulder, G.R.; Vinzerling, P.A.:** Consequences of endodontic treatment in primary teeth. Part I: A clinical and radiographic study of the influence of formocresol pulpotomy on the life-span of primary molars. *J Dent Child*, 53:364-370, September-October, 1986.

The fact that no significant differences in life-spans were found between test teeth and control teeth would seem to warrant the conclusion that formocresol pulpotomy is a successful method of treating primary teeth with exposed pulp.

### **Formocresol pulpotomy, Primary teeth, Tooth extraction**

**Thwaites, M.S. and Cox, G.M.:** The psychosocial aspects of adolescent pregnancy: a dental perspective. *J Dent Child*, 53:371-374, September-October, 1986.

The dental patient understood least is the pregnant adolescent. There are be-

havioral and physiological changes, especially hormonal, that occur with each of these life situations. Knowledge and understanding of the psychological and social dynamics of adolescence will help the dental practitioner to help this patient.

### **Pregnancy, Adolescence, Dental care**

**Turner, C. and Hill, C.J.:** Supernumerary mandibular premolar: the importance of radiographic interpretation. *J Dent Child*, 53:375-377, September-October, 1986.

The most effective method of diagnosing supernumerary teeth is by way of a thorough radiographic survey and interpretation. The number and frequency of dental radiographs being reduced with concerns about radiation exposure means increased possibilities of overlooking supernumerary teeth.

### **Supernumerary teeth, Dental radiography**

**Gross, K.B.W.; Brough, K.M.; Randolph, P.M.:** Eating disorders: anorexia and bulimia nervosa. *J Dent Child*, 53:378-381, September-October, 1986.

Both anorectics and bulimics are abnormally concerned with their body size and have an excess fear of becoming overweight. The difference between the two illnesses is in the manifestations of the conditions. The dental practitioner has an ethical and legal responsibility to detect and refer these patients for appropriate physical and psychological treatment.

### **Anorexia, Bulimia, Perimylolysis, Caries, Xerostomia**